



## Case Report

# Erratum to “Ocular rhinosporidiosis- A case report” Indian Journal of Clinical Experimental Ophthalmology 2022;8(2):295–297

Payal Mukherji<sup>1</sup>, Neha Shilpy<sup>2,\*</sup>

<sup>1</sup>Dept. of Ophthalmology, Shaheed Nirmal Mahto Medical College, Dhanbad, Jharkhand, India

<sup>2</sup>Dept. of Ophthalmology, Rajendra Institute of Medical Sciences, Ranchi, Jharkhand, India

The corresponding author has forgotten to cite an image in the manuscript and the owner of the image, Dr. Gautam Lokdarshi, has requested its removal.

## Erratum

**In Case Report Section Page No. 296:**

**Changes:** We have removed Figure 1

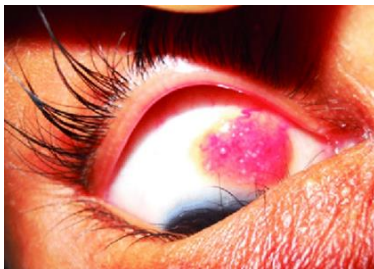


Figure. Conjunctival rhinosporidiosis (RE)

The authors and the publisher would like to apologize for any inconvenience or misunderstanding.

The corrected supplementary data is now available online: