

Study of efficacy of intravitreal triamcinolone acetonide (IVTA) for the treatment of refractory diabetic macular edema (DME) in type 2 diabetes mellitus patients

Pankaj Soni^{1*}, Ashutosh Kumar Singh², Suroma Joysmine Marndi³

¹Associate Professor, ²Junior Resident, ³Senior Resident, Dept. of Ophthalmology, BRD Medical College, Gorakhpur, Uttar Pradesh, India

Article Info

Received: 12th January, 2019

Accepted: 8th April, 2019

Published Online: 9th September, 2019

Keywords: Diabetic Macular Edema (DME), Intra Vitreal Triamcinolone Acetonide (IVTA).

Abstract

Aim: To study the efficacy of intravitreal triamcinolone acetonide (IVTA) for the treatment of refractory diabetic macular edema (DME) in type 2 diabetes mellitus patients.

Materials and Methods: A prospective, interventional, non-comparative case series. There were 13 eyes of 13 patients with refractory DME. An intravitreal injection of triamcinolone acetonide at the dose of 4 mg in 0.1 ml was administered. Best corrected visual acuity was measured at each examination. The amount of hard exudates deposition in the macula was subjectively evaluated using colour fundus photographs. Central macular thickness (CMT) was measured, on OCT.

Results: 13 patients completed 6 months or more of follow up and were included in the study. Sex distribution in the study was 12 (92.40%) males and 1 female (7.60%). There was significant improvement in the visual acuity, 2.42 ± 1 (mean \pm SD) ($p < 0.001$). There was improvement in BCVA in all thirteen patients, though the improvement was very less in 2 patients, excluding these patients 84% patients had at least 1 Snellen's line improvement, in Log MAR units this corresponds to 0.90 ± 0.36 (mean \pm SD). In 76% eyes there was one or more Snellen's line improvement. Mean central macular thickness (CMT) improved significantly.

Conclusions: Intravitreal injection of 4 mg of triamcinolone acetonide may be beneficial for improving visual acuity in type 2 diabetes patients which have refractory diabetic macular edema.

Introduction

Modern medicine has improved quality of life as well as expectancy, a majority which has been benefited are diabetics.

Diabetes mellitus, an endocrinological system disorder is well known to affect all major organs of body due to its associated microangiopathy and macroangiopathy.

Diabetics are at risk of development of vision threatening retinopathy as a result of microvascular changes. Incidence and prevalence of diabetes increases with age and so does the incidence and severity of retinopathy, despite the best efforts some complications run a relentless course specially with early onset diabetes mellitus, prevalence of complications increases with duration of disease. Diabetes mellitus is the commonest cause of legal blindness between ages of 20-65 years.

Diabetic maculopathy (foveal edema, exudates or ischaemia) is the most common cause of visual impairment in diabetic patients, particularly in type 2. Diffuse retinal edema is caused by extensive capillary leakage and localized edema by focal leakage from microaneurysms and dilated capillary segments. The fluid is initially located between the outer plexiform and inner nuclear layers; later it may also involve the inner plexiform and nerve fiber layers,

until eventually the entire thickness of the retina becomes edematous. With central accumulation of fluid the fovea assumes a cystoid appearance – cystoid macular edema (CME) that is readily detectable on optical coherence tomography (OCT) and assumes a central petal flower petal pattern on FA.

Clinically significant macular edema includes following:

1. Thickening of macula at or within 500 μ m of center of macula.
2. Hard exudates at or within 500 μ m of center of macula.
3. Zones of retinal thickening 1 disc diameter or greater within 1 disc diameter of center of macula.

Previously there was no significant treatment for diabetic retinopathy but pan retinal photocoagulation (PRP) and focal macular laser (ETDRS 1.2) with argon (Green) and Krypton (Red) to laser has substantially decreased the risk of severe visual loss.

Present study will deal with improvement in macular function (Vision) and angiographic feature after injection of 0.1 ml (4 mg) of intravitreal triamcinolone acetonide and to look for any significant adverse effect that limit its use.

*Corresponding Author: Pankaj Soni, Associate Professor, Dept. of Ophthalmology, BRD Medical College, Gorakhpur, Uttar Pradesh, India

Email: drpankajpbh@gmail.com

<http://doi.org/10.18231/ijceo.2019.097>

Aims and Objectives

To study the efficacy of intravitreal triamcinolone acetonide (IVTA) for the treatment of refractory diabetic macular edema (DME) in type 2 diabetes mellitus patients.

Materials and Methods

The study was conducted in the department of ophthalmology at Nehru Hospital attached to B.R.D. Medical College, Gorakhpur from period of September 2017 to August 2018, for a duration of one year.

Study Design

This study is a prospective, interventional, non-comparative case series.

Study Group

Study includes 13 patients who fulfilled our inclusion criteria.

Inclusion Criteria

Patients were included if they had diffuse macular edema clinically (early treatment diabetic retinopathy study) due to type 2 diabetes, refractory to laser photocoagulation and with no signs of vitreomacular traction and

1. No evidence of diffuse fluorescein leakage around macular area.
2. Central macular thickness (CMT) >250 μm at baseline.
3. Normal blood sugar levels.
4. Normal blood pressure.
5. Patient should not have history of glaucoma to evaluate corticosteroid induced rise in IOP.
6. Implied consent of eligible patient was taken.

Exclusion Criteria

1. Macular edema due to any other condition.
2. Advance cataract.
3. History of PRP within 4 months.
4. History of major ocular surgery.
5. IOP > 25 mm of Hg.

Preoperative Assessment

All the eligible patients were followed through cases in Retina Clinic of department, keeping in view aims and objectives of the study all patients were subjected to detailed clinical evaluation which includes:

History about duration of current treatment for associated systemic illnesses i.e., diabetes mellitus, hypertension. General examinations for pulse rate, respiratory rate, blood pressure, pallor, icterus etc.

Systemic examination of CVS, CNS, respiratory, gastrointestinal and excretory system.

Local Examination

1. Slit lamp examination for anterior segment.
2. Visual acuity using Snellen's chart at 6 meters for distance, counting fingers and projection of rays and pin hole testing, BCVA.
3. Near vision at 20-30 cms.
4. IOP measurement.

5. Fundus examination by 90D for evaluation of macular thickness clinically and by indirect ophthalmoscopy.
6. OCT macula for thickness measurement.
7. FFA- to look for focal leakage around macula and fundus and for any ischemic changes in fundus.
8. Macular function test done by Amslers grid at 20-30 cms.

Investigations: Routine Hb, CBC, BT, CT, Blood sugar fasting and PPBS, KFT etc.

Method:

All suitable patients were given 4 mg (0.1 ml) of intravitreal triamcinolone acetonide under subconjunctival anaesthesia. Injection was given by a 26G needle mounted on a tuberculin syringe, 3.5-4 mm from limbus at the temporal pars plana.

Observations and Results

Table 1: Age incidence of macular edema in our study

Age group	No. of patients (n=13)	Percentage
51-60 years	09	69.30
61-70 years	03	23.10
71-80 years	01	07.60

Sex distribution in the study was 12 (92.40%) males and 1 female (7.60%).

Table 2: Relationship of diabetic macular edema in type 2 diabetes with duration of disease

Duration of diabetes mellitus	No. of patients (n=13)	Percentage
10-13 years	03	27.40
14-17 years	04	36.30
18-21 years	06	36.30

To compare the effect of intravitreal TA in our patients, patients were divided in four groups:

Group 1: Vision between 6/6 – 6/12

Group 2: 6/18 – 6/24

Group 3: 6/36 – 6/60

Group 4: <6/60 – FC

Table 3: Improvement in patients following intravitreal TA injection

Group	No. of patients (n=13) Pre-Treatment	No. of patients (n=13) Post-Treatment
Group 1	-	03
Group 2	-	04
Group 3	06	04
Group 4	07	02

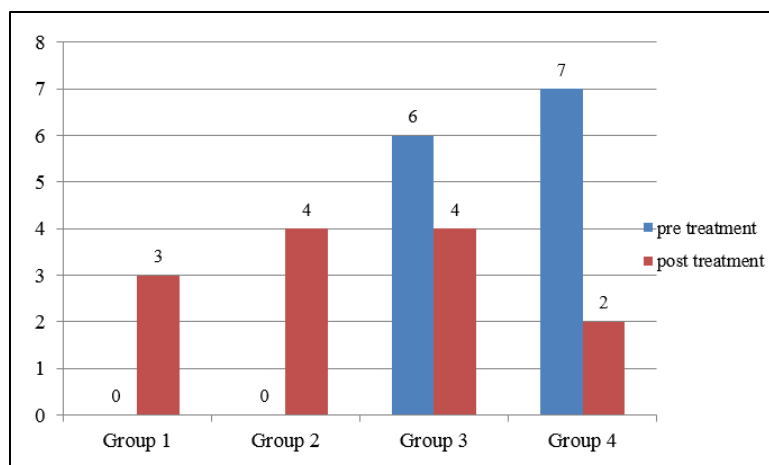


Fig. 1: Improvement of patients following intravitreal injection of TA

Table 4: Preoperative and postoperative BCVA of patients

Visual acuity	BCVA Pre intravitreal treatment	BCVA Post intravitreal treatment
Log MAR units (mean \pm SD)	1.2+0.42	0.63+0.33
Median	1.0	0.50
Decimal System (mean \pm SD)	0.09+0.06	0.29+0.17
Median	0.10	0.32

Table 5: Comparison of BCVA expressed in Snellens, log MAR and decimal system

S. No.	Pre IVTA snellens	Post IVTA snellens	Line improvement	Pre IVTA Log MAR	Post IVTA Log MAR	Pre IVTA decimal	Post IVTA Decimal
1.	6/36	6/12	3	+0.8	+0.3	0.17	0.50
2.	6/36	6/9	4	+0.8	+0.2	0.17	0.60
3.	FC 1/2m	FC 3m	0.5	+0.2	+1.4	0.01	0.04
4.	FCCF	FC 5m	1	+2.0	+1.0	0.01	0.10
5.	6/36	6/12	3	+0.8	+0.3	0.17	0.50
6.	6/60	6/18	3	+1.0	+0.5	0.10	0.32
7.	FC 3m	6/24	2.5	+1.3	+0.6	0.05	0.25
8.	FC 4m	6/18	4	+1.3	+0.5	0.05	0.32
9.	6/36	6/18	2	+0.8	+0.5	0.17	0.32
10.	FC 2m	6/36	2	+1.4	+0.8	0.04	0.17
11.	FC 5m	6/36	2	+1.0	+0.8	0.10	0.17
12.	6/60	6/36	1	+1.0	+0.8	0.10	0.17
13.	6/60	6/18	3	+1.0	+0.5	0.10	0.32

Data shows Snellen's line improvement in patients treated with IVTA (4 mg).

1. In 76% of eyes, there was 2 or more line improvements ($p < 0.001$).
2. 84% of patients had at least one line improvement ($p < 0.01$).
3. In the study group there was significant improvement in the visual acuity, 2.42 ± 1 (mean \pm SD) ($p < 0.001$). there was improvement in BCVA in all thirteen patients, though the improvement was very less in 2 patients, excluding these patients 84% patients had at least 1

Snellen's line improvement, in Log MAR units this corresponds to 0.90 ± 0.36 (mean \pm SD) in 76% eyes there was one or more Snellen's line improvement.

4. In 10 out of 13 patients (76%) there was significant decrease in fluorescein leakage.
5. There was regression in the size of hard and soft exudates in the fundus, in 4 patients there was persistence of hard exudates in macular area. There was decrease in macular edema in 11 patients (84%) on 90 D examination clinically and in OCT.
6. There was significant increase ($p = 0.001$) in intraocular pressure from baseline 15 ± 2.6 to 23 ± 59 mmHg in a

mean period of 2 months, range (15-35)mmHg. All the patients were given topical medications for intraocular pressure control. In two patients who did not had intraocular pressure control with one topical drug were given two topical drugs and intraocular pressure normalized.

7. No glaucomatous changes were seen in patients at the end of follow up. At the end of follow up the intraocular pressure measures were nearly same as the baseline measures (not significant).
8. No TA injected eyes showed evidence of deposition of triamcinolone crystals over the disc or macular area causing optical interference to light.
9. No injection related complications were noticed in follow up.

Table 6: Preoperative and postoperative central macular thickness, on OCT

At baseline-Mean (\pm SD)	At 8 months-Mean (\pm SD)	P- value
503.45 μ m (\pm 210.66 μ m)	320.76 μ m (\pm 160 μ m)	< 0.01

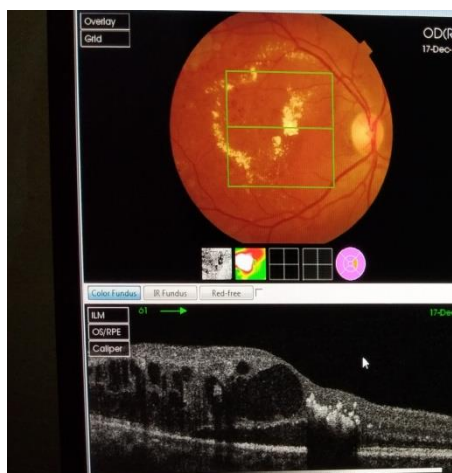


Fig. 2: Showing fundus photography and OCT picture of pre-injection IVTA in DME

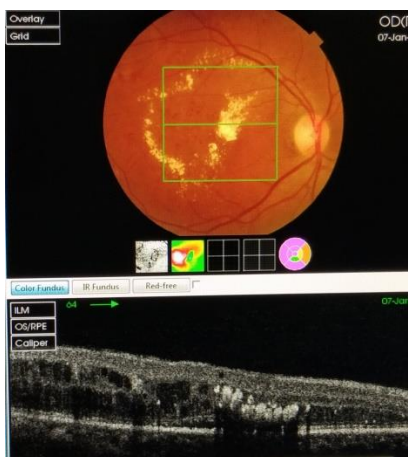


Fig. 3: Showing fundus photography and OCT picture of post-injection IVTA after 1 month in DME.

Discussion

Macular edema is one of the most important causes of impaired vision in diabetic retinopathy. Laser photocoagulation and medical therapy is often been used to treat diabetic cystoid macular edema. Corticosteroids too are being used via various routes i.e. topical, subconjunctival, subtenon, oral, intravenous etc.

Corticosteroid have been in use since decades to reduce inflammation anywhere in the body, in Ophthalmology also they are in use for various inflammatory conditions, topically, subconjunctival, subtenon or orally i.e. in uveitis, sympathetic ophthalmitis, optic neuritis but none of the methods were effective enough to provide high concentrations of steroid at a particular site and maintain its availability for long time. Oral administration has its disadvantages and side effects too and are contraindicated in systemic illness i.e. diabetes and hypertension.

To achieve long term high intraocular concentration and minimal systemic side effects, Graham and Pcyman experiment cortisone injection intravitreally in animals and human models and found it to be non toxic to ocular tissues. Clinical studies till now too do not report the intravitreal cortisone to be toxic to ocular tissues.

In an attempt to overcome the limitation of use of Steroids and potential side effects and reduce ocular inflammation and proliferation of cells, Machemer suggested a depot form of crystalline steroids which has long intravitreal absorption (2 to 5 months) time provides with cortisone for long period of time than a single injection of cortisone which washes up within 24 hours.

Following the pioneers in the use of intravitreal triamcinolone now is being used for the treatment of intraocular neovascular, proliferative and edematous States such as in Diabetic macular edema, PDR, Central retinal vein occlusion, chronic persistent uveitis, pseudophakic cystoid macular edema, age-related macular degeneration.

Various studies and clinical trials had suggested intravitreal triamcinolone injections to be useful to increase visual acuity in patients with diffuse diabetic macular edema.

These preceding studies have been confirmed by our present prospective single armed clinical interventional case series on refractory diabetic macular edema, though mechanism of action of triamcinolone is not very clear as other macular edema also respond to intravitreal triamcinolone.

Patients included in this case series showed a significant improvement in visual activity and clinical picture of fundus compared to the values and fundus picture of fluorescein fundus angiographic pictures at the baseline of the study using a dose of 4 mg (1 ml) of triamcinolone acetonide.

Factors that cause increased visual activity after intravitreal triamcinolone are

1. Degree of macular ischemia
2. Higher baseline visual acuity
3. Higher intraocular pressure elevation on follow up

This might be explained by pathophysiology of leaking retinal capillaries due to diabetes. Leakage of capillaries is most dependent on transmural pressure gradient (i.e. pressure within capillary and outside space) due to higher increase in intraocular pressure the pressure gradient decreases and so does the capillary leakage.

Main side effect observed in our study was elevation in intraocular pressure (steroid induced ocular hypertension) and could be treated on topical antiglaucoma medications without development of optic nerve head cupping.

On theoretical grounds one may suspect a development of posterior vitreous detachment or retinal detachment due to weight of triamcinolone crystals in vitreous and vitreoretinal interface but in no patients in our case series posterior vitreous detachment or retinal detachment occurred. Development of posterior vitreous detachment can be a benefit to patients with diabetic maculopathy and proliferative vitreoretinopathy and is known to regress macular edema and vitreoretinal proliferation, also suggested by studies on pars plana vitrectomy in patients with diffuse diabetic macular edema.

Cataract formation may occur in repetitive intravitreal injections as corticosteroids are known to have cataractogenic effect.

Other local side effects such as infectious endophthalmitis, sterile endophthalmitis and pseudo endophthalmitis have not been observed in our study.

Jonas JB has reported that serum level of triamcinolone was not detectable in patients who had undergone 20mg intravitreal injection revealing that it can be administrator to patients with diabetes and hypertension without having a negative impact on its metabolic control.

In diabetes and hypertension, glycemic control, blood pressure and nephropathy may affect macular edema, we therefore excluded such patients and included only those patients who had strict glycemic and blood pressure control.

Based on the results of our interventional case series and previous case reports and studies we infer that intravitreal triamcinolone maybe a valid option for patients with refractory macular edema due to diabetes not responding to conventional medical and laser treatment.

There are some limitations to our study, firstly, a small number of patients in our study and lack of controls which serve as comparative cases for evaluation of outcome. Secondly there is lack of data and studies suggesting adequate amount of dose that should be injected in patients.

Conclusion

Intravitreal injection of 4 mg of triamcinolone acetonide may be beneficial for improving visual acuity in type 2 diabetes patients which have refractory diabetic macular edema. IVTA is effective in improving vision, reducing macular thickness, and inducing reabsorption of hard exudates. Further investigation is warranted to assess the safety of IVTA for the treatment of DME.

Source of Funding: None.

Conflict of Interest: None.

References

1. Avci R, Kaderli B. Intravitreal triamcinolone injection for chronic diabetic macular oedema with severe hard exudates. *Graefes Arch Clin Exp Ophthalmol* 2013;244(1):28–35.
2. Avci R, Kaderli B, Akalp FD. Intravitreal triamcinolone injection for chronic diffuse diabetic macular oedema. *Clin Exp Ophthalmol* 2013;34(1):27–32.
3. Ciardella AP, Klancnik J, Schiff W, Barile G, Langton K, Chang S. Intravitreal triamcinolone for the treatment of refractory diabetic macular oedema with hard exudates: an optical coherence tomography study. *Br J Ophthalmol* 2004;88(9):1131–6.
4. Khairallah M, Zeghidi H, Ladjimi A. Primary intravitreal triamcinolone acetonide for diabetic massive macular hard exudates. *Retina* 2015;25(7):835–9.
5. Takagi H, Otani A, Kiryu J, Ogura Y. New surgical approach for removing massive foveal hard exudates in diabetic macular edema. *Ophthalmol* 2012;106(2):249–56.
6. Nguyen QD, Brown DM, Marcus DM. Ranibizumab for diabetic macular edema: results from 2 phase III randomized trials: RISE and RIDE. *Ophthalmol* 2012;119(4):789–801.
7. Pemp B, Deak G, Prager S. Diabetic Retinopathy Research Group Vienna. Distribution of intraretinal exudates in diabetic macular edema during anti-vascular endothelial growth factor therapy observed by spectral domain optical coherence tomography and fundus photography. *Retina* 2014;34(12):2407–15.
8. Yang CM. Surgical treatment for severe diabetic macular edema with massive hard exudates. *Retina* 2000;20(2):121–5.
9. Centers for Disease Control and Prevention. Blindness caused by diabetes: Massachusetts, 1987–1994. Morbidity and Mortality Weekly Report. 1996;45(43):937–41.
10. Ciulla TA, Walker JD, Fong DS, Criswell MH. Corticosteroids in posterior segment disease: an update on new delivery systems and new indications. *Curr Opin Ophthalmol*. 2004;15(3):211–20.
11. Cunha-Vaz J. Diabetic macular edema. *Eur J Ophthalmol*. 1998;8:127–30.
12. The Diabetes Control and Complications Trial (DCCT) Research Group. The effect of intensive treatment of diabetes on the development and progression of long-term complications in insulin-dependent diabetes mellitus. *New Engl J Med*. 1993;329:977–86.
13. Deeks JJ, Higgins JPT, Altman DG, editors. The Cochrane Library. Issue 4. Chichester, UK: John Wiley & Sons, Ltd; 2006. Analysing and presenting data. Cochrane Handbook for Systematic Reviews of Interventions 4.2.6 [updated September 2006]; Section 8.
14. Diabetic Retinopathy Study Research Group. Photocoagulation treatment of proliferative diabetic retinopathy: the second report of DRS findings. *Ophthalmol* 1978;85:82–106.
15. Early Treatment Diabetic Retinopathy Study Research Group. Photocoagulation for diabetic macular edema. Early Treatment Diabetic Retinopathy Study report number 1. *Arch Ophthalmol* 1985;103(12):1796–1806.
16. Glanville JM, Lefebvre C, Miles JN, Camosso-Stefinovic J. How to identify randomized controlled trials in MEDLINE: ten years on. *J Med Lib Assoc* 2006;94(2):130–6.
17. Higgins JPT, Green S, editors. The Cochrane Library. Issue 4. Chichester, UK: John Wiley & Sons, Ltd; 2006. Assessment of study quality. Cochrane Handbook for Systematic Reviews of Interventions 4.2.6 [updated September 2006]; Section 6.
18. Jonas JB, Kreissig I, Sofker A, Degenring RF. Intravitreal injection of triamcinolone for diffuse DME. *Arch Ophthalmol*. 2003;121:57–61.

19. Karacorlu M, Ozdemir H, Karacorlu S, Alacali N, Mudun B, Burumcek E. Intravitreal triamcinolone as a primary therapy in diabetic macular oedema. *Eye*. 2005;19(4):382–386.
20. Klein R, Klein BE, Moss SE, Davis MD, DeMets DL. The Wisconsin epidemiologic study of diabetic retinopathy. IV. Diabetic macular edema. *Ophthalmol* 1984;91(12):1464–74.
21. Massin P, Audren F, Haouchine B, Erginay A, Bergmann JF, Benosman R, et al. Intravitreal triamcinolone acetonide for diabetic diffuse macular edema: preliminary results of a prospective controlled trial. *Ophthalmol* 2004;111(2):218–24.
22. Tranos PG, Wickremasinghe SS, Stangos NT, Topouzis F, Tsinopoulos I, Pavesio CE. Macular edema. *Surv Ophthalmol* 2004;49(5):470–90.
23. UKPDS Group. Intensive blood-glucose control with sulphonylureas or insulin compared with conventional treatment and risk of complications in patients with type 2 diabetes (UKPDS 33). *Lancet* 1998;352(1998):837–53.
24. Williams R, Airey M, Baxter H, Forrester J, Kennedy-Martin T, Girach A. Epidemiology of diabetic retinopathy and macular oedema: a systematic review. *Eye* 2004;18(10):963–83.

How to cite this article: Soni P, Singh AK, Marndi SJ. Study of efficacy of intravitreal triamcinolone acetonide (IVTA) for the treatment of refractory diabetic macular edema (DME) in type 2 diabetes mellitus patients. *Indian J Clin Exp Ophthalmol* 2019;5(3):401-6.