

## Analysis of efficacy of intraoperative mitomycin C in external dacryocystorhinostomy

Srinivasan Gopalan<sup>1\*</sup>, Kalpana. Ramamoorthy<sup>2</sup>

<sup>1</sup>Assistant Professor, <sup>2</sup>Resident, Dept. of Ophthalmology, Saveetha Medical College and Hospital, Chennai, Tamil Nadu, India

### Article Info

Received: 22<sup>th</sup> February, 2019

Accepted: 8<sup>th</sup> May, 2019

Published Online: 9<sup>th</sup> September, 2019

**Keywords:** Complications, Dacryocystorhinostomy, Mitomycin C.

### Abstract

**Introduction:** The success of dacryocystorhinostomy (DCR) depends upon the patency of the lacrimal passage following the procedure. Mitomycin C has a wide application in Ophthalmology. In this present study, conventional external DCR was compared with external DCR where intra operative Mitomycin C was used, in order to prevent fibrosis at the osteotomy site following the procedure.

**Material and Methods:** There were 40 patients in this study who were divided into 2 groups. In group A, MMC was used intraoperatively at the osteotomy site for a period of five minutes. In Group B, Conventional External DCR was done without using an adjuvant. The study population included patients with acquired naso lacrimal duct obstruction. After the surgery, patients were assessed at 1<sup>st</sup> week, 1<sup>st</sup>, 3<sup>rd</sup> and 6<sup>th</sup> month respectively.

**Results:** The mean age of the study group was 40.29+/-9.53 years. Patients in both the groups were followed up regularly. Postoperatively at 6<sup>th</sup> month of visit, it was found that 1 (5%) out of 20 patients in Group A (MMC) and 4 patients (20%) among 20 in Group B (Conventional) reported with symptoms of watering of eyes and on examination had a high tear meniscus height, thereby had a non-patent lacrimal drainage system following surgery. On comparison there was a statistically significant difference between the two groups with the P value of 0.001. It was revealed that success rate was better in MMC group when compared with the Conventional group.

### Introduction

Dacryocystorhinostomy (DCR), can be done externally or endonasally. It is a highly successful procedure with a success rate of more than 80%. The patency of lacrimal passage following the surgery determines the outcome of this procedure.<sup>1,2</sup> Endonasal and external DCR was first described by Caldwell and Toti.<sup>3,4</sup> Eventually various modifications has been done which significantly led to the advancement of DCR surgery. Following dacryocystorhinostomy the osteotomy site gets blocked due to formation of adhesions which is the major cause of failure of this procedure in most of the patients.<sup>5</sup> This has been attributed to fibroblast proliferation which could lead to unsatisfactory results.

Introduction of antifibrotics like Mitomycin C (MMC) has reformed ophthalmology surgeries including dacryocystorhinostomy, pterygium and glaucoma procedures.<sup>6</sup> Mitomycin C obtained from soil bacterium *Streptomyces caespitosus* which is an antineoplastic and antiproliferative agent. It acts as a deoxyribonucleic acid cross-linker, which inhibits fibroblast proliferation. It is used in medicine as a chemotherapeutic agent. It has a wide application in Ophthalmology because of its modulatory effects on wound healing.<sup>7,8</sup> This study helps us to evaluate

the role of MMC in maintaining the postoperative patency of naso lacrimal passage.

### Materials and Methods

A prospective study from January 2018 to June 2018 held in a tertiary hospital. The total study population was 40 patients. There were 2 groups, group A (intra operative MMC group) and group B (Conventional) each comprised of 20 patients. The inclusion criteria were patients diagnosed with primary acquired naso lacrimal duct obstruction. Patients with acute dacryocystitis, obstruction secondary to canalicular obstruction, trauma or burns to the eye, malposition of puncta, mass lesion in the medial eyelid or lacrimal sac, lid laxity, significant nasal pathology, patients with anemia (Hb <7gm%) and with deranged coagulation profile were excluded from the study. All patients underwent a comprehensive examination which included slit lamp evaluation for a detailed assessment of ocular adnexa and external ocular surface lacrimal sac syringing was done and the outflow was assessed. A standard nasal examination was performed to rule out pathologies (septal deviation, middle turbinate hypertrophy, nasal polyps) that would affect the surgery. External dacryocystorhinostomy was done under local anaesthesia. In order to prepare Mitomycin C (concentration of 0.2mg/ml),

\*Corresponding Author: Srinivasan Gopalan, Assistant Professor, Dept. of Ophthalmology, Saveetha Medical College and Hospital, Chennai, Tamil Nadu, India

Email: [kgsvasans@gmail.com](mailto:kgsvasans@gmail.com)

<http://doi.org/10.18231/ijceo.2019.081>

to be used intra operatively, commercially available 2 mg vial is reconstituted with 10 ml of normal saline. Intraoperatively, a cottonoid or weck-cel sponge was soaked in the reconstituted solution and was applied at the osteotomy site for 5mins. Utmost care was taken to avoid direct contact of Mitomycin C with the skin edges of the wound, as this may result in impaired wound healing and possible postoperative wound dehiscence. Patients were followed up at 1<sup>st</sup> week 1<sup>st</sup> month, 3<sup>rd</sup> month and 6<sup>th</sup> month postoperatively. Analysis of results was done using SPSS Software (version 22) with P values < 0.05% was considered statistically significant. Chi square test was used to compare the variables.

**Results**

**Group A:** External dacryocystorhinostomy along with intra operative MMC (20 patients)

**Group B:** Conventional External DCR without intra operative MMC (20 patients)

**Age Distribution**

The age distribution of the study group was 40.29+/-9.53 years with P value of 0.398 (P value >0.05) which was not significant (Table 1)

**Table 1:** Age distribution in study population

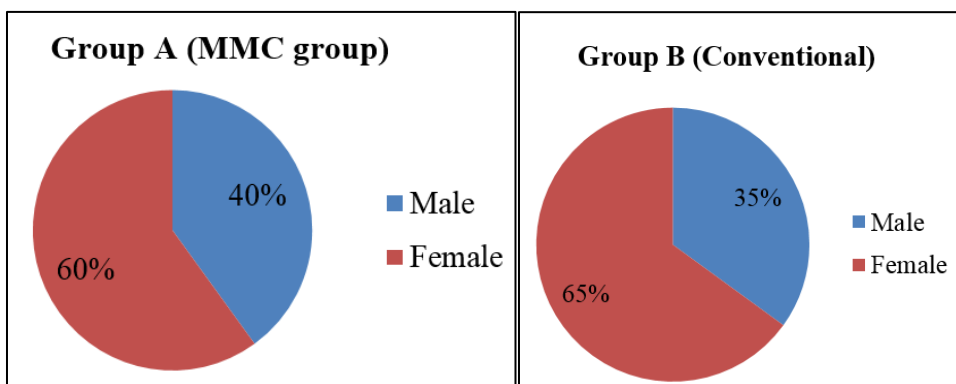
Age group	Study group		Chi-square	P value
	Group A Mitomycin c N=20	Group B Conventional N=20		
<30 Years	3(15%)	3(15%)	4.056	0.398
31-40 years	5(25%)	4(20%)		
41-50 years	6(30%)	6(30%)		
51-60 years	3(15%)	5(25%)		
>60 years	3(15%)	2(10%)		

**Gender Distribution**

In Group A 8 (40%) males and 12 (60%) females underwent DCR with adjuvant MMC and 7 (35%) males and 13 (65%) females underwent DCR in Group B MMC was not used. (Table 2)(Fig. 1)

**Table 2:** Descriptive analysis of gender in study population

Gender	Study group		Chi-square	P value
	Mitomycin C N=20	Conventional N=20		
Male	8(40%)	7(35%)	0.533	0.465
Female	12(60%)	13(65%)		



**Fig. 1:** Gender distribution in the study population

**Laterality of eye**

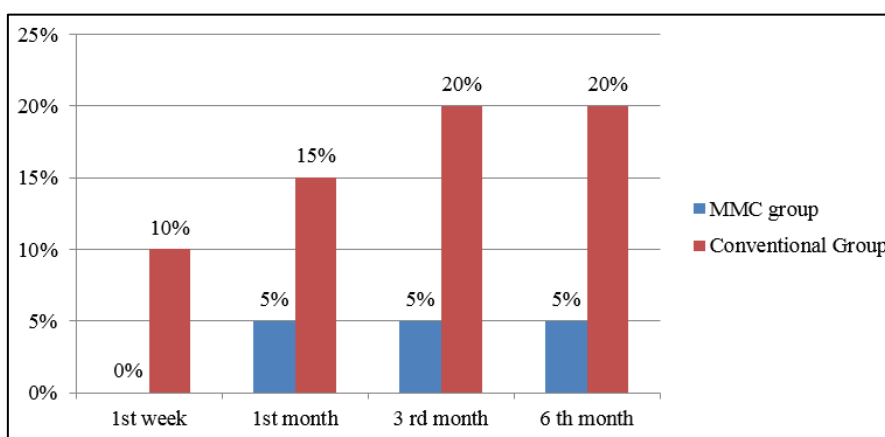
Based on laterality, the study population was compared and the P value was not significant (P value-0.123) (Table 3)

**Table 3:** Comparison of study population based on laterality

Laterality	Study group		Chi-square	P value
	Mitomycin C N=20	Conventional N=20		
Right side	13(65%)	15(75%)	2.381	0.123
Left side	7(35%)	5(25%)		

**Table 4:** Comparison of study group based on post-operative follow-up

Follow up	Group	Symptom		Lacrimal Sac Syringing		Tear meniscus height	
		No	Yes	Patent	Not patent	Normal	High
1 <sup>st</sup> week	MMC (N=20)	20(100%)	0(0%)	20(100%)	0(0%)	20(100%)	0(0%)
	Conventional(N=20)	18(90%)	2(10%)	18(90%)	2(10%)	18(90%)	2(10%)
	<b>P value</b>	*		*		*	
1 <sup>st</sup> month	MMC (N=20)	19(95%)	1(5%)	19(95%)	1(5%)	19(95%)	1(5%)
	Conventional(N=20)	17(85%)	3(15%)	17(85%)	3(15%)	17(85%)	3(15%)
	<b>P value</b>	0.018		0.018		0.018	
3 <sup>rd</sup> month	MMC(N=20)	19(95%)	1(5%)	19(95%)	1(5%)	19(95%)	1(5%)
	Conventional(N=20)	16(80%)	4(20%)	16(80%)	4(20%)	16(80%)	4(20%)
	<b>P value</b>	0.001		0.001		0.001	
6 <sup>th</sup> month	MMC (N=20)	19(95%)	1(5%)	19(95%)	1(5%)	19(95%)	1(5%)
	Conventional(N=20)	16(80%)	4(20%)	16(80%)	4(20%)	16(80%)	4(20%)
	<b>P value</b>	0.001		0.001		0.001	

**Fig. 2:** Comparison of study group based on post-operative follow-up

### Postoperative follow up

Postoperatively (Table 4) (Fig. 2), the patients were followed up at 1<sup>st</sup> week, 1<sup>st</sup> month, 3<sup>rd</sup> month and 6<sup>th</sup> month. Patients were assessed based on symptoms (watering of eyes), tear meniscus height and lacrimal sac syringing. Based on the observation, it was found that at 6<sup>th</sup> month of follow up postoperatively, with 20 patients each group, only 1 patient (5%) in Group A and 4 patients (20%) in Group B had a non patent lacrimal drainage system. The P value was 0.001 and difference between the two groups was significant.

### Discussion

Following dacryocystorhinostomy (DCR,) scarring and subsequent cicatricial closure of the osteotomy site is quite common.<sup>13,14</sup> Mitomycin C (MMC) is used as an adjuvant thereby helps in preventing such complications. Success rate is better in patients where External DCR is done along with an intra operative antifibrotic - Mitomycin C when compared to patients in whom only conventional external dacryocystorhinostomy is done.<sup>15</sup>

In DCR surgery, the efficacy of intra operative MMC (0.2mg/ml) was compared with control group undergoing Conventional DCR in Liao *et al.*<sup>16</sup> It was found that non

patency rate was 4.5% among 44 patients in MMC group and 11.4% among 44 patients in the control group after 10 months of follow up postoperatively ( $P < 0.05$ ).

Histo pathological effects of MMC on transnasal DCR by using intraoperative MMC (0.5mg/ml) at the osteotomy site was assessed by Ugurbas *et al.*<sup>17</sup> Light and electron microscopy examination of the intra operative and post operative specimens which were collected from 4 patients at day 15<sup>th</sup>, 1<sup>st</sup> month and 6<sup>th</sup> month, revealed attenuated epithelium and looser hypo cellular sub epithelial connective tissue in the MMC specimens and this serves as an evidence to know the potency of MMC application at the osteotomy site when used intra operatively. In our study, with 20 patients in each group, at 6<sup>th</sup> month of post operative follow up following DCR, only 1 (5%) patient in the Mitomycin C group whereas 4 (20%) patients (N=20) in the Conventional group reported unsatisfactory results following external dacryocystorhinostomy. There was a statistically significant difference between the two groups with a P value of 0.001.

### Conclusion

Application of an adjuvant like Mitomycin C intraoperatively, helps to improve the success rate of external dacryocystorhinostomy and hence can be considered

as a safe and effective modification in conventional dacryocystorhinostomy.

**Source of Funding:** None.

**Conflict of Interest:** None.

## References

1. Walland MJ, Rose GE. Factors affecting the success rate of open lacrimal surgery. *Br J Ophthalmol*. 1994;78:888-91.
2. Tarbet KJ, Custer PL. External dacryocystorhinostomy: surgical success, patient satisfaction, and economic cost. *Ophthalmol* 1995;102:1065-70.
3. Toti A. Nuovometodoconservatore di cura radicle delle sup-purazonicroniche del saccolacrimale (Dacriocistorinostomia). *Clin Mod Fir* 1904;10:3857.
4. Caldwell GW. Two new operations for obstruction of the nasal duct with preservation of the canaliculi and an incidental description of a new lachrymal probe. *NY Med J* 1893;57:581.
5. Qian Z, Zhang Y, Fan X. Clinical outcomes of dacryocystorhinostomy with or without intraoperative use of mitomycin C: a systematic review and metaanalysis. *Journal of ocular pharmacology and therapeutics. J Assoc Ocular Pharmacol Ther* 2014;30(8):615-24.
6. Mearza AA, Aslanides Saf. Uses and complications of Mitomycin C in ophthalmology. *Expert Opin Drug Saf*. 2007;6(1):27-32.
7. Wakaki S, Marumo H, Tomioka K, Shimizu G, Kato E, Kamada H, et al. Isolation of new fractions of antitumor mitomycins. *Antibiotics Chemother*. 1958;8(5):228-40.
8. Goodman LS, Brunton LL, Chabner B, Knollmann Br C. Goodman & Gilman's pharmacological basis of therapeutics. 12th ed. *New York: McGraw-Hill*; 2011. 2084
9. Dresner SC, Klussman KG, Meyer DR. Outpatient dacryocystorhinostomy. *Ophthalmic Surg*. 1991;22:222-4.
10. McNab A. Dacryocystorhinostomy. In *Manual of Orbital and Lacrimal surgery*. Butterworth-Hienemann. 2nd Ed 1998.
11. Rosen N, Mordechai S, Moverman DC. Dacryocystorhinostomy with silicone tubes: Evaluation of 253 cases. *Ophthalmic Surg*. 1989;20:115-9.
12. Olver J. External dacryocystorhinostomy. In *Colour Atlas of Lacrimal Surgery*. Butterworth-Hienemann. 1st Ed 2006.
13. Yildirim C, Yaylali V, Esme A, Ozden S. Long-term results of adjunctive use of mitomycin C in external dacryocystorhinostomy. *Int Ophthalmol*. 2007;27:31-5.
14. Cokkeser Y, Evereklioglu C, Er H. Comparative external versus endoscopic dacryocystorhinostomy: Results in 115 patients (130 eyes). *Otolaryngol Head Neck Surg* 2000;123:488-91.
15. McLachlan DL, Shannon GM, Flanagan JC. Results of dacryocystorhinostomy: analysis of the reoperations. *Ophthalmic Surg*. 1980;11:427-30.
16. Liao SL, Kao CS, Tseng JH. Results of intraoperative mitomycin C application in dacryocystorhinostomy. *Br J Ophthalmol*. 2000;84:903-6.
17. Ugurbas SH, Zilelioglu G, Sargon MF. Histopathologic effects of mitomycin-C on endoscopic transnasal dacryocystorhinostomy. *Ophthalmic Surg Lasers* 1997;28:300-4.
18. Feng YF, Yu JG, Shi JL, Huang JH, Sun YL, Zhao YE. A metaanalysis of primary external dacryocystorhinostomy with and without mitomycin C. *Ophthalmic Epidemiol* 2012;19:36470.
19. Baldeschi L, Nardi M, Hintschich CR, Koornneef I. Anterior suspended flaps: A modified approach for external dacryocystorhinostomy. *Br Ophthalmol* 1998;82:790-2.
20. Ali MJ, Mariappan I, Maddileti S, Ali MH, Naik MN. Mitomycin C in dacryocystorhinostomy: the search for the right concentration and duration--a fundamental study on human nasal mucosa fibroblasts. *Ophthalmic Plastic Reconstr Surg* 2013;29(6):469-74.
21. Li B, Wang, W.N., Pen, X.H., and Du, L.Q. Application of mitomycin C in dacryocystorhinostomy. *Adv Ophthalmol* 2003;23:463-4.

**How to cite this article:** Gopalan S, Kalpana R. Analysis of efficacy of intraoperative mitomycin C in external dacryocystorhinostomy. *Indian J Clin Exp Ophthalmol* 2019;5(3):339-42.