

## A novel approach of subconjunctival Mitomycin C injection at the end of trabeculectomy for secondary glaucoma: A pilot study

Ved Prakash Gupta<sup>1\*</sup>, Nitika Beri<sup>2</sup>, Jolly Rohatgi<sup>3</sup>

<sup>1</sup>Director Professor, <sup>2</sup>3<sup>rd</sup> Year Resident, <sup>3</sup>Professor, Dept. of Ophthalmology, University College of Medical Sciences, Delhi, India

\*Corresponding Author: Ved Prakash Gupta

Email: vpg275gv@yahoo.co.in

### Abstract

**Purpose:** To describe for the first time, a new approach of subconjunctival Mitomycin-C (MMC) injection at the end trabeculectomy for secondary glaucoma.

**Materials and Methods:** This pilot study consisted of 4 eyes of 4 patients of uncontrolled secondary glaucoma. After preoperative glaucoma workup, all patients underwent standard trabeculectomy with subconjunctival MMC injection, 0.1 ml (0.02mg) in superonasal quadrant at the end of surgery. Postoperative follow-up included assessment of visual acuity, intraocular pressure (IOP), bleb, anterior chamber depth and for any complications. The success criterion was IOP of  $\leq 21$  mmHg.

**Results:** The mean pre and postoperative IOP were  $43 \text{ mmHg} \pm 16.2$  and  $12.00 \text{ mmHg} \pm 1.6$  respectively with a success rate of 100% during a mean follow up of 15.5 months. Blebs were mildly elevated, diffuse and less avascular. No intraoperative complications were seen. Postoperative wound leak, flat anterior chamber, hypotony, choroidal detachment or endophthalmitis were not encountered.

**Conclusion:** This novel approach of subconjunctival MMC injection at the end of trabeculectomy was found to be safe and highly effective in secondary glaucoma without any MMC related complications.

**Keywords:** Mitomycin C, Subconjunctival injection, Secondary glaucoma, Trabeculectomy.

### Introduction

A variety of surgical methods are available for treatment of glaucoma which include trabeculectomy with or without use of antimetabolites, deep sclerectomy, canaloplasty and shunt procedures etc. However, trabeculectomy is still the 'gold standard' among the different surgical methods.<sup>1</sup>

The success rate of trabeculectomy decreases on long term follow up (FU) e.g. 83% at 5 year, 73% at 10 years and 42% at 15 years according to one study.<sup>2</sup> This failure has been attributed to scarring of the drainage fistula created and hence antimetabolites like Mitomycin-C (MMC) and 5-Fluorouracil (5-FU) have been used. MMC is an agent that prevents scarring by inhibiting the multiplication of cells that produce scar tissue. MMC soaked sponges have been applied under the conjunctivo-tenon flap prior to scleral flap dissection in different concentrations as well as for different durations.

Complications reported with the use of MMC in trabeculectomy are hypotony, shallow anterior chamber (AC), choroidal detachment, cystic blebs, leaking blebs, blebitis and late-onset endophthalmitis.<sup>3-6</sup> Other concerns with the use of MMC soaked sponges are lack of ability to determine the actual quantity of the drug delivered to the tissue, non-availability of standard sponge material or size, leading to inconsistent and unreliable absorption of MMC into sponge material. Also, the effect of irrigating the site of MMC application with saline is not constant and surgeons must use multiple sponges for a more diffuse application which increases the risk of retained sponge fragments.<sup>7</sup>

To overcome the limitations of sponge application of MMC, intra Tenon/subconjunctival injection of MMC has recently been tried.<sup>7-11</sup> The advantages of this method claimed are delivery of titrated and consistent dose of MMC to the surgical site, uniform and diffuse area of application of

MMC without the risk of retained sponge fragments and less time consuming. Although despite these advantages,<sup>7-11</sup> various studies have reported a high complication rate<sup>7-10</sup> with injecting MMC prior to the initial conjunctival incision.

Hence, we designed this study to describe a new approach of subconjunctival injection of MMC at the end of trabeculectomy to overcome the complications of injecting MMC prior to the initial conjunctival incision. To the best of our review of literature no such study is available.

### Materials and Methods

This pilot study included 4 patients of uncontrolled secondary glaucoma from March 2017 to August 2018 after approval by Institutional Ethics Committee. The study adhered to the tenets of the declaration of Helsinki.

Patients with failed trabeculectomy, dry eyes, viral keratitis, active uveitis and pregnant or lactating females were excluded. Complete success was defined as postoperative intraocular pressure (IOP)  $\leq 21$  mmHg and achieving the same with antiglaucoma drugs was defined as qualified success.

A detailed glaucoma workup including pre and postoperative IOP measurement by ton open was done. Standard trabeculectomy was performed with limbal based conjunctival - Tenon flap and 4mm x 4mm x 4mm triangular partial thickness scleral flap at 12 o'clock position (Fig. 1A). The scleral flap was closed tightly with 7 (10-0 nylon) sutures (Fig. 1B). The conjunctival-Tenon flap was closed using continuous (10-0 nylon) sutures (Fig. 1C). Subconjunctival injection of MMC 0.1 ml [0.02mg] was injected 10 mm above the limbus and 2 mm medial to superior rectus muscle (Fig. 1D). Subconjunctival gentamicin 0.5 ml + dexamethasone 0.5 ml was injected in the inferior fornix followed by pad and bandage with atropine eye ointment.

Post-operatively, all patients were bandaged with moxifloxacin 0.5% and atropine 1% eye ointment daily for 3 days followed by topical moxifloxacin 0.5%, homatropine 2% and prednisolone acetate 1%, 4 times a day for 2 weeks.

FU was done on postoperative day one, weekly for a month and periodically at regular intervals thereafter.

## Results

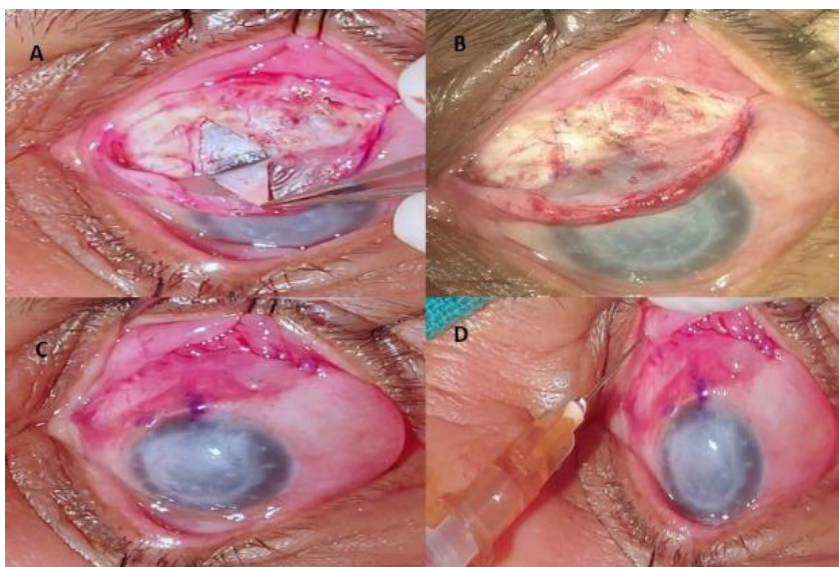
This procedure was tried in 4 patients of uncontrolled secondary glaucoma caused by penetrating keratoplasty (3) and trauma (1). Two males and 2 females with mean age of 48.5 years were included. The clinical data are mentioned in Table 1.

The baseline mean IOP was  $43 \text{ mmHg} \pm 16.2$  (range 28 to  $64 \text{ mmHg}$ ). The mean postoperative IOP on day 1, day 7, 1 month, 3 month and at last FU was  $9.5 \text{ mmHg} \pm 3.7$ ,  $14.00 \text{ mmHg} \pm 8.8$ ,  $10.75 \text{ mmHg} \pm 2.8$ ,  $13.25 \text{ mmHg} \pm 3.8$  and

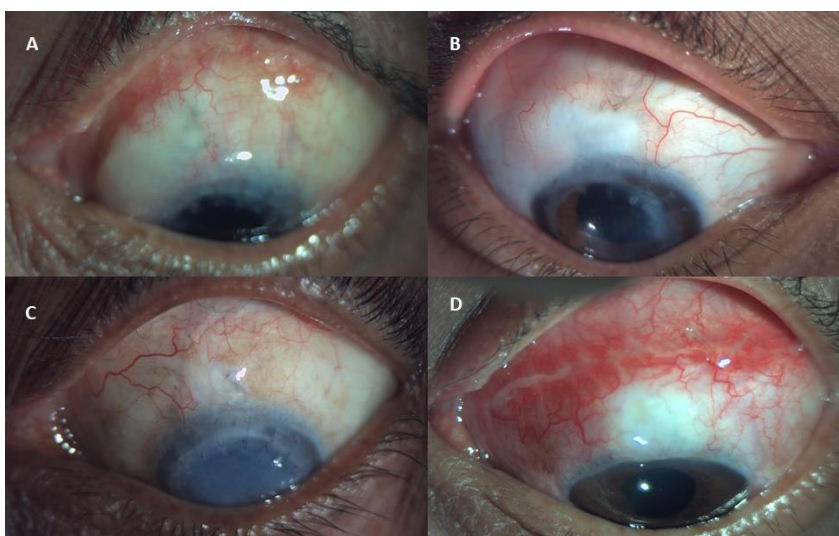$12.00 \text{ mmHg} \pm 1.6$  respectively. The reduction in IOP from base line was significant ( $p < 0.05$ ) at each FU. The mean IOP reduction from base line was 68.75% at last FU (Mean FU of 15.5 months). Majority of blebs (75%) obtained were small, diffuse, mildly elevated and less avascular (Fig. 2B-D) except in 25% patients with larger blebs (Fig. 2A). None of the patients had thin and cystic blebs.

None of the patients had complications like hypotony, flat AC, choroidal detachment, bleb leaks and endophthalmitis. No wound leak or clinical evidence of subconjunctival fibrosis were noted at the site of MMC injection. No patient required additional glaucoma surgery postoperatively.

All (100%) patients had complete success during a mean FU of 15.5 months (range 9 months-18 months). The IOP variation at various intervals of FU are reported in table 2.



**Fig.1: A: Reflected partial thickness triangular scleral flap; B: Scleral flap closed with 7 sutures; C: Conjunctival flap sutured; D: Injection MMC at the end of surgery**



**Fig. 2A: Large bleb post-operatively; B to D: Small bleb post-operatively**

**Table 1: Brief clinical details of series of 4 patients**

| Patient | Age (years)<br>Sex | Diagnosis                           | Base line<br>IOP<br>(mmHg) | Post op IOP<br>at<br>Last FU<br>(mmHg) | % IOP<br>decrease<br>at last<br>FU | Condition of<br>bleb at last FU                              | Complications | Success  | FU<br>(Months) |
|---------|--------------------|-------------------------------------|----------------------------|--|------------------------------------|--|---------------|----------|----------------|
| 1       | 60 Male            | Post PKP<br>glaucoma<br>OS          | 48                         | 12                                     | 75                                 | Large, diffuse,<br>moderately<br>elevated, Less<br>avascular | None          | Complete | 18             |
| 2       | 21 Female          | Post PKP<br>glaucoma<br>OD          | 32                         | 10                                     | 69                                 | Small, diffuse,<br>mildly elevated,<br>Less avascular        | None          | Complete | 18             |
| 3       | 65 Female          | Post PKP<br>glaucoma<br>OS          | 28                         | 14                                     | 50                                 | -do-   | None          | Complete | 17             |
| 4       | 48 Male            | Post<br>traumatic<br>glaucoma<br>OS | 64                         | 12                                     | 81                                 | -do-   | None          | Complete | 9              |

IOP= intraocular pressure, Post op= postoperative, FU= follow up, %=percentage, PKP=penetrating keratoplasty.

**Table 2: Post-operative IOP at different visits**

|  | Patient 1 | Patient 2 | Patient 3 | Patient 4 |
|--|-----------|-----------|-----------|-----------|
| Baseline IOP (mmHg)                      | 48        | 32        | 28        | 64        |
| Post Op IOP                              |           |           |           |           |
| Day1 (mmHg)                              | 8         | 5         | 13        | 12        |
| Week1 (mmHg)                             | 14        | 5         | 26        | 11        |
| 3Mo (mmHg)                               | 17        | 8         | 14        | 14        |
| 6Mo (mmHg)                               | 12        | 9         | 17        | 12        |
| 9Mo (mmHg)                               | 14        | 9         | 12        | 12        |
| 12Mo (mmHg)                              | 13        | 9         | 14        | -         |
| 15Mo (mmHg)                              | 16        | 10        | 16        | -         |
| 18Mo (mmHg)                              | 15        | 10        | -         | -         |
| Absolute IOP reduction at last FU (mmHg) | 33        | 22        | 12        | 52        |
| % IOP reduction at last FU               | 69%       | 69%       | 43%       | 81%       |

Key: M=male, F=female, post op=postoperative, Mo=month, IOP=intraocular pressure, FU=follow up, %=percentage.

## Discussion

The disadvantages of sponge application of MMC are lack of ability to determine the actual quantity of the drug being delivered to the tissue, non-availability of standard sponge material or size leading to inconsistent and unreliable absorption of MMC into sponge material.<sup>7</sup> Also, the effect of irrigating the site of MMC application with saline is variable and surgeons must use multiple sponges for a more diffuse application which increases the risk of retained sponge fragments.<sup>7</sup>

To overcome the above disadvantages, a recent approach of augmenting trabeculectomy with intraoperative injection of MMC has been described in literature.<sup>7,11</sup> The advantages claimed by various studies<sup>7-11</sup> are delivery of titrated and constant dose of anti-metabolite to the surgical site, uniform and diffuse area of application of MMC without the risk of retained sponge fragments and time saving. The success rate in these studies has been reported to be between 80%-89%.<sup>8,10,11</sup>

However, these studies reported a high complication rate with injecting MMC prior to the initial conjunctival incision.<sup>7-10</sup> The complications observed include hypotony

(11%-26%), bleb leak (5%-26%), shallow AC (27%), choroidal detachment (15.7%), hyphema (14.8%), need for postoperative bleb needling with 5-fluorouracil (10%-26.9%), and cataract progression in 7.4% of patients.<sup>7-10</sup>

We thought of a novel technique, to overcome the above complications, by injecting MMC at the end of trabeculectomy. None of the above complications were encountered in a series of 4 patients of uncontrolled secondary glaucoma with a 100% complete success rate with a mean FU of 15.5 months.

We believe that the high success rate in our study could be due to injection of MMC at the end of surgery which ensured consistency in availability of a calculated dose of MMC and also ensured its diffusion and exposure over a wider area including the conjunctival flap as well as posterior to sutured conjunctival flap. We also believe that injected MMC is diffused and exposed in large area anterior and posterior to injection site, which could be responsible for a diffusely elevated bleb avoiding the occurrence of thin blebs.

Lee et al,<sup>8</sup> Lim et al<sup>11</sup> and Pakravan et al<sup>9</sup> in their technique washed the site with saline after MMC injection hence it appears that the actual dose retained cannot be

calculated.

Encouraging safety profile in our study is attributed to the tight closer of scleral flap with seven sutures to help decrease the chances of hypotony and flat AC without adversely affecting the functioning of the bleb till last FU. Lee et al<sup>8</sup> applied 3 releasable sutures on the scleral flap, Pakravan et al<sup>9</sup> and Khouri et al<sup>7</sup> applied 2 sutures on the scleral flap. Our technique also avoided inadvertent exposure of conjunctival wound edges to MMC which might have prevented chances of conjunctival wound leak.

It is, thus, concluded that our new technique of subconjunctival MMC injection at the end of trabeculectomy appears very safe and highly effective (100% complete success) in reducing IOP in patients of uncontrolled secondary glaucoma. None of the patients in the study developed any MMC related complications like shallow AC, hypotony, bleb leak or endophthalmitis.

This is the first study in the world literature to describe subconjunctival injection of MMC at the end of trabeculectomy for secondary glaucoma. Our results were favourable with a good success rate and encouraging safety profile. Limitations of the study include less number of patients, non-comparative nature of study and shorter FU. It is suggested that this approach may be tried in primary open angle and closure glaucoma patients. Also, further randomized studies comparing trabeculectomy with MMC sponge application with those of MMC injection before and after surgery should be tried in larger sample size and longer duration of FU to assess the safety and efficacy of this novel approach in other ethnic groups.

**Conflict of Interest:** None.

## References

1. Kirwan JF, Lockwood AJ, Shah P. Trabeculectomy in the 21st century: a multicenter analysis. *Ophthalmol* 2013;120(12):2532-9.
2. Wilensky JT, Chen TC. Long-term results of trabeculectomy in eyes that were initially successful. *Trans Am Ophthalmol Soc* 1996;94:147.
3. Greenfield DS, Suner IJ, Miller MP, Kangas TA, Palmberg PF, Flynn HW Jr. Endophthalmitis after filtering surgery with Mitomycin. *Arch Ophthalmol* 1996;114: 943-9.
4. Solomon A, Ticho U, Frucht-Pery J. Late-onset, bleb-associated endophthalmitis following glaucoma filtering surgery with or without antifibrotic agents. *J Ocul Pharmacol Ther* 1999;15:283-93.
5. Ayyala RS, Bellows AR, Thomas JV, Hutchinson BT. Bleb infections; clinically different courses of blebitis and endophthalmitis. *Ophthalmic Surg Lasers* 1997;28:452-60.
6. DeBry PW, Perkins TW, Heatley G, Kaufman P, Brumback LC. Incidence of late-onset bleb-related complications following trabeculectomy with mitomycin. *Arch Ophthalmol* 2002;120:297-300.
7. S Khouri A, Huang G, Y Huang L. Intraoperative Injection vs Sponge-applied Mitomycin C during Trabeculectomy: One-year Study. *J Curr Glaucoma Pract.* 2017;11(3):101-6.
8. Lee E, Doyle E, Jenkins C. Trabeculectomy surgery augmented with intra-Tenon injection of mitomycin C. *Acta Ophthalmol* 2008;86:866-70.
9. Pakravan M, Esfandiari H, Yazdani S. Mitomycin C-augmented trabeculectomy: subtenon injection versus soaked sponges: a randomized clinical trial. *Br J Ophthalmol* 2017;101(9):1275-80.
10. Mostafaei A. Augmenting trabeculectomy in glaucoma with subconjunctival mitomycin C versus subconjunctival 5-fluorouracil: a randomized clinical trial. *Clin Ophthalmol* 2011;5:491.
11. Lim MC, Paul T, Tong MG, Brandt JD, Watnik MR, Samimi SA. A comparison of trabeculectomy surgery outcomes with mitomycin-C applied by intra-tenon injection versus sponge method. American Glaucoma Society 23<sup>rd</sup> Annual Meeting, Chapter 19, Paper abstracts – Glaucoma Management and Therapy.

**How to cite this article:** Gupta VP, Beri N, Rohatgi J. A novel approach of subconjunctival Mitomycin C injection at the end of trabeculectomy for secondary glaucoma: A pilot study. *Indian J Clin Exp Ophthalmol* 2019;5(2):268-71.