

# Botulinum Toxin: A Clinical Update on Ophthalmic Uses

Shraddha Panday<sup>1,\*</sup>, Rajendra P. Maurya<sup>2</sup>, Virendra P. Singh<sup>3</sup>,  
Mahendra K Singh<sup>4</sup>, Ishan Yadav<sup>5</sup>, Sujit Deshmukh<sup>6</sup>

<sup>1</sup>Junior Resident, <sup>2</sup>Assistant Professor, <sup>3,4</sup>Professor, <sup>5,6</sup>Senior Resident, Department of Ophthalmology, Institute of Medical Sciences, Banaras Hindu University, Varanasi-221005, U.P., India

\*Corresponding Author:

Email: shraddha2315@gmail.com

## ABSTRACT

**Aim:** To review the role of botulinum toxin in ophthalmology; its indications and side effects.

**Method:** A literature search on pubmed was performed and articles explaining the role of botulinum toxin in ophthalmology were reviewed

**Result:** Botulinum toxin is being widely used in ophthalmology for various indications like Essential Blepharospasm, Myokymia, Eyelid apraxia, Strabismus, Hyperlacrimation, Spastic entropion and Cosmetic uses. Complications of the injection include local effects like ecchymosis, pain or infection and spill over effects like ptosis, diplopia, lagophthalmos, mid facial weakness and dry eyes.

**Conclusion:** There are various implications of botulinum toxin in ophthalmology. When considering its application in clinical practice, one should be careful of the indications, risks and benefits of the procedure. When properly delivered it is a potential, efficacious, minimally-invasive treatment modality.

**Key Words:** Apraxia of Eyelid Opening, Botulinum toxin, Essential Blepharospasm, Eyelid myokymia, Spastic Entropion

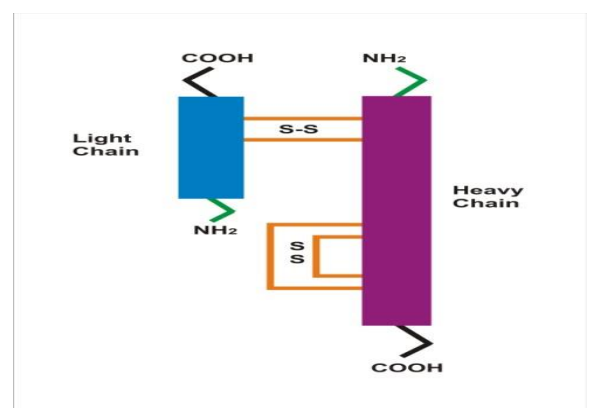
Access this article online	
Quick Response Code:	Website: www.innovativepublication.com
	DOI: 10.5958/2395-1451.2015.00001.3

## INTRODUCTION

Botulinum toxin is most potent exotoxin, having various therapeutic and aesthetic uses. Its therapeutic use was first described by an ophthalmologist Dr Alan Scott in 1973 to treat the surgically induced strabismus in monkey[1]. He produced botulinum toxin type A under the trade name Oculinum (Allergan Inc. USA) which was approved by US Food and Drug Administration (FDA) for strabismus patients in 1979. Botulinum toxin was utilized for treatment of blepharospasm since 1982 but gained FDA approval in 1989. Later on in 1991 Allergan purchased the right to produce botulinum toxin A and changed the name as Botox. In Europe and Asia botulinum toxin type A is marketed as Dysport (Beaufour Ipsen Biotech France). In 2000 botulinum toxin B was approved for treatment of cervical dystonia under trade name of Myobloc (Elan pharmaceuticals Dublin Ireland). Botox gained FDA approval for cosmetic use in 2002 as it decreased the depth and appearance of kinetic facial lines [2-4]. Currently botulinum toxin is approved for treatment of more than 20 conditions including variety of spastic disorders, hyperhidrosis, strabismus and cosmetic indications etc [5,6].

## PHARMACOLOGY

**Botulinum toxin** is a neuroprotective protein produced by anaerobic, Gram-positive bacterium *Clostridium botulinum* and related species. The active toxin is a two-chain protein, composed of a 100-kDa heavy chain and 50-kDa light chain polypeptide joined by a single disulfide bond which bound to a variety of nontoxin stabilizing proteins[7]. There are seven serologically distinct types of toxin (A to G), having different tertiary structures and significant sequence divergence. Each serotype produced by different strains of *Clostridium*[8]. Serotype E is produced by *Clostridium butyricum* and type F is produced by *Clostridium bartii*. Type A, B and E toxins affects humans and cause systemic botulism.



**Figure1: Molecular structure of Botulinum toxin. It consists of Light and Heavy chain joined by disulfide bond.**

The heavy chain is responsible for binding to nerve terminal receptors and light chain of toxin responsible for blocking the release of acetylcholine from nerve terminals by inactivating group of protein. It cleaves *synaptosomal-associated protein* (SNAP-25), a protein which form the SNARE (*soluble N-ethylmaleimide-sensitive factor attachment receptor* (SNARE) involved in vesicle fusion and mediating release of neurotransmitter acetylcholine, from axon endings. Cleavage of the SNARE proteins inhibits release of acetylcholine. In inhibiting acetylcholine release, nerve impulses are blocked, causing the flaccid (sagging) Paralysis of muscles characteristic of botulism [9].

Toxin serotype A and B differs in their binding site and target molecules in the presynaptic nerve terminal[10,11]. The effect of botulinum is usually noticed within 3 to 4 days and lasts between 3 to 4 months. The botulinum toxin is inactivated by heat 85°C or greater in 5 minutes[12-16].

Toxin is contraindicated in pregnancy, nursing mothers, children and in patients with a known hypersensitivity to proteins like egg albumin[17]. Botulinum toxin have drug interaction with aminoglycosides (e.g. gentamycine, tobramycin, streptomycin) and drug interfering neuromuscular transmission like curarin, succinylcholine. Commonest side effects are headache, dizziness, nausea, diplopia and ptosis also have been reported [18].

### Commercial Formulations

Serotype A is the only commercially available form of botulinum toxin for clinical use, although experience is emerging with development of other serotypes: B, C, and F preparations [19]. Two preparations of botulinum toxin A are approved for use: Dysport and Botox. Botox is a sterile, vacuum-dried powder form of botulinum toxin type A which requires reconstitution with 0.9% normal saline. It is produced from a culture of the Hall strain of *C. botulinum* and purified by a series of acid precipitations. Botox is stored in a freezer at or below -5°C. Some investigators suggest that reconstitution with sterile saline solution with preservative (0.9% benzyl alcohol) reduces microbial contamination and provides a weak local anaesthetic effect [20].

Botox is denatured easily by bubbling or agitation; gently inject the diluent onto the inside wall of the vial and discard the vial if a vacuum does not pull the diluent in. The final dilution of Botox is mostly a matter of personal preference; 100 units commonly are reconstituted in 1-10 ml of diluent.

Once reconstituted, Botox is kept refrigerated at 2-8°C. The Botox reconstituted with non-preserved saline should be used within 4 hours[21]. However Botox reconstituted by preserved saline can be refrigerated upto 2 weeks.

## THERAPEUTIC USES IN OPHTHALMOLOGY

### Benign Essential Blepharospasm

Essential blepharospasm is characterized by bilateral, repetitive and uncontrolled clonic contractions of the orbicularis oculi muscle. It manifests as involuntary orbicularis muscle contraction resulting in increased frequency of blinking. In severe cases, blinking is repetitive and forceful, resulting in functional blindness. The etiology remains unknown, but may involve dysfunction of the central coordination of visual sensory input and motor output to the eyelids. Patients have increased sensitivity to visual stimuli and an exaggerated motor response manifested as excessive blinking and forced eyelid closure.

Botulinum toxin (BT) has been used in the treatment of blepharospasm (BSP) since 1983 and is the treatment of choice for controlling eyelid spasms. Studies show type A toxin to be effective in 70%–90% of patients. The average dose of toxin type A is 12.5–25 units per eye, injected into the orbicularis muscle. Typically, Botox (botulinum toxin type A) is injected into the medial and lateral portions of the pretarsal orbicularis in both the upper and lower eyelids, and often into the eyebrows as well. Treatment benefit lasts upto an average of 13 weeks. In cases where type A becomes ineffective, one can use botulinum toxin type B, using 750 to 2500 units per eye. In our experience, type B has a shorter duration of effect (8–10 weeks) and shows a greater tendency to diffuse to adjacent areas. Potential adverse effects following the use of botulinum toxin around the eye include ecchymosis, ptosis, diplopia, midfacial weakness, lagophthalmos, and dry eye. Ptosis is the most common complication related to spread of the chemodenervation to the levator muscle. It is seen in 10%–15% of treated patients. Typically, this is mild and of little or no functional consequence. In most cases, complications are mild, transient, and can be minimized with appropriate injection technique. Botulinum toxin has also been used in children with congenital blepharospasm. The botulinum toxin injection resulted in a normal visual development of the child; otherwise, sensory deprivation would have occurred. Botulinum toxin can therefore be helpful to treat special conditions even in very young children without any significant side effects of the neurotoxin[22].

Kollewe et al studied treatment, efficacy and adverse effect data on Blepharospasm in patients treated with either Botox®, Dysport® or Xeomin® for at least eight consecutive injections. Adverse effects were rare, mild and always transient. BT therapy is a safe and effective treatment for BSP. Shorter inter-injection intervals may improve therapeutic results [23].

Ramirez-Casteneda et al carried out retrospective, longitudinal study that analyzed data on 89 patients treated with Botulinum for dystonia at Movement Disorders Clinic for up to 26 years (mean follow-up period of 18.5 years)[24]. This series of dystonia patients with the longest reported treatment with Botulinum provide evidence that in selected patients repeated chemo denervation is associated with sustained symptomatic benefit, decreased latency effect, and prolonged duration of therapeutic response. Despite the higher requirement of mean units per visit over time, only 19% of all treatment cycles are associated with adverse, but tolerable, side effects. Saad J et al carried out a comparison of onabotulinumtoxin (Botox) and Incobotulinum toxin A (Xeomin) in the treatment of benign essential blepharospasm. No significant difference between Xeomin and Botox was detected in either subjective or objective measures for the treatment of Blepharospasm[25].

### Apraxia of Eyelid Opening

Apraxia is nonparalytic inability to raise the upper eyelid in the absence of discernable orbicularis muscle contraction or levator muscle injury. Many authors inappropriately apply this diagnosis to any patient with eyelid closure associated with minimal force of orbicularis contraction, or to those who respond poorly to botulinum toxin. The original description of this disease referred to patients with supranuclear injury in which activation of the levator muscle could not be achieved. Since that time, apraxic eyelids have been found to occur with several different disorders such as dystonic Parkinson syndrome, progressive supranuclear palsy, and isolated loss of levator muscle control. A fourth type, which can be referred to as *blepharospastic apraxia*, is seen in some patients with blepharospasm. Here, subclinical contractions of the pretarsal orbicularis muscle persist into the post-blink phase, suppressing levator muscle contraction. In such cases, injection of 5 units of botulinum toxin type A into the pretarsal orbicularis and Riolan's muscles along the upper eyelid margin may show beneficial results, whereas routine placement of toxin as for blepharospasm will not be effective. The frontalis sling procedure has also proven to be beneficial. Lopez Valdes et al & Kanazawa N. et al studies support the role of botox in eyelid apraxia [26].

**Eyelid myokymia** is an uncontrollable twitching of the orbicularis muscle, typically involving the lower eyelid. The twitching is triggered by stress, fatigue, caffeine or alcohol. In most cases it is benign and self-limiting. The mechanism is not well understood, but the affected muscle shows a slow, undulating fine movement in the most superficial muscle layers. Injection of 5 units of botulinum toxin type A into the superficial

orbicularis muscle temporarily relaxes the muscle until the condition resolves spontaneously.

### Strabismus

Botulinum toxin was first used in ophthalmology by Dr. Alan Scott to treat strabismus by weakening the contraction force of specific opposing muscles to straighten the eye. Injection usually requires the use of electromyographic-guided needle placement to ensure the toxin is delivered to the target muscle. For infantile esotropia it has been shown that two thirds of children receiving simultaneous bimedial rectus muscle toxin injection achieve some degree of stereopsis. One third of patients with comitant exotropia may also show improvement in their deviation. For larger-angle deviations, increasing the dose of toxin per injection may give better results, but this is associated with a higher incidence of complications such as ptosis. Botulinum toxin has also shown some benefit for traumatic paralytic strabismus, where it is used to minimize contracture of the opposing muscle until recovery. For patients who do not show recovery in 6 months, surgical correction is indicated.

Bunting et al carried out a retrospective review of patients undergoing inferior rectus botulinum toxin injection between 1982 and 2006 for vertical strabismus due to orbital pathology. A beneficial effect with inferior rectus botulinum toxin was obtained in 9/13 (69%) patients[27].

Dawson EL et al studied the Diagnostic use of botulinum toxin in patients with Duane syndrome. Duane syndrome is a difficult condition to treat. Botulinum toxin may be used to assess the likelihood of reducing the abnormal head posture and reducing the diplopia by increasing the field of binocular single vision. If results are favorable then surgery may be offered. Transient complications were ptosis in 11 patients and induced vertical deviation in 10 [28].

Studies show the role of botulinum toxin in decompensated strabismus. In small angle strabismus, botulinum toxin is reported as particularly useful in cases of acquired and acute-onset esotropia in aiding maintenance of binocular vision. It is useful for additional management of surgically under- or over-corrected esotropia, particularly for those with potential for binocular vision. Lesser effect is reported in primary exotropia versus primary esotropia. It is the management of choice for consecutive exotropia, particularly when patients have had previous multiple surgery and where there is a risk for postoperative diplopia. Botulinum toxin has a specific role in decompensated heterophoria, allowing the visual axes a chance to 'lock on' and subsequently maintain binocular vision. Successful outcomes are reported after 1-2 injections only but the results are best in cases of heterophoria

with little near-distance angle disparity. The main reported complications are those of ptosis, induced vertical deviation and subconjunctival haemorrhage. The higher the dose, the greater the risk of complications [29]. Diplopia following orbital decompression is a common complication in Graves' ophthalmopathy. Strabismus surgery is often required to treat the persistent diplopia. The author presents a successful treatment with botulinum toxin A injection in a case of diplopia following orbital decompression. Treatment with botulinum toxin A in the management of new-onset diplopia following orbital decompression has been suggested in a case that is not amenable to prism treatment and may eliminate strabismus surgery in some cases[30].

Patients with acute traumatic partial third-nerve palsy treated by injection of botulinum toxin A in the lateral rectus muscle showed marked recovery when injection was performed within 2 months of the onset of palsy. Botulinum toxin injection into the lateral rectus muscle may provide temporary relief of symptoms in some patients and seems to be a useful treatment option in cases of acute traumatic third nerve palsy in the short-term [31].

#### **Facial nerve palsy with aberrant regeneration**

Gustatory epiphora, often called *crocodile tears*, is a rare but most troublesome and embarrassing condition, characterised by excessive lacrimation while eating or smelling food. This occurs after Bell's palsy or stroke resulting into proximal facial nerve injury with aberrant regeneration of secretomotor fibers, originally destined for the salivary glands abnormally innervate the lacrimal gland. Intra or periglandular injection of Botulinum toxin is most effective treatment of gustatory epiphora[32]. Ptosis and superior rectus underaction are commonly reported side effects [33].

Freye's syndrome also called auriculo-temporal syndrome is characterized by ipsilateral excessive facial sweating while eating. The condition is due to aberrant innervations of the sweat glands by the parasympathetic salivary gland fibres after parotid gland surgery.

Botulinum injection also indicated in Lacrimal Hypersecretion Syndromes eg.primary idiopathic lacrimal hypersecretion or in secondary Lacrimal hypersecretion due to ocular surface irritation, such as with trichiasis and eyelid malpositions, corneal exposure, or blepharitis. Intraglandular injection of 2.5–5 units of botulinum toxin type A into the palpebral lobe of the lacrimal gland results in a clinically significant reduction in functional epiphora. Relief of epiphora lasts 3–4 months. Nava-Casteneda A et al studied the duration of effect of botulinum toxin in the treatment of crocodile tears. The effect of 2.5 units of Botax-A injected into the lacrimal gland lasted 6 months[32].

#### **Eyelid Retraction**

Upper eyelid retraction associated with thyroid eye disease may result in corneal exposure and, in some cases, corneal ulceration. Surgical recession gives excellent results in 90%–95% of patients, but is not usually recommended until the ophthalmopathy is stable. The transcutaneous or transconjunctival injection of Botulinum toxin type A (5–10 units) into the levator muscle can provide significant improvement in eyelid retraction. A drop in eyelid position of 2–4 mm is typical and results last for 12–14 weeks. Overcorrection can result in visually significant ptosis and diplopia from weakening of the superior rectus muscle [34].

#### **Spastic Entropion**

Spastic entropion is seen with horizontal lid laxity where overriding of preseptal orbicularis muscle over pretarsal orbicularis muscle occurs[34]. Occasionally after ocular surgery in patients with pre-existing lid laxity, ocular irritation can cause orbicularis muscle spasm resulting in entropion. Relief can be achieved by weakening the pretarsal orbicularis muscle with 5 units of botulinum toxin type A, eliminating the entropion for up to 3–4 months[35].

#### **Cornea Protection in Facial Paralysis**

Chemo-tarsorrhaphy is intramuscular injection of Botulinum toxin in levator muscle for inducing, temporary ptosis for corneal protection in case of exposure keratopathy in facial palsy and corneal ulcer.

#### **Aesthetic Uses**

The utility of botulinum toxin in facial rejuvenation has grown dramatically in recent years. Initially treatment was for dynamic glabellar folds treated with 20–40 units of botulinum toxin type A injection into the corrugator muscle in a V-shaped pattern to include both the transverse and oblique heads between the eyebrows. The aesthetic use of this drug has now expanded to off-label applications to many other areas of the face, including “crows feet” (lateral periocular rhytids), transverse brow and forehead furrows, “smoker's lines” (perioral rhytids), “marionette lines” (mesolabial folds), and platysmal bands. Botulinum toxin is also useful in creating a “chemical brow lift” by targeting the brow depressors (*depressor supercilii* medially, and tail of the *orbicularis* laterally). Treatment strategies for aesthetic uses vary widely, but it is important to approach each patient judiciously. While side effects are temporary they can result in significant morbidity and patient dissatisfaction.

## REFERENCES

1. Scott AB. Botulinum toxin injection into extraocular muscles as an alternative to strabismus surgery. *Ophthalmology* 1980;87:1044-1049.
2. Clark RP, Berris CE. Botulinum toxin (a treatment for facial asymmetry caused by facial nerve paralysis) *Plast Reconstr Surg* 1989; 84: 353-5.
3. Carruthers J, Carruthers A. Botulinum toxin (botox) chemodenervation for facial rejuvenation. *Facial Plast Surg Clin North Am* 2001; 9: 197-204 vii
4. Carruthers J, Carruthers A. Botox use in mid and lower face and neck, *Semin Cutan Med Surg* 2001;20: 85-92.
5. Charles PD. Botulinum neurotoxin serotype A: a clinical update on noncosmetic uses. *Am J Health Syst Pharm* 2004; 61 (22 Suppl 6): S11-S23.
6. Zalvan C, Bentsainov B, Gonzalez Yanes O, Biltzer A. Noncosmetic uses of Botulinum toxin. *Dermatol Clin* 2004; 22:187-195.
7. Akoi KR. Pharmacology and immunology of Botulinum neurotoxins. *Int Ophthalmol Clin* 2005; 45-25-37.
8. Melling J, Hambleton P, Shone CC. *Clostridium botulinum* toxins: nature and preparation for clinical use. *Eye (Lond)* 1988; 2 (Pt1): 16-23.
9. L. Bing, N.P. Peet, M.M. Butler, J.C. Burnett, D.T. Moir & T.L. Bowlin, 2011, "Small Molecule Inhibitors as Countermeasures for Botulinum Neurotoxin Intoxication," *Molecules*, 16:202-220, DOI 10.3390/molecules16010202
10. Akoi KR, Guyer B. Botulinum toxin type A and other botulinum toxin serotypes: a comparative review of biochemical and pharmacological actions. *Eur J Neurol* 2001; 8 (suppl 5): 21-29.
11. Foran PG, Mohammed N, Lisk GO et al. Evaluation of the therapeutic usefulness of botulinum neurotoxin B, C1, E and F compared with the long lasting type A. Basis for distinct durations of inhibition of exocytosis in central neurons. *J Biol Chem* 2003; 278: 1363-1371.
12. Allergan (2005) Botox® COSMETIC (botulinum toxin type A) purified neurotoxin complex <http://www.botoxcosmetic.com/resources/pi.aspx>. Cited 11 April 2007.s
13. Naik MN, Soparkar CN, Murthy R, Honavar SG. Botulinum toxin in Ophthalmic plastic surgery. *Indian J Ophthalmol* 2005; 53: 279-88.
14. Quinn N, Hallett M. Dose standardization of botulinum toxin. *Lancet* 1989; 1: 964.
15. Odergren T, Hjaltason H, Kaakkola S, Solder S, Hanko J, Fehling C et al. A double, randomized, parallel group study to investigate the dose equivalence of Dysport and Botox in the treatment of cervical dystonia. *J Neurol Neurosurgery Psychiatry* 1998;64 :6-12.
16. Lipham WJ. What is botulinum toxin and how does it work? In Lipham WJ (Ed): *Cosmetic and Clinical Applications of Botox and Dermal Fillers*. Slack incorporated, Thorofare NJ 2004; 6-9.
17. Matarasso SL, Matarasso A. Treatment guidelines for botulinum toxin type A for the particular region and a report on partial upper lip ptosis following injections to the lateral canthal rhytids. *Plast Reconstr Surg* 2001;108: 208-14.
18. Goldman MP. Festoon formation after infraorbital botulinum A toxin: a case report. *Dermatol Surg* 2003; 29: 560-1.
19. Jankovic J, Brin MF. Botulinum toxin: Historical perspective and potential new indications. *Muscle Nerve Suppl.* 1997;20:129-45
20. Schantz EJ, Johnson EA. Preparation and characterization of botulinum toxin type A for human treatment. In: Jankovic J, Hallet M, editors. *Therapy with Botulinum Toxin*. Vol. 109. New York, NY: Marcel Dekker; 1994. pp. 10-24.
21. Ranoux D, Gury C, Fondarai J, Mas JL, Zuber M. Therapy with Botulinum Toxin. *J Neurol Neurosurg Psychiatry.* 2002;72:459-62.
22. Botulinum toxin therapy in congenital blepharospasm, *Case Rep Ophthalmol.* 2014 Sep-Dec; 5(3): 435-438.
23. Kollewe et al, Blepharospasm: long-term treatment with either Botox, Xeomin or Dysport. *J. Neural Transm.* 2015 Mar;122(3):427-31. doi: 10.1007/s00702-014-1278-z. Epub 2014 Jul 25.
24. Ramirez-Casteneda et al, Long-term efficacy, safety, and side effect profile of botulinum toxin in dystonia: a 20-year follow-up. *Toxicon*, 2014 Nov;90:344-8. doi: 10.1016/j.toxicon.2014.07.009. Epub 2014 Aug 15.
25. A direct comparison of onabotulinumtoxinA (Botox) and IncobotulinumtoxinA (Xeomin) in the treatment of benign essential blepharospasm: a split-face technique. *J. Neuroophthalm.* 2014 Sep;34(3):233-6. doi: 10.1097/WNO.0000000000000110
26. Lopez Valdes et al & Kanazawa N et al, Botulinum toxin A injections improve apraxia of eyelid opening without overt blepharospasm associated with neurodegenerative diseases. *Mov. Disord.* 2008 Apr 15; 23(5):773; author reply 773. doi: 10.1002/mds.21816
27. Bunting et al, Role of inferior rectus botulinum toxin injection in vertical strabismus resulting from orbital pathology. *Strabismus*, 2013 Sep;21(3):165-8. doi: 10.3109/09273972.2013.811602
28. Dawson EL et al, Diagnostic use of botulinum toxin in patients with Duane syndrome. *Strabismus*, 2010 Mar;18(1):21-3. doi: 10.3109/09273970903580199
29. Ripley L, Rowe FJ, Use of botulinum toxin in small-angle heterotropia and decompensating heterophoria: a review of the literature. *Strabismus*. 2007 Jul-Sep;15(3):165-71
30. Wutthiphon S. Role of botulinum toxin A in diplopia following orbital decompression. *Strabismus*. 2008 Jul-Sep;16(3):112-5. doi: 10.1080/09273970802292552
32. Talebnejad MR et al. The role of Botulinum toxin in management of acute traumatic third-nerve palsy. *J AAPOS.* 2008 Oct;12(5):510-3. doi: 10.1016/j.jaaapos.2008.03.009. Epub 2008 Jun 16
34. Nava-Castaneda A et al. Duration of botulinum toxin effect in the treatment of crocodile tears. *Ophthalm Plast Reconstr Surg.* 2006 Nov-Dec;22(6):453-6
35. Keegan DJ, Geerling G, Lee JP, Blake G, Collin JR, Plant GT. Botulinum toxin treatment for hyperlacrimation secondary to aberrant regenerated seventh nerve palsy or salivary gland transplantation. *Br J Ophthalmol* 2002;86:43-6.
36. Uddin JM, Davies PD. Treatment of upper eyelid retraction associated with thyroid eye diseases with subconjunctival botulinum toxin injection. *Ophthalmology* 2002; 109: 1183-7.
37. Clarke JR, Spalton DJ. Treatment of senile entropion with botulinum toxin. *Br J Ophthalmol* 1988; 72:361-362.