

Optical coherence tomography based analysis of changes in macula in diabetes after phacoemulsification surgery

Rajni Sethia¹, Parin Mehta^{2,*}, Vivan Desai³, Aakash Patel⁴, Shail Shah⁵

¹Associate Professor, ²Resident, ^{3,4}Consultant, ⁵Resident, Dept. of Ophthalmology, ^{1,2,5}S.B.K.S M.I.R.C, Sumandeep Vidyapeeth Deemed to be University, ³Diva Eye Hospital, Ahmedabad, Gujarat, ⁴Aakash Eye Hospital, Ahmedabad, Gujarat, India

***Corresponding Author: Parin Mehta**

Email: parinmehta23@gmail.com.com

Abstract

Purpose: To assess quantitative changes of the macula after cataract surgery using optical coherence tomography (OCT) in diabetic eyes and to estimate the incidence of development of macular edema (ME) in type II diabetic eyes.

Materials and Methods: In this prospective observational case control study, 100 eyes out of which 50 are of type II diabetic patients and 50 are non-diabetic patients who underwent phacoemulsification surgery with acrylic foldable IOL lens implantation were evaluated at post op day 1, day 7, 1 month and 3 months post operatively. Macular thickness as described in early treatment of diabetic retinopathy study (ETDRS) with OCT was evaluated in 9 zones. 4 patients developed DME at 1 month after surgery and were withdrawn from further analysis.

Result: The mean central foveal thickness of the diabetic group preoperatively was 231.06±38.785µ. The increase in central foveal thickness was statistically significant at 1 month postoperatively (p=0.004). The mean perifoveal thickness changes in the inferior and temporal quadrants was also statistically significant at 1 month postoperatively (p=0.002). However, the overall change in macular thickness was found to be insignificant at 3 months postoperatively. The incidence of diabetic macular edema was found to be 8%.

Conclusion: We found that after uncomplicated phacoemulsification, changes in macular thickness as measured by OCT was without any significance.

Keywords: Cataract, Diabetes, Macular edema, OCT.

Introduction

Irvine-Gass syndrome or pseudophakic CME is Cystoid Macular Edema (CME) associated with cataract surgery and its cause is thought to be directly related to the surgery.¹

Pseudophakic CME is more commonly seen in patients with diabetes and with complicated cataract surgery.² Diabetic macular edema (DME) though being the most common ocular manifestation causing visual deterioration in diabetic patients post cataract surgery, has also been reported in non-diabetic eyes post uncomplicated cataract surgery.^{3,4}

The pathogenesis and course of DME requires a complex approach. Most of the earlier studies haven't used optical coherence tomography (OCT) technology in their research. The role of OCT is in providing both qualitative and quantitative data to evaluate the association of CME and cataract surgery in patients with diabetic retinopathy.

In our study we analysed the OCT parameters of macular thickness after uncomplicated phacoemulsification surgery in diabetics and non-diabetics.

Materials and Methods

This was a prospective observational case control study conducted in the department of Ophthalmology of a tertiary care hospital. A total of 100 eyes underwent uncomplicated phacoemulsification with acrylic hydrophilic foldable IOL implantation under one surgical platform by single surgeon with single postoperative protocol were included in the study. 100 eyes were divided into 2 groups. Group A included 50 eyes of type II diabetic patients & group B included 50 eyes of non-diabetic patients which acted as

control group. Out of the 50 diabetic patients, 4 patients developed CME 1 month after cataract surgery and they were excluded from the analysis after 1 month for the same.

All the participants gave informed consent before the study. The study also adhered to the tenets of Declaration of Helsinki and was reviewed and approved by the institutional Ethics Committee.

All patients with senile cataract, known cases of type II diabetes with mild to moderate NPDR, without preexisting macular edema (on OCT macular thickness of <280 microns), with no history of previous laser and uneventful cataract surgery were included in our study.

Exclusion criteria were no previous ocular surgery, no evidence of previous uveitis, glaucoma or any other ocular pathology that might affect visual acuity, no evidence of current or preexisting retinal/macular pathology except mild to moderate NPDR, proliferative diabetic retinopathy and use of topical medication or systemic therapy with known interference on retinal thickness.

A complete ophthalmic evaluation including visual acuity, tonometry and slit lamp examination including biomicroscopy was done. The cataract grading was based on the LOCS III classification. Dilated posterior segment evaluation was done to grade diabetic retinopathy. The above examination was done preoperatively and postoperatively on day 1, day 7, 1 month and 3 months.

Phacoemulsification for cataract surgery was performed by a single experienced surgeon using catarhex easy, Oertli. A clear corneal incision was made and a continuous curvilinear capsulorhexis was performed. The nucleus was divided and phacoemulsification and aspiration were performed and after cortical removal, an acrylic hydrophilic

foldable intraocular lens was inserted in the capsular bag. The average phaco power was between 50%-60% and absolute phaco time was 15 ± 7 seconds.

Optical Coherence Tomography (Topcon 3D OCT 1000) was done preoperatively & postoperatively on day 1, day 7, 1 month and 3 months to measure foveal thickness by ETDRS grid. Pupils were dilated for OCT examination in all cases with 0.5% tropicamide with 2.5% phenylephrine. The retinal thickness values in the fovea, parafoveal and perifoveal areas were measured using 3D macular thickness map analysis program. Parafoveal and perifoveal areas were also measured in superior, inferior, nasal and temporal quadrants. Parafovea is defined as the area surrounding the fovea upto 3 mm. While, perifovea is the region that circumscribes the parafovea upto 2mm diameter.

Statistical Analysis

In this study the categorical variables were analysed with frequencies and percentages. For continuous variables, mean and standard deviation were calculated and the student's unpaired 't' test was used to for comparison between two group whereas repeated measured ANOVA was applied for comparison between more than two groups. When ANOVA was applied, Bonferroni Post Hoc multiple comparisons have been done to know the one to one relation. Differences were considered statistically significant when the p value was less than 0.05.

Results

100 eyes of patients were included in the study out of which 50 were type II diabetics and 50 were non diabetics. There were a total of 43 females and 57 males. The mean central foveal thickness of the diabetic group preoperatively was $231.06\pm 38.785\mu$. Postoperatively the mean central foveal thickness was $232.36\pm 46.224\mu$, $235.75\pm 41.641\mu$,

$250.89\pm 57.862\mu$ and $236.61\pm 54.349\mu$ on post op day 1, day 7, 1 month and 3 months respectively. (Table 1)

For the non-diabetic group the mean central foveal thickness preop was $232.56\pm 39.484\mu$. Postoperative mean central foveal thickness was $236.79\pm 38.327\mu$, $233.56\pm 36.896\mu$, $245.35\pm 49.170\mu$, $233.30\pm 32.657\mu$ on post op day 1, day 7, 1 month and 3 months respectively. (Table 1)

Based on post hoc analysis it was found that central foveal thickness shows statistically significant increase at POD 1 month in both diabetics and non-diabetics compared to baseline ($p=0.004$) which then returns to normal value at 3 months post op. ($p<0.05$). The difference between macular thickness between diabetics and non-diabetics was statistically non-significant.

Table 1 shows mean macular thickness based on OCT for fovea, parafovea and perifoveal thickness in superior, inferior, temporal and nasal quadrants. There was no statistically significant difference in overall macular thickness when compared pre-operative and post-operative values. ($p>0.05$)

4 patients developed Diabetic macular edema at 1 month postoperatively with central foveal thickness at $387\pm 56\mu$. These patients were not included in the analysis at 1 month and 3 months. The incidence of DME was found to be 8%. (Table 2)

Fig. 2 shows comparison of parafoveal thickness values of diabetics and non-diabetics. The mean thickness for diabetics was higher in each quadrant compared to non-diabetics however the difference was statistically non-significant ($p>0.05$).

Fig. 3 shows mean perifoveal thickness comparison of diabetics and non-diabetics. The inferior and temporal quadrants in diabetics showed increase in thickness on POD 1 month ($p=0.02$) which then returned to near baseline at POD 3 months. This change was statistically significant.

Table 1: Macular thickness for all 9 quadrants in both groups

Group	Day	Mean Fovea	Parafovea				Perifovea			
			Superior	Nasal	Inferior	Temporal	Superior	Nasal	Inferior	Temporal
Diabetes N=46	Pre Op	231.06	284.17	282.03	282.92	289.72	255.83	268.50	267.08	244.11
	POD 1 Day	232.36	282.25	284.44	282.11	286.19	258.75	270.97	268.14	245.33
	POD 7 Days	235.75	288.28	286.31	289.83	282.36	260.89	272.72	262.44	252.14
	POD 1 Month	250.89	289.42	289.08	293.94	283.81	267.33	283.36	288.42	280.64
	POD 3 months	236.61	288.81	285.61	288.19	286.69	257.69	272.72	268.83	244.39
Non diabetic N=50	Pre Op	232.56	275.28	276.02	274.98	267.95	244.58	254.16	241.07	233.56
	POD 1 Day	236.79	283.60	284.02	281.00	272.37	241.05	266.14	248.93	235.72
	POD 7 Days	233.56	284.70	285.81	282.23	271.07	245.63	268.60	251.14	236.19
	POD 1 Month	245.35	289.23	293.33	286.63	280.12	250.49	265.33	254.91	242.19
	POD 3 months	233.30	282.49	286.47	281.12	271.23	242.28	264.93	248.33	233.86

Table 2: Mean preop and post op values of central macular thickness of diabetic patients

Fovea	Without CME N=46	With CME (at 1 month) N=4
Pre op	231.06	232.32
POD Day 1	232.36	243.56
POD Day 7	235.75	245.12
POD 1 Months	250.89	342.19
POD 3 Months	236.61	367.71

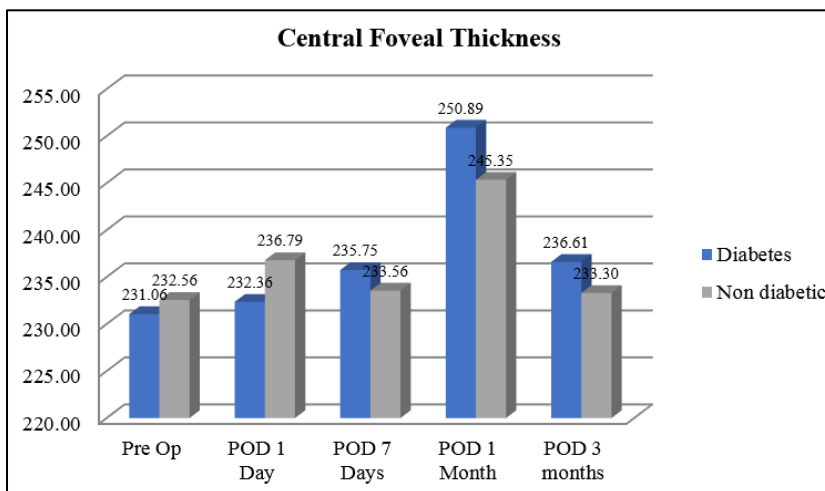


Fig. 1: Comparison of central foveal thickness in both groups

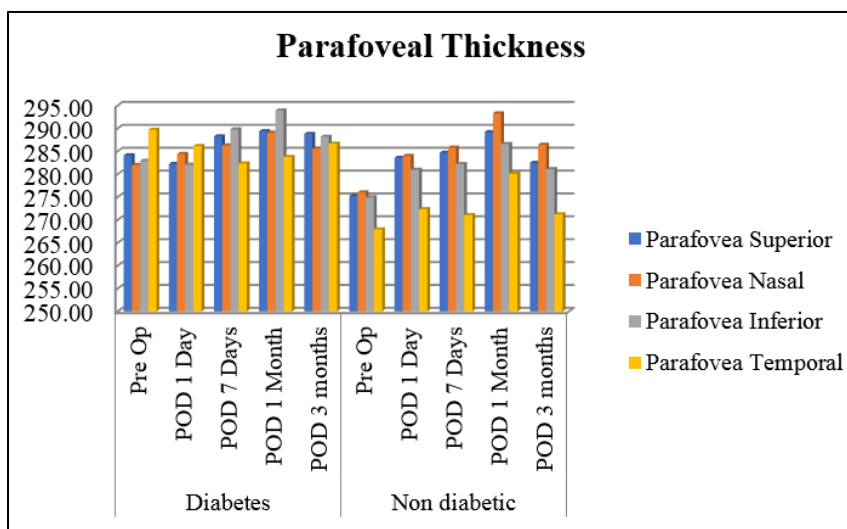


Fig. 2: Comparison of parafoveal thickness in each quadrant

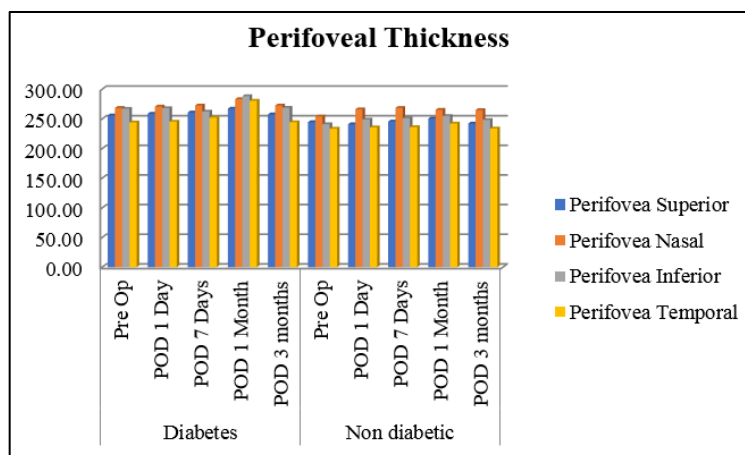


Fig. 3: Comparison of perifoveal thickness in each quadrant

Discussion

This prospective, observational study demonstrates that in diabetic eyes, macular thickness of the central subfield as well as the inner and outer areas increase statistically in post op month 1, however the mean increase shows no clinical significance. These values eventually return to baseline at the end of post op month 3 indicating short-term nature of CME.

Two types of surgeries has revolutionized cataract surgery in the last decade. Phacoemulsification has lower complication rate and also more safety level and predictability in surgery.^{5,6}

The aim of these advances & surgical proficiency are to gain better post-operative results in the form of comfort, visual acuity, faster recovery and avoiding spectacle wear. Certain complications in surgery such as vitreous loss, iris trauma, posterior capsular rupture, post-operative astigmatism, Irvine gass syndrome, wound leak, endophthalmitis, etc. have shown considerable reduction.

CME is one of the complications of cataract surgery with incidence of 1-2%.⁷ There is accumulation of fluid in the macular area, and there is thickening of retina like a sponge. This condition can manifest at around 4 weeks post-surgery or sometimes even earlier.

Other conditions causing macular edema apart from cataract surgery are conditions such as age-related macular degeneration (ARMD), uveitis, epiretinal membrane, vitreomacular traction, diabetes, retinal vein occlusion and drug induced CME.

Glycosylated end products are responsible for first line changes in the retinal endothelial cells. Factors such as vascular endothelial growth factor (VEGF) and other radicals cause more damage to each layer of retina causing accumulation of fluid and neovascularisation.⁷

Optical Coherence Tomography is a imaging technology for retinal disease diagnosis that captures micron resolution three-dimensional images. The principle of optical reflectometry involves the measurement of light back scattering through transparent or semi-transparent media such as retina and choroid. Light from a broadband light source into two arms, a reference arm and a sample arm that

is reflected back from structures at various depths within the posterior pole of the eye.

The risk of macular edema after cataract surgery in patients with mild retinopathy is as high as 6 times and as high as 12 times in patients with severe retinopathy.⁸ Several studies indicate that development of macular edema or its progression in diabetics is related to cataract surgery.⁹⁻¹¹ If the patient already has a pre-existing DME involving fovea then there is a predominance of CME in these patients after surgery. However, other reports indicate that pre-existing DME is not needed for ME to occur after surgery.¹²

Many earlier studies, however, used other methods to report rates of CME progression; for example, the proportion of eyes manifesting angiographic CME was 9% after cataract surgery using fluorescein angiography in people without diabetes.¹³ Romero-Aroca et al¹⁴ reported that 6.06% of 132 eyes of diabetic patients developed DME on evaluation by fluorescein angiography and OCT following uneventful phacoemulsification. In a single-center study of 50 eyes, Kim et al¹² reported an incidence rate of 22% (95% CI, 13%-35%) for DME exacerbation (defined as $\geq 30\%$ increase in OCT centre-point thickness compared with presurgical OCT) 1 month after cataract surgery. In the present study, CME has been noticed using OCT in 4 out of 50 (8%) eyes of diabetic patients after surgery. All these 4 patients had drop in mean visual acuity and had undergone appropriate intervention.

There is no consensus on OCT parameters for identifying the presence of CME post cataract surgery. The inconsistency in reported progression rates of CME post cataract surgery in diabetic persons may be explained by the lack of a unified definition of clinically important progression of CME and/or different population settings or pathologic parameters between studies.

Von Jagow et al. reported that the degree of macular thickening is not related to the surgical and biometric parameters such as phacoemulsification time and energy and axial length. These parameters were not considered in our study. However, an average of 50–60% phacoemulsification energy was used in all of the cases.¹⁵

The mean age of the patients with increased macular thickness in our analysis was higher than those without any change in macular thickness. This is consistent with Desai P et al advocating that aging may predispose the development of CME.¹⁶ Furthermore, in their study the CMT of those patients without CME increased significantly on OCT on day 1 post surgery, compared to the preoperative values. Increase of the CMT in these patients may be because of light exposure during surgery.

The results in our study signify that after uncomplicated cataract surgery, macular thickness in diabetics is not significantly affected. However, higher sensitivity of OCT machine can pick up changes which are non-significantly higher in diabetics compared to non-diabetics.

Sourdille found significant macular thickening with decreased visual acuity in 11 eyes out of 41 post uneventful cataract extraction.¹⁷ Cheng B et al performed OCT examinations 1 week after uncomplicated cataract surgery on 80 eyes, and although the average preoperative foveal thickness increased, the difference proved to be non-significant ($P < 0.05$).¹⁸

Follow-up time of only three months may be another limitation of study. Though studies suggested that more than 60% CME occur at 1-month follow-up, CME may occur at 6 months or even 1 year after surgery. Longer follow-up in the future is needed to obtain a more accurate incidence of ME in diabetic eyes after cataract surgery.

Conclusion

In conclusion, OCT provides non invasive and quantitative measurements of macular thickness and allows us to quantitatively assess progression of postsurgical CME. Although, uncomplicated cataract surgery does not significantly affect macular thickness, the surgeons should vigilantly monitor diabetic patients after cataract surgery. Using OCT we can get a baseline measurement and then subsequently assess the risk of macular edema in such patients. Our study was somewhat limited due to a small sample size; however, the results are comparable to previous studies.

Financial Support: Sumandeep Vidyapeeth Deemed to be University.

Conflict of Interest: None.

References

1. Benitah NR, Arroyo JG. Pseudophakic cystoid macular edema. *Int Ophthalmol Clin* 2010;50(1):139-53.
2. Nelson ML, Martidis A. Managing cystoid macular edema after cataract surgery. *Curr Opin Ophthalmol* 2003;14:39-43.
3. Stark WJ Jr, Maumenee AE, Fagadau W. Cystoid macular edema in pseudophakia. *Surv Ophthalmol* 1984;28Suppl:442-451.
4. Ursell PG, Spalton DJ, Whitcup SM, Nussenblatt RB. Cystoid macular edema after phacoemulsification: relationship to blood-aqueous barrier damage and visual acuity. *J Cataract Refract Surg* 1999;25:1492-1497.
5. Schimel AM, Fisher YL, Flynn HW., Jr Optical coherence tomography in the diagnosis and management of diabetic

- macular edema: time-domain versus spectral-domain. *Ophthalmic Surg Lasers Imaging* 2011;42(Suppl. S41-55).
6. Baskin DE. Optical coherence tomography in diabetic macular edema. *Curr Opin Ophthalmol* 2010;21(3):172-177.
7. Henderson BA, Kim JY, Ament CS, Ferrufino-Ponce ZK, Grabowska A, Cremers SL. Clinical pseudophakic cystoid macular edema. Risk factors for development and duration after treatment. *J Cataract Refract Surg* 2007;33(9):1550-1558.
8. International Journal of Advances in Medicine Lathika VK. *Int J Adv Med* 2017;4(2):546-550.
9. Pollack A, Dotan S, Oliver M. Course of diabetic retinopathy following cataract surgery. *Br J Ophthalmol* 1991;75(1):2-8.
10. Jaffe GJ, Burton TC, Kuhn E, Prescott A, Hartz A. Progression of nonproliferative diabetic retinopathy and visual outcome after extracapsular cataract extraction and intraocular lens implantation. *Am J Ophthalmol* 1992;114(4):448-456.
11. Benson WE, Brown GC, Tasman W, McNamara JA, Vander JF. Extracapsular cataract extraction with placement of a posterior chamber lens in patients with diabetic retinopathy. *Ophthalmol* 1993;100(5):730-738.
12. Kim SJ, Equi R, Bressler NM. Analysis of macular edema after cataract surgery in patients with diabetes using optical coherence tomography. *Ophthalmology*. 2007;114(5):881-889.
13. Menten J, Erakgu T, Afrashi F, Kerici G. Incidence of cystoid macular edema after uncomplicated phacoemulsification. *Ophthalmol* 2003;217(6):408-412.
14. Romero-Aroca P, Fernández-Ballart J, Almena-Garcia M, Méndez-Marín I, Salvat-Serra M, Buil-Calvo JA. Nonproliferative diabetic retinopathy and macular edema progression after phacoemulsification: prospective study. *J Cataract Refract Surg* 2006;32(9):1438-1444.
15. von Jagow B, Ohrloff C, Kohnen T. Macular thickness after uneventful cataract surgery determined by optical coherence tomography. *Graefes Arch Clin Exp Ophthalmol* 2007;245:1765-1771.
16. Desai P, Minassian DC, Reidy A. National cataract surgery survey 1997-8: a report of the results of the clinical outcomes. *Br J Ophthalmol* 1999;83(12):1336-1340.
17. Sourdille P, Santiago PY. Optical coherence tomography of macular thickness after cataract surgery. *J Cataract Refract Surg* 1999;25(2): 256-261.
18. Cheng B, Liu Y, Liu X, Ge J, Ling Y, Zheng X. Macular image changes of optical coherence tomography after phacoemulsification. *Zhonghua Yan Ke Za Zhi* 2002;38(5):265-267.

How to cite this article: Sethia R, Mehta P, Desai V, Patel A, Shah S. Optical coherence tomography based analysis of changes in macula in diabetes after phacoemulsification surgery. *Indian J Clin Exp Ophthalmol* 2019;5(1):82-86.