

## Clinico-pathological study of orbital inflammatory diseases of infectious origin

Prasanna Jit Das<sup>1</sup>, Abhisek Mondal<sup>2,\*</sup>

<sup>1</sup>Assistant Professor, <sup>2</sup>Registrar, Dept. of Ophthalmology, Silchar Medical College, Silchar, Assam, India

\*Corresponding Author: Abhisek Mondal

Email: phantompain007@gmail.com

### Abstract

**Introduction:** Infection in the orbit and the periorbital tissues are particularly important subsets of inflammatory diseases not only because of frequency of presentation but also because of life threatening conditions which demand prompt, specific and therapeutic management. Of the orbital inflammation with infections most common aetiological factors encountered, are due to bacteria.

**Materials and Methods:** All patients with orbital signs and symptoms of inflammatory diseases of infectious origin were selected. Progression, symptoms, history of associated symptoms such as headache, fever, allergy etc. asked for. History of trauma, immunization and systemic illness, endocrinological disorders, infections of any systems and any dermatological disorders were taken into account. Local examination, ENT examination, laboratory and radiological investigations were done in all cases.

**Results:** Incidence of orbital infection is 0.34%. Male preponderance and maximum number of patients were adult. The maximum aetiological factor of orbital infection being due to infections of the ocular adnexae, sinusitis, dacryocystitis, post-surgical, and trauma. Raised IOP in 24%, proptosis in 34%, restricted ocular motility in 42%, mechanical ptosis in 70%, NLD block in 18%, Corneal oedema or opacity in 14% and inflammation of ocular adnexae in almost all cases. In majority of the cases the organism responsible is *Pseudomonas aeruginosa*, then *staphylococcus aureus*.

**Conclusion:** Orbital infection is sight threatening and the pathognomic features and virulence of the causative organism is unpredictable. Early presentation appropriate diagnosis and judicious protocol if followed at an early stage would halt the morbidity and fatality.

**Keywords:** Clinicopathology, Infectious origin, Orbital cellulitis, Orbital inflammation, Preseptal cellulitis.

### Introduction

The orbit is a pear shaped bony cavity, containing globe, extra ocular muscles, fascia nerves, fat, blood vessels and the stalk of the pear is the apex or the optic canal tapering posteriorly.

The orbit lie in the anterior cranial fossa, between them in the nasal cavity and ethmoidal air sinus and below each the maxillary sinus and, laterally middle cranial fossa, and temporal fossa.

Infection in the orbit and the periorbital tissues are particularly important subsets of inflammatory diseases not only because of frequency of presentation but also because of life threatening conditions which demand prompt, specific and therapeutic management.

Of the orbital inflammation with infections most common aetiological factors encountered, are due to bacteria. The next common is fungal infection. Relatively rare orbital infections are those caused by parasites.

The diagnosis of orbital inflammatory disease of infectious origin is from history, clinical examination, few laboratory investigations and necessary radiological investigations.

### Materials and Methods

Aim of this study was to find out incidence of orbital infections and mode of clinical presentation, probable aetiological factors and the outcome.

**Selection of Patients:** All the patients attending the out-patient department presenting with orbital signs and symptoms of orbital inflammatory diseases of infectious origin were selected. Written consent about being a part of the study was obtained from them. History, visual acuity abnormalities (both for near and distant), deviation of the

eye, diplopia, discharge from the eye, drooping of the eyelid, protrusion of eye ball, adnexal swelling were noted down.

Progression, chronology of symptoms appearance, history of associated symptoms such as headache, fever, nausea, vomiting, allergy etc. asked for.

History of present and past trauma, history of immunization and systemic illness were taken into account.

Endocrinological disorders like diabetes mellitus, thyroid disorders were given special attention.

Also history of present and past local infections of any systems and any dermatological disorders and infections were asked for.

On inspection following points were noted- Head posture, Laterality, Proptosis, Any change in colour of the skin of eyelids and adjacent structure, Any signs of trauma, haemorrhage, pus drainage.

The following points were noted on palpation Swelling, size, shape, consistency; Reducibility; Compressibility & fluctuation; Pulsation locally; Translucency; Regional lymph nodes. Orbit was auscultated by placing the bell of the stethoscope over the closed eyelids.

Slit lamp biomicroscope was done to find out incidence of orbital infections pupillary size, shape, reaction direct and consensual and RAPD were noted.

Fundus examination was done by direct and indirect ophthalmoscope (90D, 78D, 20D) with dilatation of the pupil.

Ocular motility test was noted. Diplopia charting was done.

Intraocular pressure was recorded with Schiotz tonometer and digitally.

It was done with Proptosis was measured by Hertel Exophthalmometer and the result was recorded. ENT examination was done whenever required.

General and systemic examination were carried out.

Routine blood, urine and stool examinations were carried out.

Plain X-ray of the orbit, skull, and chest B-Scan Ultrasonography and CT scan of the brain /orbit: were done in selected cases.

## Results

During the study period 14500 cases attended the out - patient department and a few cases were referred from Casualty, ENT, Paediatric and Surgery department. The study included 30 cases of preseptal cellulitis and 20 cases were orbital cellulitis.

**Table 2: Age distribution of orbital infection**

Age in years	Total Orbital Infection		Preseptal Cellulitis		Orbital Cellulitis	
	No of Cases	%	No. of cases	%	No. of cases	%
0-9	9	18%	7	23.3%	2	10%
10-19	9	18%	7	23.3%	2	10%
20-29	5	10%	3	10%	2	10%
30-39	10	20%	6	20%	4	20%
40-49	6	12%	1	3.3%	5	25%
50-59	4	8%	3	10%	1	5%
60-69	7	14%	3	10%	4	20%
Total	50	100%	30	100%	20	100%

There was male preponderance of 60% and female of 40%, ratio of 3:2.

The maximum incidence of cases of orbital infections found to be of right side (66%) and the left sided incidence of 34%.

Pre septal cellulitis being right sided 66.66%, left sided 33.33% and the orbital cellulitis right sided involvement 65% and left sided 35%.

The commonest cause of orbital infection being due to infections of the ocular adnexae, followed by sinusitis, dacryocystitis, post-surgical, and trauma respectively. There are cases of orbital infections due to retinoblastoma and insect bite and also a single case of endogenous aetiology is noted. (Table 3)

**Table 3: Aetiology of orbital infection**

Aetiology	No. of cases	%
Dacryocystitis	9	18%
Sinusitis	10	20%
Post Operative	8	16%
Adnexal pathology	12	24%
Endogenous	1	2%
Retinoblastoma	2	4%
Insect bite	1	2%
Trauma	7	14%
Total	50	100%

In this study there are important clinical associations of temperature in 42%, poor nutrition in 14%, anaemia in 6%,

50 cases of orbital inflammatory diseases of infectious origin were recorded among all the patients that attended the Out-patient department. Incidence of orbital infection is 0.34%. The pre septal cellulitis cases were 30 (60%) and the orbital cellulitis cases were 20 (40%). The table is shown below (Table 1).

**Table 1: Incidence of orbital infection**

Total no of patients	14500	Incidence
Total orbital infections	50	0.34%
Preseptal cellulitis	30	60%
Orbital cellulitis	20	40%

In the present study there are 50 cases of different age groups as shown in the data below. The adult age group showing the maximum occurrence (Table 2).

Type 2 diabetes mellitus in 8%, malignancy in 4%, and tuberculosis and endogenous infection in 2% of total cases.

**Ocular Morbidity in Orbital Infection:** Raised IOP in 24%, proptosis in 34%, restricted ocular motility in 42%, mechanical ptosis in 70%, NLD block in 18%, Corneal oedema or opacity in 14% and inflammation of ocular adnexae in almost all cases (100%).

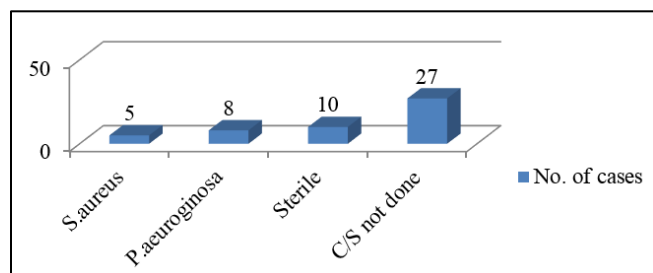
Visual acuity: Absent light perception in 24%, finger counting close to face in 6%, and Snellen's acuity <6/12-60 in 16% and 6/6 to 6/9 in 54% of cases. The pl-ve (70%) cases are during presentation. (Table 4)

**Table 4: Ocular morbidity in orbital infection**

Condition	No. of cases	%
Raised IOP	12	24%
Proptosis	17	34%
Ocular motility restriction	21	42%
Mechanical Ptosis	35	70%
NLD block	9	18%
Corneal edema/opacity	7	14%
Fundus not visible	14	28%
Inflamed ocular adnexa	50	100%

**Organisms Involved in Orbital Infections:** Culture sensitivity is done in only few cases as there are difficulty in obtaining the material, prior administration of antibiotic topically or systemically and late presentation of cases.

Culture was done in 23 cases, in majority of the cases the organism responsible is *Pseudomonas aeruginosa*, then *Staphylococcus aureus* and 10 cases are sterile in culture sensitivity report. (Fig. 1)



**Fig. 1: Organisms involved**

**Treatment:** Treatment option was conservative in most of the cases with broad spectrum antibiotics. In 23 cases (46%) surgical interventions was done although not immediately and they are as follows - in 9 cases dacryocystorhinostomy, repair of ocular adnexa and anterior segment in 2 cases and evisceration in 12 cases.

## Discussion

The present study of orbital inflammatory diseases of infectious origin is a prospective randomized study.

Richard Dallow et al<sup>1</sup> has found 5% cases of orbital cellulitis among the total cases of 2000 inflammatory disorders. Also in child hood orbital disorders Richard L. Dallow found inflammatory disorders to be of 37% and orbital cellulitis was the common prevalent inflammatory disorder.

In the present study the incidence of orbital infection is 0.34% of the total no of cases attended in our institution during the study period of a year and the incidence of pre septal cellulitis is 60% and the orbital cellulitis is 40%, among the total infectious disorder of the orbit.

**Incidence of Age:** Bergin<sup>2</sup> et al studied 49 cases of orbital infections from the age range of 4-71 years and the mean age was 31 years.

In the present study the age range is from 2 years to 69 years and mean age is 30.58 years, pre septal cellulitis is 26.75 years and orbital cellulitis 36.70 years, and 18 patients were of paediatric age group.

**Sex Incidence:** Waters EC<sup>3</sup> et al studied 104 patients of orbital cellulitis where he found 68 (66%) patients were male and 36(34%) were female and Suneetha et al studied 13 cases of orbital abscess where 10 cases (76%) were male and 3 (24%) cases were female).

**Laterality:** Bergin J.D.<sup>2</sup> et al found 49 cases of orbital cellulitis 17 cases (35%) were of right sided and 30 cases (62%) were left sided and 2 cases (3%) had bilateral involvement.

**Clinical and aetiological discussion and outcome:** In the study of Bergin J.D.<sup>2</sup> et al in 49 cases of onset of symptoms varied from <7-14 days. Chemosis and eye lid swelling were present in all the patients and 45 patients had restricted ocular movement and eye was displaced infero laterally. 16

Patients had pyrexia and 23 patients had decrease visual acuity of 1 Snellen's line or more in the affected eye, increased leucocyte count in 33 patients. In X-rays sinus abnormalities in 61% and in CT scan in 6 patients abscess was detected in the orbit. Factors predisposed to orbital cellulitis in his cases were chronic sinusitis, infected chalazion, eyelid or ocular trauma, dental surgery etc. Culture and sensitivity in his cases were disappointing as the majority of cases presented after antibiotic treatment. Complication occurred in the patients were strabismus, afferent papillary defect, chronic draining sinus and scarred lids.

In the study of Suneetha N. Rao,<sup>4</sup> 13 cases of orbital abscess sources of orbital infection included PNS infection in 5 cases, odontogenic infection in 4 cases one each temporal fossa abscess, palatal abscess, furuncle of lids and nose, secondary to retrobulbar injection of steroid. CT finding in 13 cases showed abscess. Culture sensitivity showed *Staphylococcus aureus* (3), and 2 each *Pseudomonas aeruginosa*, *Proteus mirabilis*, *Acinobacter* and 1 each had *Beta Haemolytic streptococcus*, *Enterobacter* & *Citrobacter*. Final visual acuity was good in 6 cases and no light perception in 6 cases and other complications were intra cranial abscess (4) cavernous sinus thrombosis (20), restricted ocular motility (2).

Avery Weiss<sup>5</sup> et al studied bacterial periorbital and orbital cellulitis in child hood and found 137 cases of periorbital cellulitis and 21 children of orbital cellulitis. Orbital cellulitis was more frequent in children >5 years and frequently associated with Sinusitis (90%) with positive sinus X-rays. Bacteria isolated in Periorbital cellulitis were *Staphylococcus aureus* (15), *Streptococcus* (14), and 1 each of *Moraxella* species, *H.influenza* and *E.coli*.

In the present study of orbital infection the onset of symptoms varied from 5 days to 14 days. Chemosis and eye lid swelling i.e. inflammation are present in all the patients and 20 patients had restricted ocular movement, blocked NLD in 9 cases, mechanical ptosis in 35 cases, corneal oedema and opacity in 7 cases. 21 Patients had pyrexia and 23 patients had decrease visual acuity of Snellen's chart <6/12-6/60 in 8, FCCF in 3, PI-ve in 12 in the affected eye, increased leucocyte count in 35 patients. In X-rays sinus abnormalities in 8 patients and in CT scan 1 patient showed medial rectus abscess in the orbit. Factors associated with orbital infection in this study were poor nutrition in 7 cases, anaemia 3 cases, diabetes 4 case, malignancy 2 cases, tuberculosis and endogenous infection 1 in each case. The majority of cases predisposed to orbital cellulitis were adnexal pathology (12), sinusitis (10), dacryocystitis (9), and postoperative cataract extraction (8), trauma (7), retinoblastoma, insect bite and endogenous infection 1 in each case. Sensitivity has been done in 23 cases in this study & common organism cultured is *Pseudomonas aeruginosa* (8), *Staphylococcus aureus* (5), and sterile in 10 cases. Major complications occurred are loss of eye in 12 cases, scarring of the lid in 2 cases persistent epiphora in 1 case.

In the present study a single case of pre septal cellulitis due to Tuberculosis was recorded. Tuberculosis of the orbit

is rare in developed countries (Jacobic et al<sup>6</sup>). The majority of cases were reported from under developed countries with a higher incidence of systemic tuberculosis and orbital involvement may result from distant foci or secondary to extension of paranasal sinus tuberculosis. (Mortoda et al,<sup>7</sup> Khalil M et al,<sup>8</sup> Sheldon T et al,<sup>9</sup> Agarwal PK et al<sup>10</sup>).

Two cases of retinoblastoma with orbital cellulitis is also recorded in the present study, Orbital cellulitis is an uncommon presenting feature of retinoblastoma and clinically it corresponds with the inflammatory stage II of bacterial cellulitis (Paul B Mullany<sup>11</sup> et al) Inflammatory signs of ocular adnexa, it's surface and the anterior segment are associated with retinoblastoma associated cellulitis and may mask the underlying diagnosis & may suggest extra ocular extension if particularly the sclera is thickened. In orbital cellulitis like presentation in retinoblastoma does not necessarily indicate extra sclera extension of tumour however correlates with the presence of advanced intra ocular diseases. (Manschol WA<sup>12</sup> et al, Richard W.W<sup>13</sup> et al, PB Mullane<sup>11</sup> et al) In the review of 292 cases of retinoblastoma P.B. Mullaey et al<sup>11</sup> found 14 (4.8%) cases of orbital cellulitis with 10 cases of female and 9 cases of male, 5 cases of right and 9 cases of left sided involvement. In the present study both the cases were of right sided involvement and both the patients were male.

In contrast to bacterial infection which leads to occur in healthy individual, fungal infections have predilection for the debilitated host (Christopher T Westfall<sup>14</sup> et al). In the present study none of the cases of fungal infections were observed. Parasitic infestation of the orbit is relatively rare in this part of geographical location. Occasionally sporadic cases are being found in our institution. During the present study none of the cases of parasitic infestation of the orbit was noted.

## Conclusion

In the study the maximum number of patients were adult though it is not very uncommon in the paediatric age group. Inflammation of the ocular adnexae is the common symptoms while presenting with or without visual effectation.

Association of systemic features like malnutrition, anaemia, diabetes, trauma, tuberculosis and malignancy and source of infection in any part of the body may play an important role. The diagnosis is often an intriguing problem in infections of the orbit as it requires exclusion of non-infectious inflammatory conditions of the orbit because of close clinical similarity. It is also seen that the orbital infection is sight threatening and the pathognomic features and virulence of the causative organism is unpredictable. Early presentation appropriate diagnosis and judicious protocol if followed at an early stage would halt the morbidity and fatality.

**Conflict of Interest:** None.

## References

1. Richard L Dallow, Steven G Pratt, Jeffery P Green, Approach to orbital disorders and frequency of disease occurrence Ch

- 234, Text Book. Of ophthalmology, Albert Jackobic. 4<sup>th</sup> Ed.3056-3067.
2. Bergin DJ, Wright JE orbital cellulitis. *Br J Ophthalmol* 1986;70:174.
3. Watters E C, Waller H, Hilles D.A, Michaelles RH. Ante orbital cellulitis. *Arch Ophthalmol* 94:785.1976
4. Suneetha. N, R.R Batter, R. K. Thomas, A. Bosco. *Indian J Ophthalmol* 2000;48:129-134.
5. Weiss A, Friendly D, Eglin K. Bacterial Periorbital and orbital callulitis in childhood. *Ophthalmol* 1983;90:195.
6. Jackobic FA, Jones IS. Orbital inflammations. Duane's Clinical ophthalmology Philadelphia, Harper & Row 1981 Vol 2 ch. 35.
7. Mortada A. Tuberculosis of orbit and lacrimal gland. *Br J Ophthalmol* 1971;55:565-567.
8. Khalil M, Lindley S, Mautoule E. TB of the orbit. *Ophthalmol* 1985;92:1624-1627.
9. Sheldon T, Warman Preseptal cellulitis caused by Mycobacterium intracellulare. *Ophthalmol* 1982;89:499-501.
10. Agaxwal PK, Nath J, Jain BS. Orbital involvement of tuberculosis. *Indian J Ophthalmol* 1977;25(3):12-16.
11. Mullaney PB, Zeynel AK, Antonio MH, Saleh A M. *Br J Ophthalmol* 1998;82:517-521.
12. Manschot W A. Difficult in Diagn of retinoblastoma. *Ophthalmol* 1956;32:162-164.
13. Richards WW. Retinoblastoma simulating uveitis. *Ophthalmol* 1968;65:427-431.
14. Christopher T. Westfall Ann. Sulivan Balea, John W Shore. Infectious process of the orbit Text book of Ophthalmology Albert Jackobic, IV<sup>th</sup> edition. W. B. Saunders & co. Pg 3121-3129. ed.2.

**How to cite this article:** Das PJ, Mondal A. Clinico-pathological study of orbital inflammatory diseases of infectious origin. *Indian J Clin Exp Ophthalmol* 2019;5(1):48-51.