

CAN GREY CRESCENT PREVENT MACULAR DETACHMENT IN CASE OF OPTIC DISC PIT? A CASE REPORT AND HYPOTHESIS

Sanjiv Kumar Gupta^{1,*}, Ajai Kumar², Arun Sharma³, Siddharth Agrawal⁴, Vishal Katiyar⁵

^{1,3,4,5}Associate professor, ²Senior consultant and Surgeon, Dept. of Ophthalmology, King George's Medical University, Lucknow.

***Corresponding Author:**
E-mail: sanjiv204@gmail.com

ABSTRACT

We here describe a case with bilateral optic disc pit and bilateral asymmetrical grey crescent, its ocular coherence tomography findings and the associated unilateral maculopathy in the eye with incomplete crescent. The interesting observation is that the eye in which the grey crescent encompassed the optic pit did not have any maculopathy in contrast to the other eye which had macular retinoschisis and macular retinal detachment with smaller grey crescent not encompassing the pit. Presence of grey crescents around the optic disc pits may prevent the occurrence of associated maculopathy, similar to the intraretinal tamponade and laser done to treat the maculopathy.

Key Words: *Bilateral optic disc pit, Grey crescent, Maculopathy, Retinoschisis*

Key Messages: *The presence of grey crescent may be protective in cases of optic disc pits, provided it encompasses the temporal perimeter of the optic disc pit.*

INTRODUCTION

Optic disc pit is one of the congenital optic disc anomaly first described by Weithe in 1882. Later on series of cases were reported by Greear⁽¹⁾, Kranenburg.⁽¹⁾ The case series reported by them had majority of unilateral optic disc pits. Two thirds of these Optic disc pits may be associated with schitic cavity at macula or may have serous detachment of macula. Association of optic disc pit with other disc anomalies have been reported like myelinated nerve fibre layer, multiple pits by Malik S.⁽²⁾ coloboma of the disc with duplication of the disc.⁽¹⁾

In 1980, Bruce Shields described a pigmented crescent of the optic disc which appeared to be located within the substance of the optic nerve head and termed this the grey Crescent. Jonsson and colleagues found that the grey crescent was present in about 22% of the eyes examined. It was more commonly found in women, in hyperopic eyes, and in eyes without small Para papillary atrophy. It was associated with a large optic disc, and it was usually located in the temporal region of the optic disc. Since the grey crescent is relatively dark, it may be associated with retinal pigment epithelium cells.⁽³⁾

The case reported here is of interest as none of the cases of optic disc pit reported earlier had an associated grey crescent and most of the reported cases were unilateral. This association of grey crescent and optic disc pit provides us added insight of the pathology of the conditions. University ethics committee was informed before reporting this as a case report.

CASE HISTORY

15 year old female presented in the OPD with the complaint of diminution of vision in her right eye for last 3 years which has been static since then. There were additional complaint of flashes and floaters in the right eye since then.

On examination she had visual acuity of 3/60 in right eye and 6/6 in the left eye. There was no improvement in the vision with refraction. The pupillary reactions were normal with no RAPD (relative afferent pupillary defect) in any eye. The amsler's grid evaluation showed metamorphopsia in the central field in the right eye.

Slit lamp evaluation showed an unremarkable anterior segment in both eyes. In the right eye the posterior segment evaluation showed a typical optic disc pit in the temporal part of the disc with superotemporal grey crescent. There was pigmentary heterogeneity in the macular area with hypo pigmented dots. **Fig. 1.** The left eye had a similar optic disc pit and a larger temporal grey crescent which ended just short of the pit.

The optic disc pit in the right eye was larger and had poorly defined margins when compared to the pit in the left disc. Rest of the fundus was normal. **Fig. 2.** A provisional diagnosis of bilateral optic disc pit with macular detachment was kept. An OCT (ocular coherence tomogram) was ordered to evaluate the macular area and the pit anatomy of both the eyes.

The OCT revealed presence of neurosensory detachment at the macula in the right eye with a schitic cavity near the disc. **Fig. 3.** The OCT section was positioned across the optic disc pit and thus it was seen as an abyss defect in the layers of the retina

in both eyes. In the left eye the grey crescent covered a larger area and hence the OCT section was across the grey crescent and then through the optic disc pit. Here it was evident that the grey crescent was indeed a continuation of the retinal pigment epithelium which had continued under the optic disc margin up to the temporal border of the pit. **Fig. 4.** Treatment in form of parsplana vitrectomy for right eye was offered to the patient who refused to undergo the procedure because of personal reasons. The patient was advised to be on follow up every 3 months.

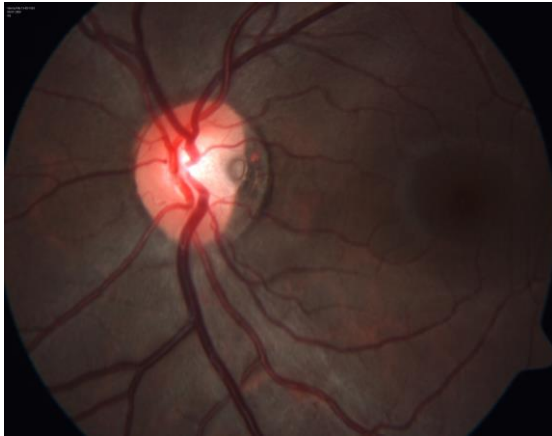

Fig. 1: Colour fundus photograph of right eye showing the optic disc pit, grey crescent and the associated maculopathy

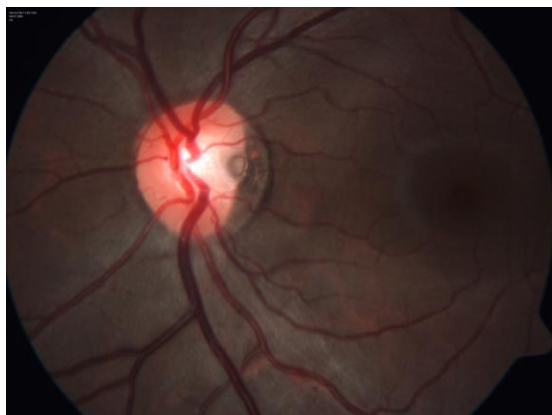


Fig. 2: Colour fundus photograph of left eye showing the optic disc pit and grey crescent

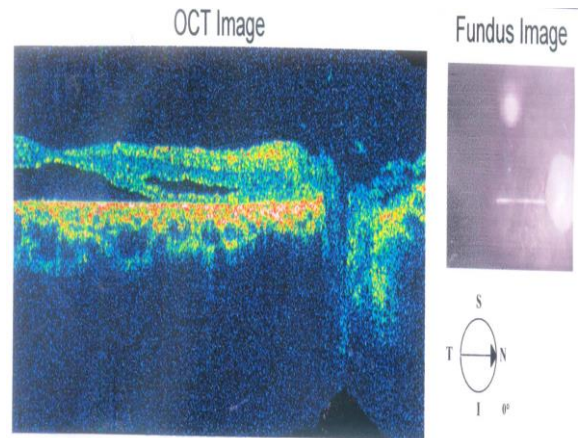


Fig. 3: OCT of right optic disc pit, showing the optic disc pit, the macular schitic cavity and the macular detachment. Note the disorganised tissue between the Retinal pigment layer and the pit

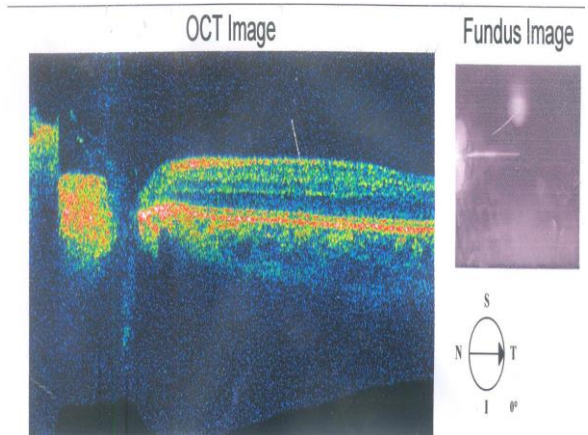


Fig. 4: OCT of the left eye showing the optic disc pit and normal macular area. Note the continuation of the RPE up to the pit margin

DISCUSSION

The association of optic disc pit and grey crescent has not been discussed in the available literature, to the best of our knowledge. The case discussed has bilateral optic disc pit which itself is rare [Error! Bookmark not defined., Error! Bookmark not defined.] together with grey crescents.

The origin of optic pits remains unclear. Optic pits have been associated with colobomatous lesions, suggesting that they result from incomplete closure of the foetal fissure. Thus there being a defect in the lamina cribrosa. [Error! Bookmark not defined.] Others propose that they result from abnormal differentiation of primitive epithelia papilla. Overall the high incidence of maculopathy in form of schitic cavity or macular detachment does indicate that there is a possible communication channel created by the pit between the prelaminar space and sub retinal space. This communication channel can explain the macular detachment seen in these patients.

This case also had grey crescents along the temporal margin of the disc which is larger in the left eye and encompasses the area of the optic pit. We believe that the presence of the grey crescent in such a manner protects the left eye from associated maculopathy. This hypothesis is based on the difference in the OCT image in both the eyes. The OCT section was obtained along the vector cutting through the optic pit in both the eyes. In the right eye the disorganised tissue can be seen at the pit which can allow the seepage of the fluid from the vitreous cavity into the retina and sub retinal space resulting into the maculopathy. However the section in the left eye shows the tight approximation of the retinal pigment epithelium and the pit cavity, thus leaving no space for communication between the vitreous cavity and the sub retinal space.

Thus in our opinion the presence of the grey crescent encompassing the optic disc pit is protective and is similar to the attempt to treat the maculopathy by external or internal tamponade with or without laser as reported in the literature.^(3,4)

REFERENCES

1. James n. Greear jr. Pits, or crater-like holes, in the optic disk. *Arch Ophthalmol.* 1942;28(3):467-483.
2. E. W. Kranenburg. Crater-like holes in the optic disc and central serous retinopathy. *Arch ophthalmol.* 1960;64(6):912-924.
3. Malik S, Gupta AK, Singh G. Bilateral multiple congenital pits in the optic disc with opaque nerve fibres and maculopathy. *Indian J Ophthalmol.* 1969;17:117-9
4. Vasumathy Vedantham. Double optic discs, optic disc coloboma, and pit: spectrum of hybrid disc anomalies in a single eye. *Arch Ophthalmol.* 2005;123:1450-1452
5. J B Jonas. Optic nerve grey crescent. *British J Ophthalmol.* 2005;89:3.
6. M P Snead, N James, P M Jacobs. Vitrectomy, argon laser, and gas tamponade for serous retinal detachment associated with an optic disc pit: a case report. *British J Ophthalmol.* 1991;75:381-382.
7. Philip M Falcone, Peter L Lou. Resolution of an external layer macular hole associated with an optic nerve pit after laser photocoagulation. *British J Ophthalmol.* 1993; 77: 457-459.