

ADJUSTABLE ANTERIOR AND NASAL TRANSPOSITION OF INFERIOR OBLIQUE MUSCLE IN CASE OF TORSIONAL DIPLOPIA IN SUPERIOR OBLIQUE PALSY

Rohit Saxena^{1*}, Digvijay Singh², Anuradha Chandra³, Pradeep Sharma⁴

¹Additional Professor, ³Consultant, Dr. Rajendra Prasad Centre for Ophthalmic Sciences, All India Institute of Medical Sciences, New Delhi,

²Associate Consultant, Medanta-The Medicity, Gurgaon, Haryana

***Corresponding Author:**

E-mail: rohitsaxena80@yahoo.com

ABSTRACT

Superior oblique palsy presents with a vertical and torsional deviation and diplopia which is often exacerbated by an ipsilateral inferior oblique over action. The usual surgical approach is defined by the extent of inferior oblique over action and/or vertical deviation and includes weakening of the ipsilateral inferior oblique muscle. If torsional diplopia outweighs the vertical component then, an antero-nasal transposition of the inferior oblique may be undertaken to correct both. We describe a novel surgical technique for adjustable antero-nasal transposition of the inferior oblique muscle for a residual torsional diplopia in one case of a superior oblique palsy.

Keywords: Adjustable, Inferior oblique surgery, Superior oblique palsy, Torsional diplopia

INTRODUCTION

Management of superior oblique palsy has been systematized by Von Nooden's modification of the Knapp's classification.^{1,2} The various surgical procedures described include ipsilateral inferior oblique recession, superior oblique tucking, Harada-Ito procedure and/or contralateral inferior rectus recession. Besides these, various other surgical procedures and their modifications are known. To tackle hypertropia, another procedure entailing an anterior transposition of the inferior oblique has been described while additionally an antero-nasal transposition is shown to handle any extorsion. The chief complaint of patients with trochlear nerve palsy is diplopia, both vertical and torsional, which they minimize by adopting a head tilt position. In the absence of significant vertical deviation in the primary gaze but significant torsional diplopia, anterior and nasal transposition of the inferior oblique may be undertaken. However, in view of the minimal torsional fusion amplitudes, it would require fine adjustment to correct the patients symptoms altogether. We describe a novel technique to perform an adjustable antero-nasal transposition of the inferior oblique muscle in order to obviate torsional diplopia in one patient previously operated for correcting the hypertropia induced due to a superior oblique palsy.

CASE REPORT AND TECHNIQUE

A 33 year old male developed a right superior oblique palsy after a head trauma one year back. The patient had undergone an inferior oblique antero-positioning two months back but continued to have diplopia in levoversion and in up gaze. On

detailed examination, the excycloductions at primary, up gaze and down gaze were 6, 8 and 4 degrees on the synoptophore. The prism bar cover test revealed a residual hypertropia of 12 prisms and superior oblique under action of -1 and inferior oblique over action of +1. (Figure 1A) Significant excyclotorsion was also observed on the preoperative fundus photograph. (Figure 2A) In view of persistent diplopia and second surgery, an adjustable antero-nasal transposition of the inferior oblique was planned.

The patient was explained the procedure and formal consent was obtained. Under peribulbar block with lignocaine injection, a limbal incision of 4 mm was made inferiorly and inferior rectus muscle was dissected and exposed. The inferior oblique was found inserted lateral to the inferior rectus. All adhesions around the inferior oblique were cleaned and the tissue septa between the inferior oblique and rectus was dissected. A double-armed 6-0 polyglactinsuture was passed 5 mm from the insertion site through the width of the inferior oblique muscle and locking bites were taken on both ends. The sutures were passed 2 mm anterior to the nasal border of inferior rectus and were tied over a mersilene suture using a bow tie knot. (Figure 3) A second bucket handle suture was passed near the limbus using an 8-0 polyglactinsuture for better globe manoeuvrability during adjustment. The conjunctiva was then closed keeping the sutures exposed in the inferior fornix. When the patient regained complete ocular movements after about 6 hours of surgery, the diplopia was measured in levoversion in elevation and depression. The patient had minimal torsional and vertical diplopia in the immediate postoperative

period and an adjustment was planned. The globe was moved up and out using the bucket handle suture while the mirsilene suture was cut and removed and the bow tie knot opened. The inferior oblique sutures were tightened and tied, bringing the inferior oblique anteriorly in the process. The knot was finalized and sutures were retracted and cut in the final position

when patient could see single images in levoelevation and levodepression. The bucket handle suture was also cut. The postoperative fundus photo showed mild in torsion as was planned. (Figure 2B) The patient was followed in the outpatient clinic at 1 month and did not have any diplopia with alignment in all positions of gaze. (Figure 1B)

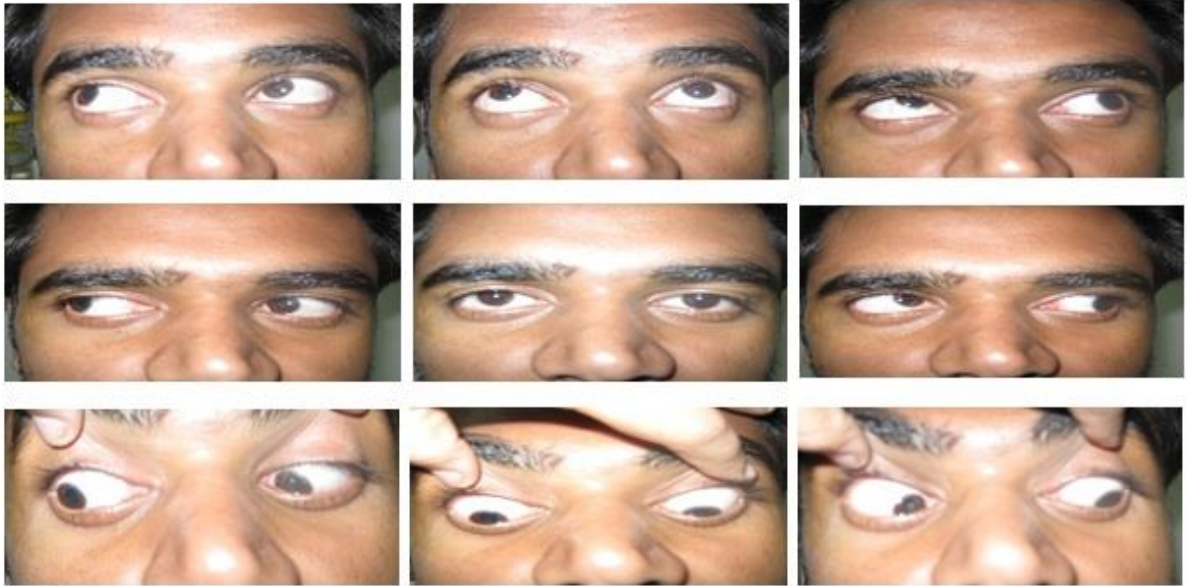


Fig 1A: Preoperative 9 gaze photograph of the patient with right superior oblique palsy showing the residual hypertropia in primary gaze increasing in levoversion and maximally in levoelevation.

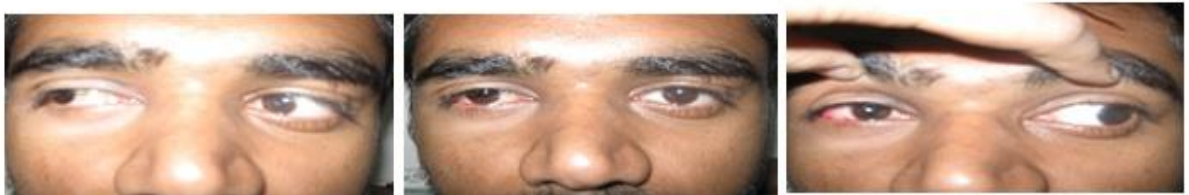

Fig 1B: Postoperative 3 gaze photograph of the patient showing the correction of right hypertropia in primary gaze and levoversion.

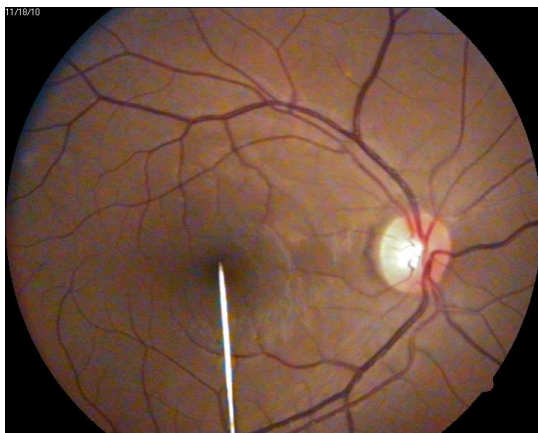


Fig 2A: Preoperative fundus photograph of the patient showing a significant exocyclotorsion

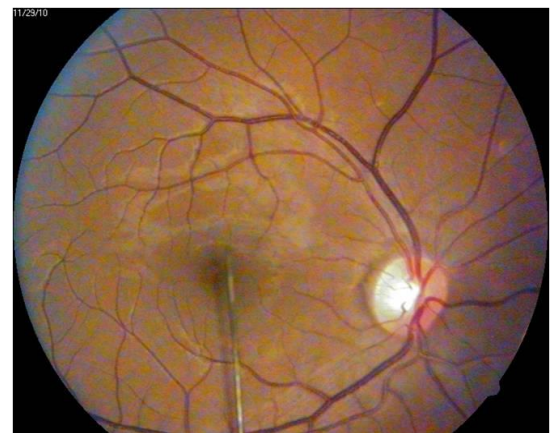


Fig 2B: Postoperative fundus photograph of the patient showing a slight incyclotorsion

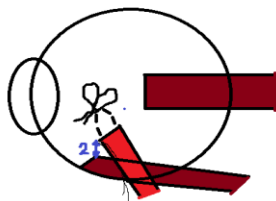


Fig 3: Schematic depiction of the final point of insertion of the inferior oblique in the adjustable anterior and nasal transposition technique described. The deep red colors are the medial and inferior recti muscles while the lighter red is the inferior oblique muscle. The inferior oblique is inserted in adjustable loop 2 mm from nasal border of inferior rectus in between medial rectus and inferior rectus

DISCUSSION

Anterior transposition of the inferior oblique muscle is a well described and preferred surgical modality for treating dissociated vertical deviation when it is associated with inferior oblique muscle overaction.³⁻⁸ Stager and colleagues proposed transposing the inferior oblique muscle both anteriorly and nasally to the nasal edge of the inferior rectus muscle.⁹⁻¹¹ As a result of this procedure, the insertion of the inferior oblique muscle is placed nasally to the y-axis (affecting torsional movement) and anterior to the x-axis (affecting vertical movement), thereby converting it from an extorter and elevator to an intorter and depressor in adduction. We furthered this procedure by converting it into an adjustable one. Traditionally, adjustable sutures are not frequently used on the inferior oblique. This is attributed to the fact that the inferior oblique is attached to the inferior rectus and presents with reduced chance of free mobility. Also, after a recession, there is adequate lax muscle adhered close to the globe whereby, it does not slide back unlike the recti on loosening of the sutures. Finally, the posterior location of the oblique, in relation to the recti, makes it difficult to access for adjustment. In our case, however, the inferior oblique was well dissected and advancement of the oblique more anterior and nasal was required making it amenable to adjustment.

Previously, a similar adjustable technique has been described for inferior oblique recession but it faces the limitations described above and was more of theoretical significance since none of the cases had required adjustment.¹²

To conclude, an adjustable antero-nasal transposition of the inferior oblique has a definite role to play in situations where an accurate correction of torsional diplopia secondary to superior oblique palsy is needed. The benefit and success of an adjustable surgery in a previously operated case has been clearly demonstrated in this case report.

REFERENCES

1. Knapp P. and Moore S. Diagnosis and Surgical options in superior oblique surgery. *Int. Ophthalmol. Clin.* 16: 137, 1976.
2. Noorden G.K. Von, Murray E., Wong S.Y. Superior oblique paralysis. A review of 270 cases. *Arch. Ophthalmol.* 104: 1771. 1986.
3. Elliott RL, Nankin SJ. Anterior transposition of the inferior oblique. *J Pediatr Ophthalmol Strabismus* 1981;18:35-8.
4. Mims J. Benefits of bilateral anterior transposition of the inferior obliques. *Arch Ophthalmol* 1986;104:800-1
5. Kratz RE, Rogers GL, Bremer DL, Leguire LE. Anterior tendon displacement of the inferior oblique for DVD. *J Pediatr Ophthalmol Strabismus* 1989;26:212-32.
6. Bacal DA, Nelson LB. Anterior transposition of the inferior oblique muscle for both dissociated vertical deviation and/or inferior oblique over action: results of 94 procedures in 55 patients. *Binocular Vis Eye Muscle Surg Q* 1992;7:219-25.
7. Mims JL III, Wood RC. Bilateral anterior transposition of the inferior oblique. *Arch Ophthalmol* 1989;107:41-4.
8. Ziffer AJ, Isenberg SJ, Elliott RL, Apt L. The effect of anterior transposition of the inferior oblique muscle. *Am J Ophthalmol* 1993;116:224-7.
9. Stager DRSr, Beauchamp GR, StagerDRJr. Anterior and nasal transposition of the inferior oblique muscle: A preliminary case report on a new procedure. *Binocul Vis Strabismus Q* 2001;16:43-4.
10. Stager DR Jr, Beauchamp GR, Wright WW, Felius J, Stager D Sr. Anterior and nasal transposition of the inferior oblique muscles. *J AAPOS* 2003;7:167-73.
11. Hussein MA, Stager DR Sr, Beauchamp GR, Stager DR Jr, Felius J. Anterior and nasal transposition of the inferior oblique muscles in patients with missing superior oblique tendons. *J AAPOS* 2007;11:29-33.
12. Kumar K, Bhole R et al. Hang-back recession of inferior oblique muscle in V-pattern strabismus with inferior oblique overaction. *J AAPOS* 2008;12:401-4.