

## EPIDEMIOLOGY AND FACTORS AFFECTING VISUAL ACUITY IN FUNGAL KERATITIS IN EASTERN UTTAR PRADESH

Sujit Deshmukh<sup>1</sup>, Shraddha Pandey<sup>2,\*</sup>, Rajendra P. Maurya<sup>3</sup>,  
Mahendra K Singh<sup>4</sup>, Virendra P Singh<sup>5</sup>, Ishan Yadav<sup>6</sup>

<sup>1,6</sup>Senior Resident, <sup>2</sup>Junior Resident, <sup>3</sup>Assistant Professor <sup>4,5</sup>Professor,  
Department of Ophthalmology, Institute of Medical Sciences,  
Banaras Hindu University, Varanasi-221005, UP, India

\*Corresponding Author:

E-mail: shraddha2315@gmail.com

### ABSTRACT

**Background:** Fungi can cause devastating ocular infections like keratitis and endophthalmitis; however, there are limited studies available on the epidemiology and risk factors of fungal ocular infections in Northern India. The aim of this study is to determine the epidemiology and factors affecting visual acuity in fungal keratitis, in population of Eastern Uttar Pradesh.

**Methods:** All patients were reviewed for demographic features, predisposing factors, prior therapy, clinical features, microbiological findings, medical and surgical treatment, and outcome of therapy. For microbiological study corneal scrapings were taken by the Ophthalmologist using sterile blades. For the isolation of fungi, samples were inoculated on specific media and KOH mount were done. The identification of fungi was performed by microscopic evaluation and growth on specific media. Different epidemiological factors and risk factors were assessed and compared to find association of risk factors to visual acuity in fungal keratitis.

**Results:** Out of total 295 cases of culture-proven keratomycosis at our institute during the study period between June 2010 and March 2015, 254 cases were included in the analysis. In our study most of the patients (61.42%) were male, significant number of patients were from lower socio economic status (89.76%) and from rural background (91.34%). Illiteracy was one of the major factor was found in our patients (85.04%). 48.03% study subjects were having history of ocular trauma while 7.87% patients were Diabetics. Other factors responsible for poor visual outcome were patients age (age > 40 years in 66.15%), delayed Presentation (> 7 days, 82.22%), use of topical steroids (90.63%) and TEM (80.00%), patients having infection caused by septate fungi (74.36%), hypopyon (89.19%) and central corneal ulcer (78.74%). Factors could not be assessed in 2 patients less than 1 year of age, so their visual acuity was not recorded.

**Conclusions:** History of trauma, use of topical steroid, diabetes, lid margin disorders are major predisposing factors for fungal keratitis. Age > 40 years, steroid use, late presentation, central location of ulcer with hypopyon and use of traditional eye medication (TEM) were major risk factors for poor visual acuity with corneal opacity being most common complication.

### INTRODUCTION

Suppurative keratitis is a preventable sight threatening condition. In some developing countries in the tropics, corneal infections are the second commonest cause of blindness after un-operated cataract[1-3]. Suppurative corneal ulcers may be caused by bacteria, fungi, and protozoa. However, within the tropics, as many as two thirds of ulcers may be due to filamentous fungi. This type of ulceration is commonly associated with ocular trauma[2-9]. Untreated suppurative keratitis ultimately lead to perforation of the cornea and opacification. The associated morbidity is the result of several factors and is directly affected by difficulties in patient management because of a lack of diagnostic facilities and appropriate treatment. Specific treatment requires prompt and accurate identification of the causative micro-organisms[10]. Within the setting of rural eye hospitals in the tropics laboratory facilities are rare and diagnosis is based on clinical characteristics. As a direct result of this, treatment is often empirical.

Corneal blindness is a major public health problem worldwide and infectious keratitis is one of the predominant causes. Corneal infection of fungal

etiology (keratomycosis) is very common and represents 30-40% of all cases of culture-positive infectious keratitis[4-6]. Moreover, fungi have replaced bacteria as the predominant cause of infectious keratitis in developing countries[5-8]. Keratomycosis is most commonly caused by yeast and filamentous fungi which can be further classified into two types: pigmented (dematiaceous) fungi which produce characteristic black/brown pigment appreciable clinically and/or on culture media and nonpigmented (moniliaceous) fungi which do not produce such pigments. Most of the existent literature on keratomycosis is focussed mainly on nonpigmented filamentous fungi or *Candida* spp. as etiological agents.

As a group, the pigmented fungi have increasingly gained importance as agents causing corneal ulcers, second only to *Fusarium* and *Aspergillus* species[11-12]. *Curvularia* species are saprophytic dark pigmented fungi found in soil and are considered the commonest cause of pigmented fungal corneal ulcer. Other dematiaceous fungi such as *Alternaria*, *Exserohilum*, *Cladosporium*, *Botryodiplodia* and *Biopolaris* are also known to cause human keratomycosis[13-15]. Except for one

large series by Garg *et al.*, and another by Wilhelmus *et al.*, rest of the literature on pigmented fungal keratitis have been published case reports, with emphasis on the appearance of the pigmented lesion in some. However, little is known about the outcomes of dematiaceous fungal keratitis especially in comparison with the more common nonpigmented keratitis[16-21].

The microbial causes of suppurative keratitis vary considerably between continents and countries and also within countries. It is essential to determine the local aetiology within a given region when planning a corneal ulcer management strategy. Several studies have investigated the epidemiology of corneal ulceration, causative micro-organisms, and effective treatments, particularly in the Indian subcontinent. However there is a paucity of information in the literature with regard to the experience in north India. The following study was conducted at hospitals in Sir Sunderlal Hospital, IMS, Banaras Hindu University, Varanasi, Uttar Pradesh, India to study factors responsible for poor visual outcomes in fungal keratitis and to study incidence of fungal keratitis in relation to age, sex, occupation and season in hospital based population. The aims of this investigation were to improve facilities for laboratory diagnosis, to determine the predominant causative micro-organisms, to identify the most suitable treatments, and encourage rapid referral of patients.

## MATERIALS AND METHODS

A prospective study of suppurative keratitis was conducted in Sir Sunderlal Hospital, IMS, Banaras Hindu University, Varanasi, India between June 2010 and March 2015. Patients who presented with suppurative keratitis from Uttar Pradesh, Bihar and Madhya Pradesh were recruited at the eye department of Institute of Medical Sciences, BHU included in the study. All patients presenting with suspected features of fungal keratitis were included in the study. Corneal ulceration was defined as loss of corneal epithelium with underlying stromal infiltrate and suppuration associated with signs of inflammation, with or without hypopyon. Patients with suspected or confirmed bacterial and viral keratitis and any other corneal pathology causing visual impairment were excluded from the study. Patient consent was mandatory for inclusion in the study.

### Clinical examination and laboratory investigation:

All patients, with culture proven diagnosis of keratomycosis, who presented to the eye department were identified from a computerized database. Medical and microbiological records of these patients were reviewed for demographic features, predisposing factors, prior therapy, clinical features, microbiological findings, medical and

surgical treatment, and outcome of therapy. Only those with thorough slit-lamp examination and good documentation in the case records were included in the analysis. The location, size, depth, nature of the infiltrate; presence of clinically detectable pigmentation; endothelial exudates; and anterior chamber reaction or hypopyon were recorded, at the time of presentation. Best corrected visual acuity (BCVA) was measured using Snellen's distance visual acuity chart.

As a routine, corneal scrapings were obtained from all patients with corneal ulcers using a sterile 15 number blade under slit-lamp magnification. Material obtained from the base and edges was examined microscopically using freshly prepared potassium hydroxide (10%) and Gram staining methods, and was directly inoculated on various solid media in the form of multiple rows of C streaks; growth occurring only on the C streaks was considered to be significant. All inoculated media were incubated aerobically. Cultures were checked every day during the first week and twice a week for the next 3 weeks. The inoculated blood agar, chocolate agar, thioglycolate broth and brain-heart infusion broth were incubated at 37°C. The inoculated potato dextrose agar (PDA) were incubated at 27°C and discarded at 4 weeks if no growth was seen.

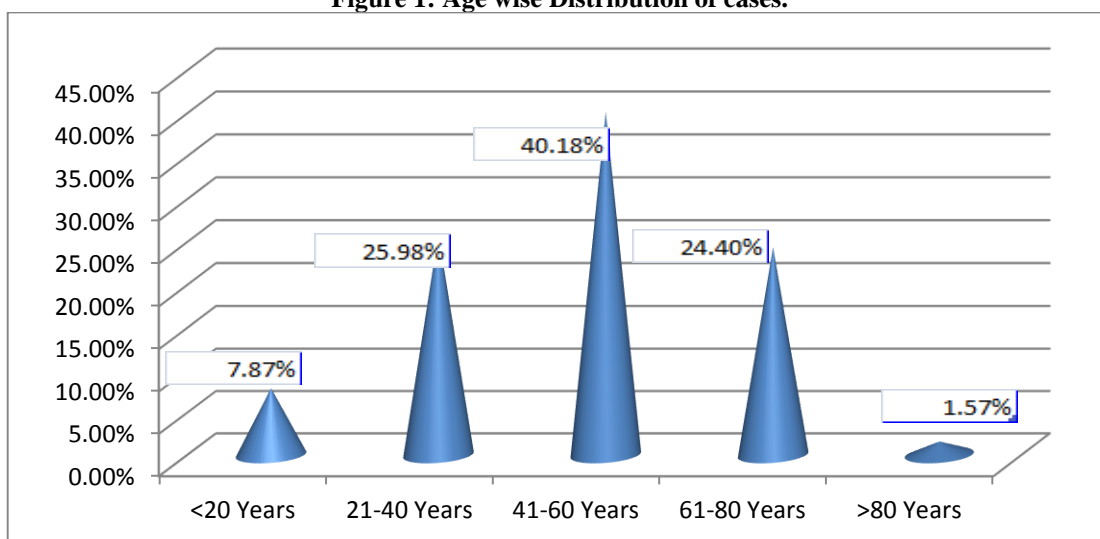
Microbial cultures were considered significant if, growth of the same organism was demonstrated on more than one solid-phase medium, and/or if there was a confluent growth at the site of inoculation on one solid medium, and/or if growth of one medium was consistent with direct microscopy findings and/or if the same organism was grown from repeated scrapings. Any growth present on the medium was identified by standard laboratory techniques viz., the rate of growth, colony morphology on PDA and microscopic appearance of fungal hyphae and conidia in lactophenol cotton blue mount and slide culture. Speciation was based on the characteristics of conidia and spore bearing structures wherever possible. An isolate was considered dematiaceous, if fungal colonies revealed black or brown pigmentation and Lactophenol cotton blue mount from the culture revealed black or brown pigmented hyphae, conidia or both. Medical treatment was based on the smear results and was modified depending on the clinical response.

## RESULT

Out of total 295 cases of culture-proven keratomycosis at our institute during the study period, 254 with good documentation were included in the analysis. Table 1 shows the age distribution in fungal pathogens isolated from the two groups in our study. It shows maximum number of cases belong to age of 40 to 60 years and least in extreme age groups.

**Table 1: Showing Age-Wise Distribution**

Sr. No	AGE	No. Of Patients	Percentage
1.	<20 years	20	07.87%
2.	21-40 years	66	25.98%
3.	41-60 years	102	40.18%
4.	61-80 years	62	24.40%
5.	>80 years	04	01.57%
	TOTAL	254	100%

**Figure 1: Age wise Distribution of cases.**

In our study most of the patients (61.42%) were males, correlated with their outdoor work. We also found that 91.34% (n= 232) of our patients were from rural background and remaining 8.66% (n= 22) from urban areas. Comparing to socio-economic status of the patients significant number of patients (89.76%) were from lower socio economic status corresponding to inaccessibility to treatment, poor personal hygiene and in compliance towards the treatment. Illiteracy was one of the major factor was found in our patients (85.04%).

Maximum numbers of our patients were farmers (100) and labourers (80). Nineteen patients were housewives. In this study, most of the patients were reported in October to December (88) followed by July-September (70).

**Table 2.**

Sr. No.	Predisposing Factors	No. of patients	Percentage
1.	History of trauma	122	48.03%
2.	Topical steroid use	64	25.20%
3.	Use of TEM	30	11.81%
4.	Chronic dacrocystitis	30	11.81%
5.	Lid and margin abnormalities	16	6.30%
6.	Blepharitis	14	5.51%
7.	Bell's palsy	4	1.57%
8.	Dry eye	4	1.57%
9.	H/o Diabetes	20	7.87%

In our study, 180 patients had predisposing factors for fungal keratitis. Trauma (122) was the most common associated factor. Topical steroid instillation (64), use of traditional eyes medicines (30), chronic dacrocystitis (30), lid and lid margin abnormalities (16), blepharitis (14), Bell's palsy(4), dry eye (4), history of diabetes (20) were other predisposing factors.

In our study, 78.74% of patients had ulcer with central location, 46.46% had more than 4mm of diameter, 29.31% had hypopyon, 15.18% had satellite lesion and 7.87 and 3.15% had immune ring and pigmentation respectively.

**Table 3: Showing Complications of Fungal Keratitis**

Sr. No.	Complications	No. patients	Percentage
1.	Corneal opacity	230	90.55%
2.	Vascularisation	70	27.56%
3.	Perforation	22	8.66%
4.	Descemetocele	18	7.09%
5.	Anterior staphyloma	4	1.57%

In this study, corneal opacity (230) was the most common complication. While vascularisation was seen in 70, perforation was seen in 22, descemetocele in 18 and anterior staphyloma in 4 patients.

Filamentous fungi were the most common cause in our study and rest of patients had yeast fungi infection. Visual acuity was recorded in 250 patients; two of our patients were less than 1 year of age, so their visual acuity could not be recorded. In this study, 58.40% of patients had vision up to 1/60 at the time of presentation and 21.60% of patients had visual acuity > 6/60. At the final follow up, 48% had VA up to 1/60, 21.6% had between 1/60 to 6/60, and 30.4% had > 6/60.

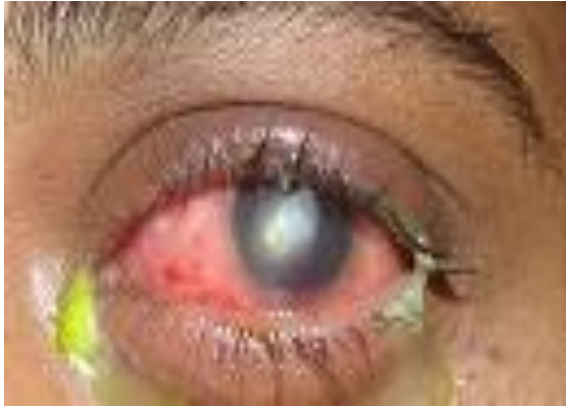All patients were initially treated with topical natamycin drops on an hourly basis for 48 hours followed by tapering, after the diagnosis was confirmed microbiologically by smear. Patients with deep mycosis (endothelial plaque) and hypopyon were treated on an in-patient basis. The rest were treated as out patients and closely followed up. After 1 week, an additional topical antifungal drug was added in cases of inadequate response (either worsening or slow response) and oral fluconazole was added to the regimen if deep mycosis occurred. The commonest topical agent used in combination with topical natamycin was itraconazole. Oral fluconazole was commonest systemic antifungal used. Superficial keratectomy was done for superficial plaque like pigmented infiltrates.

There was a statistically significant improvement in mean visual acuity after completion of treatment compared with that at presentation.

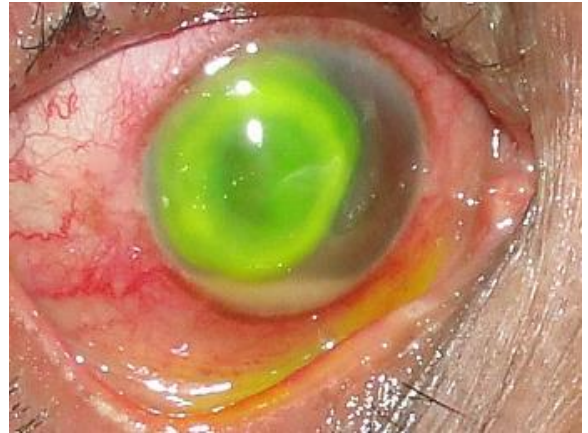**Table 4: Showing Factors Affecting Visual Outcome**

SR. NO	FACTORS	Visual Acuity Upto 6/60	Visual Acuity > 6/60	P -Value
1a	AGE < 40 YEARS (n= 82)	44 (53.66%)	38 (46.34%)	P <0.05
1b	AGE > 40 YEARS (n=168)	130 (77.38%)	38 (22.62%)	
2a	PRESENTATION < 7 DAYS (n=70)	26 (37.14%)	44 (62.86%)	P <0.05
2b	PRESENTATION > 7 DAYS (n=180)	148 (82.22%)	32 (17.78%)	
3a	USED STEROID DROPS (n=64)	58 (90.63%)	6 (9.37%)	P <0.05
3b	DID NOT USE STEROID DROPS (n=186)	116 (62.37%)	70 (37.63%)	
4a	USED TEM (n=30)	24 (80%)	6 (20%)	P=0.526
4b	DID NOT USE TEM (n=220)	150 (68.18%)	70 (31.82%)	
5a	CENTRAL ULCER LOCATION (n=196)	172 (87.76%)	24 (12.24%)	P <0.05
5b	PERIPHERAL ULCER (LOCATION)(n=54)	2 (3.70%)	52 (96.30%)	
6a	HYPOPYON PRESENT (n=74)	66 (89.19%)	8 (10.81%)	P <0.05
6b	HYPOPYON ABSENT (n=176)	108 (61.36%)	68 (38.64%)	
7a	SEPTATE HYPHAE (n=156)	116 (74.36%)	40 (25.64%)	P=0.241
7b	ASEPTATE HYPHAE (n=78)	50(64.10%)	28 (35.90%)	
7c	YEAST FORM (n=16)	8 (50%)	8 (50%)	

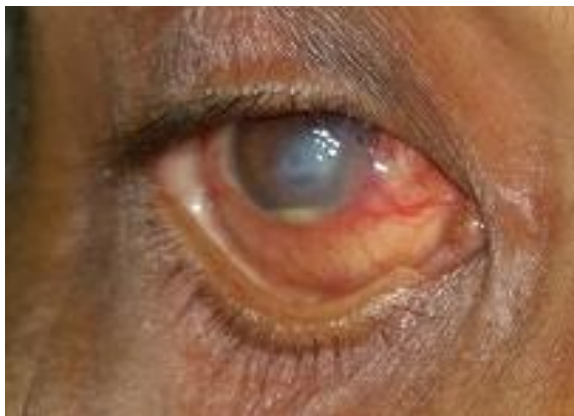In our study, 77.38% of patients with age > 40 years, 82.22% of patients with day of presentation > 7 days, 90.63% of patients using topical steroids, 87.76% of patients with central corneal ulcer, 80.00% using TEM, 89.19% of patients having hypopyon, 74.36% of patients having septate fungi infection had final visual acuity up to 6/60. However, TEM use and septate fungi infection were not statistically significant as compared to others. Factors could not be assessed in 2 patients less than 1 year of age, so their visual acuity was not recorded.



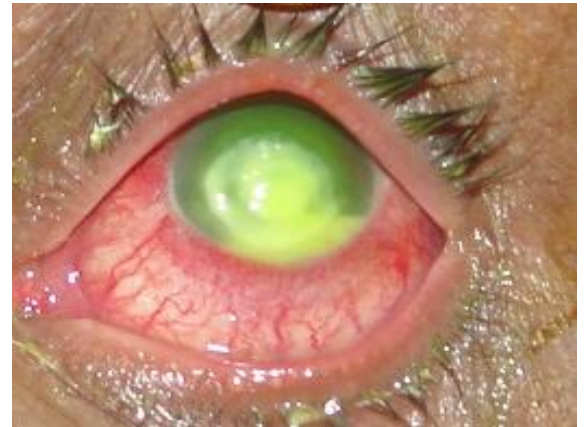
**Fig. 1: Fungal corneal ulcer involving central cornea with Conjunctival congestion**



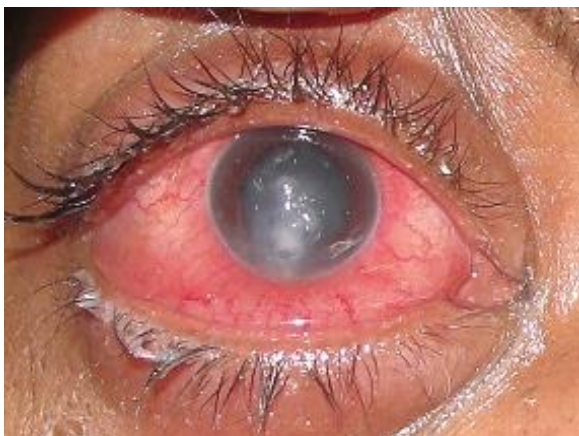**Fig. 4: Diffuse Fluorescein stain positive fungal corneal ulcer with hypopyon**



**Fig. 2: Fungal corneal ulcer: Resolving stage with mild hypopyon**



**Fig. 5: Fluorescein Stain positive fungal corneal ulcer showing corneal thinning**



**Fig. 3: Fungal corneal ulcer: corneal edema with bullae formation**

## DISCUSSION

Fungal keratitis, which is a serious ocular infection, causes scarring and opacification in the cornea. Trauma caused by wearing contact lenses or by a foreign object falling into the eye or trauma by vegetable matter, or corneal defects and abnormalities of the ocular surface are the most frequently reported predisposing factors for microbial keratitis. Endophthalmitis, which is also a severe intraocular infection caused by fungi, occurs as a complication after intraocular surgeries, especially on the posterior segment of the eye. Titiyal et al. reported that the delay in starting a definite treatment is a risk factor for perforation in corneal ulcers. According to their findings, Titiyal et al. and Stapleton et al[22-23]. Indicated that contact lens wear, trauma with vegetable matter or trauma with something falling into the eye were the predisposing factors for fungal keratitis.

A review of the literature shows that there are distinct patterns of geographical variation in the aetiology of suppurative keratitis and considerable variation in the proportion due to fungi has been

documented. The proportion of corneal ulcers caused by filamentous fungi increases towards tropical latitudes. In more temperate climates, fungal ulcers are uncommon and are more frequently associated with *Candida* species than filamentous fungi. Houang et al reviewed the relation of fungal keratitis to climate concluding that, although a higher incidence of fungal keratitis could be expected in countries with similar annual rainfall and temperature range, this was not always so and was also dependent on the extent of urbanisation [24].

Fungal keratitis continues to be a significant cause of ocular morbidity in rural illiterate population following agricultural trauma. Application of topical steroid drop, TEM use and other predisposing factors had led to the exacerbation of infection; affecting final visual acuity. KOH mount has been rapid, inexpensive and reliable method for diagnosis of fungal keratitis.

The present day study consists of 254 consecutive patients of fungal keratitis from outpatient department and those admitted in department of Ophthalmology, in Sir Sunderlal Hospital, IMS, Banaras Hindu University, Varanasi, India between June 2010 and March 2015. Patients were followed for 6 months and their visual acuity was recorded.

At the completion of study, data was analysed and following conclusions were drawn- Incidence of fungal keratitis cases was maximum in 41-60 years of age group followed by 21-40 years of age group which was similar to reported by Lixin Xie et al. and M. Jayahar et al who found that maximum patients (66.85%) were between the ages 21 to 50 years. Fungal keratitis was more common in males and it was in accordance with studies of M. Jayahar Bharathi et al, Reema nath et al, Pranja Lalitha et al who reported male preponderance in 65.02%, 67.60%, & 55.6% of patients respectively [25-28].

Cases of fungal ulcer were predominantly in rural areas, were from low socio economic status and were illiterate. Maximum number of cases were farmers and labourers as vegetative matter being one the most common causes in these occupations which was similar to reported by Lixin Xie et al and M. Jayahar et al who found that maximum patients (66.34%) were farmers ( $p < 0.001$ ) [29-31].

Incidence of fungal keratitis was higher in months of November and December corresponding to harvesting season in this area. Trauma to cornea was the most common predisposing factor for mycotic keratitis in our study which was similar to studies of Bastola P et al, Reema nath et al and M Jayahar et al [32-36]. Other factors were topical steroid use, blepharitis, chronic dacryocystitis, Bell's palsy and diabetes. Most of the ulcers presented were in central location. Corneal opacity was the most common frequently occurring complication. Ashok Kumar

Narsani et al found that 68.91% eyes had larger ulcers (diameter > 5mm), typical satellite lesion in 16.76% patients and hypopyon seen in 60.55% patients [37-38]. This study has finding consistent with our study. Other complications were perforation, descmetocele, anterior staphyloma, Lixin Xie et al found that 7.0% had corneal perforation and 5.5% had endophthalmitis [39-42].

Filamentous septate fungi were the most common cause for fungal ulcer which was consistent with findings of Ula Jurkunas et al who found filamentous fungi in 65% cases and yeast in 35 % of their cases of fungal keratitis. Majority of patients had presenting visual acuity up to 1/60 and factors affecting visual acuity were age > 40 years, presenting after 7 days, topical steroid use, TEM use, central ulcer, presence of hypopyon, filamentous septatae fungi infection.

Lalitha P et al also found that predictors of treatment failure in fungal keratitis were ulcers that exceeds 14mm<sup>2</sup> ( $p=0.009$ ), presence of hypopyon ( $p=0.003$ ) and those infected with *Aspergillus* (0.003) [43]. Pranja NV et al found that predictors for worse 3- months visual acuity include older age ( $p=0.024$ ), worse presentation visual acuity ( $p < 0.001$ ) [44-45], larger infiltrate size at presentation ( $p < 0.001$ ) and pigmented ulcer ( $p=0.030$ ). Larger infiltrate size at presentation was a significant predictor of worse 3 - month infiltrate/scar size ( $p < 0.001$ ), larger epithelial defect was a significant predictor of perforation( $p=0.003$ ). This study shows there are many other factors which affect prognosis of fungal keratitis which we did not include and forms a limitation of our study.

An increase has been in number and severity of presentation of fungal keratitis cases, This can be attributed to facts that; most of the people here are from rural area and are engaged in agricultural activity, delay in presentation of cases as symptoms are less as compared to signs, ignorance and lack of education in patients, treatment from local practitioners, injudicious use of topical steroid and self-medications.

Thus adequate protection during outdoor activities, minimization of topical steroids / TEM use, early institution of appropriate antifungal therapy are practical means to reduce burden of visual impairment due to fungal keratitis.

On analyzing factors predictive for visual outcome, location of the ulcer, age, steroid drop instillation, hypopyon were the factors that reached statistical significance. Eyes with central corneal ulcers were found to have an increased risk of visual loss compared to peripheral and paracentral ulcers. Delay in presentation (> 7 days) was also associated with visual loss, this also attained statistical significance ( $P < 0.05$ ). TEM use was also associated



with poor visual outcome but did not attain statistically significant value.

In conclusion, this study highlights the relative importance of different factors affecting visual outcomes in fungal keratitis. This study also gave different demographical factors associated with fungal keratitis. More research needs to be done on fungal keratitis to find other risk factors and to decrease burden of complications. It would be valuable to compare the efficacy of newer antifungal agents with broader spectrum like Voriconazole with traditional polyene antifungals like Nystatin for fungal keratitis alone to assess outcomes in fungal keratitis associated with different risk factors.

## REFERENCES

- Upadhyay MP, Karmacharya PC, Koirala S, et al. Epidemiologic characteristics, predisposing factors, and etiologic diagnosis of corneal ulceration in Nepal. *Am J Ophthalmol* 1991;111:92-9.
- Gonzales CA, Srinivasan M, Whitcher JP, et al. Incidence of corneal ulceration in Madurai District, south India. *Ophthalmic Epidemiol* 1996;3:159-66.
- Whitcher JP, Srinivasan M, Upadhyay MP. Corneal blindness: a global perspective. *Bull World Health Organ* 2001;79:214-21.
- Dunlop AAS, Wright ED, Howlader SA, et al. Suppurative corneal ulceration in Bangladesh. *Aus NZ J Ophthalmol* 1994;22:105-10.
- Thomas PA. Mycotic keratitis—an underestimated mycosis. *J Med Vet Mycol* 1994;32:235-56.
- Hagan M, Wright E, Newman M, et al. Causes of suppurative keratitis in Ghana. *Br J Ophthalmol* 1995;79:1024-8.
- Srinivasan M, Gonzales CA, George C, et al. Epidemiology and etiological diagnoses of corneal ulceration in Madurai, south India. *Br J Ophthalmol* 1997;81:965-71.
- Panda A, Sharma N, Das G, et al. Mycotic keratitis in children: epidemiologic and microbiologic evaluation. *Cornea* 1997;16:295-9.
- Khanal B, Kaini KR, Deb M et al. Microbial keratitis in eastern Nepal. *Tropical Doctor* 2001;31:168-9.
- Foster CS. Fungal keratitis. *Infect Dis Clin N Am* 1992;6:851-7.
- Gugani HC, Talwar RS, Njoku-Obi AN, et al. Mycotic keratitis in Nigeria. A study of 21 cases. *Br J Ophthalmol* 1976;60:607-13.
- Thomas PA, Kalavathy CM, Rajasekaran J. Microbial keratitis—a study of 774 cases and review of the literature. *J Madras State Ophthalmic Assoc* 1986;23:13-21.
- Deshpande SD, Koppikar GV. A study of mycotic keratitis in Mumbai. *Indian J Pathol Microbiol* 1999;42:81-7.
- Garg P, Gopinathan U, Choudhary K, et al. Keratomycosis: clinical and microbiologic experience with dematiaceous fungi. *Ophthalmology* 2000 107:574-80.
- Jones DB. Initial therapy of suspected microbial corneal ulcers. II. Specific antibiotic therapy based on corneal smears. *Surv Ophthalmol* 1979;24:97, 105-61.
- Kunimoto DY, Sharma S, Garg P, et al. Corneal ulceration in the elderly in Hyderabad, south India. *Br J Ophthalmol* 2000;84:54-9.
- Coster DJ, Wilhelmus J, Peacock J, et al. Suppurative keratitis in London. The cornea in health and disease. Vth Congress of the European Society of Ophthalmology 1981;40:395-8.
- Neumann M, Sjostrand J. Central microbial keratitis in a Swedish city population. A three-year prospective study in Gothenburg. *Acta Ophthalmol (Copenh)* 1993;71:160-4.
- Liesegang TJ, Forster RK. Spectrum of microbial keratitis in south Florida. *Am J Ophthalmol* 1980;90:38-47.
- Rosa RH, Miller D, Alfonso EC. The changing spectrum of fungal keratitis in south Florida. *Ophthalmology* 1994;101:1005-13.
- Tanure MA, Cohen EJ, Sudesh S, et al. Spectrum of fungal keratitis at Wills Eye Hospital Philadelphia, Pennsylvania. *Cornea* 2000;19:307-12.
- Titiyal, York MK, Church DL. Ocular Cultures. In: Garcia LS, Isenberg HD (Eds). *Clinical Microbiology Procedure Handbook*, 3rd ed. Washington: ASM Press, 2011;3.10.1-3.10.9.
- Titiyal, Allen SD, Janda WM, Schereckenberger BC, Winn WC. *Color Atlas and Text Book of Diagnostic Microbiology*, 6th ed. Philadelphia: Lippincott Publishing, 2006:124-46.
- Houang. Ocular infections due to anaerobic bacteria. *Int Ophthalmol* 2001;24:269-77.
- Lixin Xie, Stapleton F, Edwards K, Keay L, et al. Risk factors for moderate and severe microbial keratitis in daily wear contact lens users. *Ophthalmology* 2012;119:1516-21.
- Lixin Xie, Kosoko A, Vu Q, Kosoko-Lasaki O. Chemical ocular burns: A case review. *Am J Clin Med* 2009;6:41-9.
- M. Jayahar, Ioannidis AS, Zagora SL, Wechsler AW. A non-healing corneal ulcer as the presenting feature of type I diabetes mellitus: a case report. *J Med Case Rep* 2011;5:539.
- M. Jayahar, Therese KL, Anand AR, Madhavan HN. Polymerase chain reaction in the diagnosis of bacterial endophthalmitis. *Br J Ophthalmol* 1998;82:1078-82.
- M. Jayahar, Stellrecht KA, Woron AM, Mishrik NG, Venezia RA. Comparison of multiplex PCR assay with culture for detection of genital mycoplasmas. *J Clin Microbiol* 2004;42:1528-33.
- M. Jayahar, Huq M, Gonis G, Istivan T. Development and evaluation of a multiplex PCR for the detection of *Campylobacter concisus* and other *Campylobacter* spp. from gastroenteritis cases. *Open J Med Microbiol* 2014;4:29-37.
- Lixin Xie, Achermann Y, Vogt M, Leunig M, Wüst J, Trampuz A. Improved diagnosis of periprosthetic joint infection by multiplex PCR of sonication fluid from removed implants. *J Clin Microbiol* 2010;48:1208-14.
- Bastola P, Reema nath, M jayahar, Bourcier T, Borderie V, Laroche L. Late bacterial keratitis after implantation of intrastromal corneal ring segments. *J Cataract Refract Surg* 2003;29:407-9.
- Bastola P, Reema nath, M jayahar, Brook I. Ocular infections due to anaerobic bacteria in children. *J Pediatr Ophthalmol Strabismus* 2008;45:78-84.
- Kelly LD, Gaynon M. *Bacteroides fragilis* endophthalmitis: a case report. *Can J Ophthalmol* 1990;25:208-9.
- Gangopadhyay N, Daniell M, Weih LA, Taylor HR. Fluoroquinolone and fortified antibiotics for treating

- bacterial corneal ulcers. *Br J Ophthalmol* 2000;84:378-84.
36. Bastola P, Reema nath , M jayahar ,Brook I. Management of anaerobic infections. *Exper Rev Anti-infect Ther* 2004;2:153-8.
  37. Bastola P, Bertino JS. Impact of antibiotic resistance in the management of ocular infections: the role of current and future antibiotics. *Clin Ophthalmol* 2009;3:507-21.
  38. Stein GA, Goldstein EJ. Fluoroquinolones and anaerobes. *Clin Infect Dis* 2006;42:1598-607.
  39. Wybo I, Van den Bossche D, Soetens O, et al. Fourth Belgian multicentre survey of antibiotic susceptibility of anaerobic bacteria. *J Antimicrob Chemother* 2014;69:155-61.
  40. Eitel Z, Sóki J, Urban E, Nagy E, ESCMID Study Group on Anaerobic Infection. The prevalence of antibiotic resistance genes in *Bacteroides fragilis* group strains isolated in different European countries. *Anaerobe* 2013;21:43-9.
  41. Gonawardena SA, Ranasinghe KP, Arseculeratne SN, et al. Survey of mycotic and bacterial keratitis in Sri Lanka. *Mycopathologia* 1994;127:77-81.
  42. Imwidthaya P. Mycotic keratitis in Thailand. *J Med Vet Mycol* 1995;33:81-2.
  43. Lalitha P, Wong TY, Fong KS, Tan DTH. Clinical and microbial spectrum of fungal keratitis in Singapore: a 5-year retrospective study. *Int Ophthalmol* 1997;21:127-30.
  44. Houang E, Lam D, Fan D, et al. Microbial keratitis in Hong Kong: relationship to climate, environment and contact-lens disinfection. *Trans R Soc Trop Med Hyg* 2001;95:361-7.
  45. Pranja NV, De Hoog GS, Guarro J, Gené J, et al. Atlas of clinical fungi. 2nd ed. 2000:30-5.