

A comparative study on pterygium excision and glue free limbal conjunctival autograft with and without suture

Shadakshari S.M

Consultant, Dept. of Ophthalmic, Rotary Hospital, Sirsi

***Corresponding Author:**

Email: drshadakshari1976@gmail.com

Abstract

Aim: A comparative study on pterygium excision and glue free limbal conjunctival autograft with and without suture.

Materials and Methods: 50 patients of primary nasal pterygium attending ophthalmology OPD in Rotary Hospital, Sirsi, Karnataka were randomly selected. The study was conducted during the period from June 2015 to January 2016.

All patients were divided randomly into two groups. Group 1 consisted of 25 patients who underwent suture less, glue free limbal conjunctival autograft and Group 2 consisted of 25 patients who underwent limbal conjunctival autograft with suturing.

Clinical data of all patients which included age, sex, laterality of pterygium as well as a history of other diseases, were obtained by reviewing the medical records and direct patient interview.

All patients were subjected to detail comprehensive ophthalmic examination which included visual acuity, refraction, slit lamp biomicroscopy, measurement of IOP, extra ocular movements and dilated funduscopy.

Results: In this study 50 primary nasal pterygium who underwent Surgery were assessed. Of 50 patients, 35 were male and 15 were female patients. The age of patients ranged from 30 years to 65 years. In our study mean Surgical time in Group A (n=25) was 20±1.5 min. as compared to Group B (n=25) which was 30±2 min. Early post-operative signs and symptoms like pain, foreign body sensation, hyperemia and chemosis were significantly less in Group A as compared to Group B. There was no significant difference in complication rate seen among to group except for graft retraction which was seen in Group A. Both groups achieved good visual acuity after 4 weeks. Both groups had no recurrence of pterygium.

Conclusion: Among the two techniques Suture less and glue free limbal conjunctival autograft is easy to perform and it is safe, effective and economical.

Keywords: Limbal conjunctival autograft, Pterygium excision, Suture.

Introduction

Pterygium is a common ocular surface growth disorder originating in the conjunctival and extending to the cornea.⁽¹⁾ its incidence range from 0.7% to 31%.^(2,3) The standard treatment of pterygium is surgical excision, but the recurrence rate after surgery can be as high as 24% to 89%, which comprises outcome⁽⁴⁾ localized limbal stem cell deficiency is thought as a causative factor for pterygium formation.⁽⁵⁾

Simple excision is associated with high rate of recurrence. Numerous techniques aimed at preventing recurrence have been described. Currently the most widely used technique involves excision of the pterygium and covering the defect with either a conjunctival graft or amniotic membrane.⁽⁶⁾ Pterygium excision associated with autologous conjunctival graft is currently the most effective method to treat pterygium do to its low rate of recurrence.⁽⁷⁾

Materials and Methods

In our study we included 50 eyes of 50 patients having primary nasal pterygium to attended the ophthalmology opd in Rotary hospital, Sirsi, Karnataka between January 2016 to June 2016.

Inclusion Criteria: Patients who presented with primary nasal pterygium in all age groups and either sex.

Exclusion Criteria: Those unable to complete 6 months follow up, recurrent pterygium, pseudo-ptyerygium, ocular surface pathology, infection, previous limbal surgery, preexisting glaucoma, retinal pathology requiring surgical intervention.

All patients underwent a comprehensive ophthalmic examination including visual acuity, refraction, Slit lamp biomicroscopy, measurement of IOP, extra ocular muscle movements & dilated funduscopy.

We divided all patients in to two groups. Group 1 consisted of 25 eyes who underwent sutureless and glue free limbal conjunctival Auto graft and Group 2 consisted of 25 eyes who underwent free limbal conjunctival autograft with suturing.

Surgical technique: Local anaesthesia in the form of peribulbar using 2% lignocaine and 0.5% bupivacaine in 1:1 ratio was administered to all patients. Using crescent blade the head of the pterygium was dissected along with the body, its limbal attachment was carefully pterygium dissected out down upto 4mm from limbus. Subsequently, the Sub conjunctival pterygium tissue and the thickened segment of conjunctival and adjacent tenon capsule were excised leaving bare sclera. Caution was avoided. The graft was taken from superior temporal quadrant. The size of which was 1mm more than the recipient bed. The graft was properly rotated and placed over the recipient bed with epithelial side up. Firm pressure was applied to the graft for few minutes and for

the patients included in group 2 along with the above procedure 8-0 vicryl sutures were applied to all 4 corners. Antibiotic drops and ointment was placed and the eye bandaged. Post-operatively all patients were given antibiotic – steroid drops and topical lubricant drops for 4 weeks with tapering dose. All patients were examined post-operatively on 1st day, 1st week, 2nd week, 4th week, 3rd month and 6th month. Respectively. Patients completed a questionnaire at each follow-up visit grading for pain, foreign body sensation, hyperemia and chemosis into 4 grades according to intensity. The questionnaire were scored for (0 – 3) 0 – nothing, 1-mild, 2-moderate, 3-severe. Surgical time was noted in both groups. The main post-operative outcome noted were recurrence rate, graft dehiscence, graft retraction and gain in vision.

Statistical Analysis: Unpaired t test is applied to find the difference between average surgical time between two groups. And chi square test was applied to find the significant difference between complications between two groups.

Results

In our study we included 50 eyes of 50 patients among them 35 were male patients and 25 were female patients. All patients age ranged from 30 years to 65 years.

Table 1

	Group A (n = 25)	Group B (n = 25)
Range of Age and mean	30-65 years	33-64 years
mean	47.5	48
Sex		
male	18	17
Female	14	11
Laterality		
Right	13	15
Left	12	10

The demographic profile of the patient is summarized in Table 1.

The average surgical time for Group A was 20±1.5minutes and for group B was 30± 2 minutes (P value).

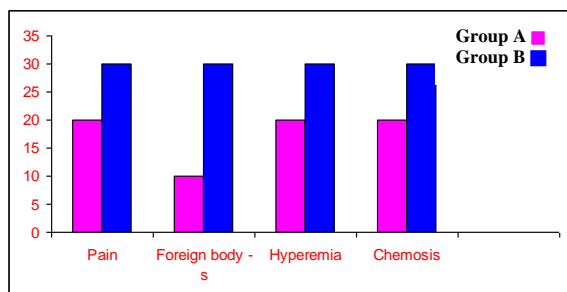


Fig. 1: Showing 1st day post-operative signs and symptoms in Group A and Group B

There is no significant difference between group A and Group B (P=0.3834)

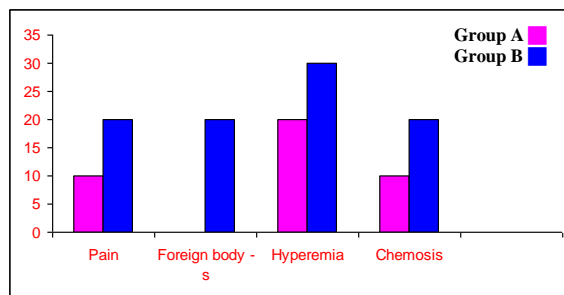


Fig. 2: showing 1st week post-operative signs and symptoms in Group A and Group B.

There is a significant difference between group A and group B. (P=0.0113)

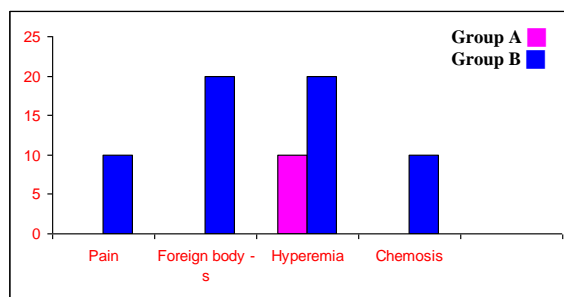


Fig. 3: Shows post-operative signs and symptoms at 2nd week in both groups

There is significant difference between group A and group B. (P=0.0014)

At 4th week post operatively both groups had satisfactory signs and symptoms.

Table 2

	Group A	Group B	P value
Average surgical time	20 ± 1.5 min	30 ± 2 min	
Complication Rate			
Graft edema	2	4	
Graft dehiscence	1	0	
Graft retraction	3	1	
Recurrence Rate	0	0	

Above Table shows comparison of Average surgical time and complication rate between 2 groups

There was no significant difference in visual outcome in both groups after 4th week post operatively.

Discussion

There are different surgical techniques for managing pterygium. The main aim of pterygium surgery should be pterygium excision and preventing its recurrence. Generally, the pterygium recurs within the first six months after surgery.⁽⁸⁾

The average surgical time in our study was comparable to the study by Ashok Sharma et al which showed in group 1 (23 ± 1.55) and group 2 (37 ± 1.89) minutes.

Post-operative sings and symptoms that occurred in Group 1 and Group 2 in our study can be compared to the results seen in the study conducted by Elwan.⁽⁹⁾ The symptoms were maximum on day 1 and gradually disappeared within 2 weeks in Group 1 and within 4 weeks and Group 2.⁽¹⁰⁾

Post-operative symptoms were also reported more with suture and less with sutureless autograft by various authors.⁽¹¹⁻¹²⁾

Post-operative complication seen in our study can be compared to the study conducted by Ashok Sharma et al.⁽¹³⁾

Table 6

	Group 1	Group 2	P value
Average surgical time	23 ± 1.55 min	37.76 ± 1.89 min	0.001
Complication Rate			
Graft edema	2	3	NS
Recurrence Rate	0	1	NS
Conjunctival granuloma	0	1	NS

Above table shows average surgical time and post-operative complication seen in study conducted by Ashok Sharma et al.⁽¹³⁾

Conclusion

Among the two techniques Suture less and glue free limbal conjunctival autograft is easy to perform and it is safe, effective and economical.

References

1. Hirst LW, Recurrent pterygium surgery using pterygium extended removal followed by extended conjunctival transplantation: recurrence rate and cosmesis. *ophthalmology*. 2009;116:1278-86.
2. Shiroma H, Higa A, Sawaguchi S, Iwase A, Tomidokoro A, Amano S, Araie M. Prevalence and risk factors of pterygium in south western island of Japan; the kumejima study. *Am J ophthalmol* 2009;148:766-71.
3. Srinivasa S, Dollin M, Mc Allum P, Berger Y, Rootman DS, Slomovic AR. Fibrin glue Versus Suture for attaching the conjunctival autograft in pterygium surgery; a prospective observer masked clinical trial. *Br J ophthalmol* 2009;93:215-8.
4. Xu Y, Zhou HM, Li J, Ke BL, Xu X. Efficacy of treatment for pterygium by autologous conjunctival transplantation and mitomycin C. *chin Med J (Engl)* 2012;125:3730-4.

5. Tseng SCG. Concept and application of limbal stem cells. *Eye*. 1989;3:141-57.
6. Jack J Kanski. *Clinical ophthalmology* 5th edn; 2003.83.
7. Malik KP, Goel R, Gupta A, Gupta SK, Kamal S, Malik VK, Singh S. Efficacy of Sutureless and glue free limbal conjunctival autograft for primary pterygium surgery. *Nepalese Journal of ophthalmology* 2012 Jul 25;4(2):230-5.
8. Starck T, Kenyon KR, Serrano F. conjunctival autograft for primary and recurrent pterygia: surgical technique and problem management *cornea* 1991;10:196-202.
9. Elwan sam. comparison between sutureless and glue free versus sutured limbal conjunctival autograph in primary pterygium surgery. *Saudi journal of ophthalmology* 2014;28:292-298.
10. Wit D, Athanasiadis I, sharma A, Moore J, Sutureless and glue free conjunctival autograft in pterygium surgery. *A case Series Eye* 2010;24:1474-77.
11. Adamis AP, Starck T, Kenyon KR. The management of pterygium. *ophthalmol clin north Am* 1990;3:611-23.
12. Yelksel B, Unsal SK, onat S, comparison of Fibrin glue and suture technique in pterygium surgery performed with limbal autograph. *Int J ophthalmol* 2010;3:316-20.
13. Ashok Sharma, Hans Raj, Aditi Gupta and Amit vikram Raina. Sutureless and glue free versus Suture for limbal conjunctival autografting in primary pterygium surgery. A prospective comparative study. *J Clin Diagn Res*. 2015 Nov;9(11):NC 06- NC 09.