

Clinical profile of herpes simplex viral keratitis cases attending eye opd in tertiary hospital of Chhattisgarh state

Abha Sinha^{1,*}, Somya Dulani²

¹Assistant Professor, ²Professor & HOD, Dept. of Ophthalmology, Govt. Medical College, Rajnandgaon

***Corresponding Author:**

Email: dhiraj.bhawnani@gmail.com

Abstract

Introduction: Herpes simplex viral keratitis is a very common infective disease in western countries. Despite the availability of excellent topical antiviral agents, HSV remains a leading cause of unilateral corneal blindness in the United States and in all developed countries. Primary infection usually occurs in early life, & may be asymptomatic, but the real danger lies in the virus ability to establish latency in the neuronal ganglia & reactivation. This reactivation is an immune phenomenon which can lead to progressive corneal damage, as recurrences may be multiple & severe, ultimately causing corneal scarring, vascularisation, thinning & even perforation.

Materials & Methods: The present prospective study was carried out on 100 eyes involving 80 patients of viral involvement of cornea, who presented to Department ophthalmology, Government Medical College, Rajnandgaon (C.G.), India, during the period from March 2016 to February 2017. To study for the precipitating factors, age & sex distribution, laterality, different types of lesions, complications & recurrences, detailed history of each case was taken & examined thoroughly. Ocular examination with slit lamp was carried out thoroughly. Fluorescein staining was also done in each case. All diagnosis was made clinically.

Observations: Majority (62.5%) of patients belonged to 20 to 40 years followed by 18.75% of patients in 40 to 50 years age group. No cases were seen under 10 years age group in present study. Males were more commonly affected than females by 57.5%. In present study at first presentation onset of disease was spontaneous in 58.75%. In rest of the cases major precipitating factors were history of minor ocular trauma, fever, stress, exanthematous skin eruptions & UV light. Bilateral herpetic keratitis was found in 25% patients in present study. In present study epithelial keratitis was most common lesion (60% cases) found followed by stromal keratitis (23% cases). Among patients of epithelial keratitis, superficial punctate keratitis (42% cases) was most common, followed by dendritic keratitis (11% cases) & geographic ulcer (7% cases).

Conclusion: HSV keratitis is a major cause of unilateral blindness. Early diagnosis & management could restrict disease progression.

Keyword: HSV, Epithelial keratitis, Stromal keratitis.

Introduction

Herpes simplex viral keratitis is a very common infective disease in western countries. It has been estimated that nearly 500,000 people in the USA are affected with ocular HSV.⁽¹⁾

Despite the availability of excellent topical antiviral agents, HSV remains a leading cause of unilateral corneal blindness in the United States and in all developed countries.⁽²⁾ Primary infection usually occurs in early life, & may be asymptomatic, but the real danger lies in the virus ability to establish latency in the neuronal ganglia & reactivation.⁽³⁾ This reactivation is an immune phenomenon which can lead to progressive corneal damage, as recurrences may be multiple & severe, ultimately causing corneal scarring, vascularisation, thinning & even perforation.⁽⁴⁾

The frequency of incidence has become much greater in developing countries like India because of improved socioeconomic status and following indiscriminate wide spread use of antibiotics and corticosteroids. There is paucity of data regarding clinical profile of H.S.V. keratitis cases in our region so in present study attempts was made to show the incidence, age and sex distribution, precipitating causes, laterality, different type of lesions, complications and recurrences of HSV keratitis in our hospital.

Materials & Methods

The present prospective study was carried out on 100 eyes involving 80 patients of viral involvement of cornea, who presented to Department of ophthalmology, Government Medical College, Rajnandgaon (C.G.), India, during the period from March 2016 to February 2017.

To study for the precipitating factors, age & sex distribution, laterality, different types of lesions, complications & recurrences, detailed history of each case was taken & examined thoroughly. Ocular examination with slit lamp was carried out thoroughly. Fluorescein staining was also done in each case. All diagnosis was made clinically.

Cases were followed up to know for recurrences and visual morbidity. Daily follow ups were done for the first three days and then on 5th, 10th and 14th day & every one month for three months & thereafter at 6 month & one year. In each follow ups, patients were examined for the absence of fluorescein staining & disappearance of clinical symptoms. Superficial Punctate Keratitis was diagnosed as numerous white plaques on cornea arranged in rows or groups, which after desquamation stained with fluorescein staining. Cases presenting with branching linear lesions with terminal bulbs & swollen epithelial borders were diagnosed as dendritic keratitis,

which stains positive for fluorescein along the length of the lesions & ulcer border stains positive for Rose Bengal. Patients diagnosed as geographic ulcer presented with broad area of epithelial involvement with irregular angulated borders. Cases presenting with central zone of stromal edema often with an overlying epithelial oedema with or without KP were diagnosed as disciform keratitis. Patients of necrotizing stromal keratitis presented with stromal necrosis & melting with profound interstitial opacification & epithelial defect. Cases found to have diffuse infiltration of deep layers of corneal stroma with loss of corneal sensation and in absence of other causes of keratitis were diagnosed as stromal keratitis. Clinical diagnosis of endothelitis was made in the presence of mild stromal edema, medium sized KP, aqueous flare and cells. Patients presenting with significant corneal edema with marked signs of anterior uveitis were diagnosed as keratouveitis. Neurotrophic ulcer was diagnosed in patients with persistent central epithelial defects with grey thickened border.

Data was compiled in MS Excel and checked for its completeness and correctness. Then it was analyzed.

Observations

It was observed that among the patients who visited the OPD during the study period 0.55% (1 in 182) of the patients were suffering from HSV Keratitis. Observations have been made regarding herpes simplex keratitis as follows:-

Table 1: Age & Sex distribution

Age Group (Yrs.)	Males	Females	Total	%
1-10	0	0	0	0
11-20	7	2	9	11.25
21-30	20	7	27	33.75
31-40	18	5	23	28.75
41-50	12	3	15	18.75
51-60	6	0	6	7.5
Total	63	17	80	100

As per the age & sex distribution that has been shown in the Table 1, maximum number (62.5%) of patients belonged to 20 to 40 years followed by 18.75% of patients in 40 to 50 years age group. No cases were seen under 10 years age group in present study. (Table 1)

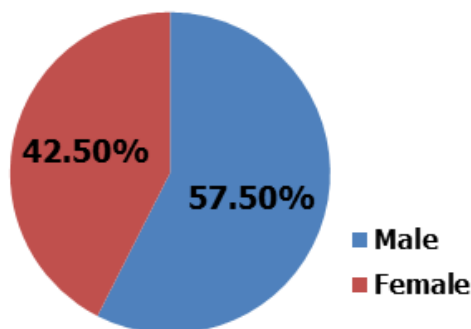


Fig. 1: Gender wise distribution of subjects

In present study males were more commonly affected than females by 57.5%. (Fig. 1)

Table 2: Precipitating factors

Precipitating Cause	No. of Cases	Percentage
Spontaneous	47	58.75
Minor Ocular Trauma	8	10
Fever	14	17.5
Stress	7	8.75
Exanthematous Skin Eruptions	2	2.5
U.V. Light	2	2.5
Total	80	100

In present study at first presentation onset of disease was spontaneous in 58.75%. In rest of the cases major precipitating factors were history of minor ocular trauma, fever, stress, exanthematous skin eruptions & UV light. (Table 2)

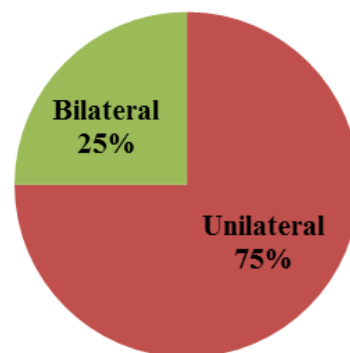


Fig. 2: Nature of herpetic keratitis

Bilateral herpetic keratitis was found in 25% patients in present study. (Fig. 2)

Table 3: Different type of lesions

Type of lesions	No. of eyes	%
Superficial Punctate Keratitis	42	42
Dendritic Keratitis	11	11
Geographic Ulcer	7	7
Disciform Keratitis	22	22
Necrotizing Stromal Keratitis	1	1
Endothelitis	8	8
Keratouveitis	5	5
Neurotrophic Ulceration	4	4
Total	100	100

Above table shows the different types of lesions of HSV Keratitis in patients studied. In present study epithelial keratitis was most common lesion (60% cases) found followed by stromal keratitis (23% cases). Among patients of epithelial keratitis, superficial punctate keratitis (42% cases) was most common, followed by

dendritic keratitis (11% cases) & geographic ulcer (7% cases). (Table 3)

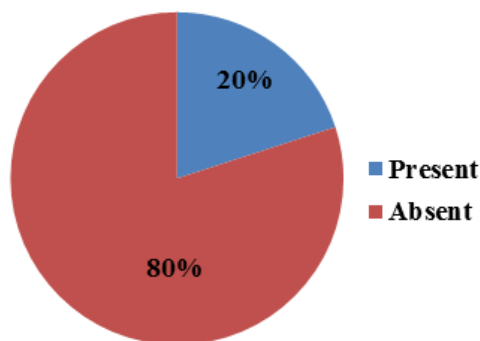


Fig. 3: Recurrence of disease

During follow up period, recurrence rate was found in 20% of cases. Among them 12% were of stromal keratitis & 8% of epithelial keratitis. Epithelial keratitis recurred as either epithelial or stromal. Stromal keratitis recurred as only stromal. Average interval of recurrence from first presentation was 6 months to 1 year in present study. (Fig. 3)

Complications – Complications were less. Among endothelitis cases 3 cases, (37.5%) showed elevated intraocular pressure. 7.4% cases developed persistent corneal opacity.

Discussions

In the current study, 0.55% (1 in 182) was suffering from HSV keratitis, while Janker gave an incidence of 1:250 of all ophthalmic patients.⁽⁵⁾

There is a rising trend of its occurrence in developing countries like India. The rise may be due to early diagnosis & improved treatment & injudicious use of steroids.

In present study, maximum number of patients belonged to 20-40 yrs. of age group, which was similar to other study done.⁽⁶⁾

Bilaterality: Bilateral herpetic keratitis was found in 25% patients in present study. While in a series of 356 patients followed over 30 years in Japan, bilateral keratitis was found in 9.4%.⁽⁷⁾ Increased bilateral cases may be due to overall increased incidence of the disease. Bilateral cases are mainly epithelial which matches with other study.⁽⁷⁾

Precipitating causes: In 58.75% cases, onset was spontaneous, while in rest of the cases some precipitating causes were found i.e. fever, stress, history of minor ocular trauma, UV light. Wilhelmus KR⁽⁸⁾ in their study also found that recurrences are triggered by fever, hormonal changes, ultraviolet radiation, stress & ocular trauma.

Type of lesions – In present study most common type of lesion found was epithelial keratitis (60%), followed by stromal keratitis (23%), endothelitis (8%), keratouveitis (5%), and neurotrophic ulcer (5%).

Promol NP et al also reported in his study, most common type of lesion being epithelial keratitis followed by stromal keratitis.⁽⁹⁾ Among epithelial keratitis, most common lesion found was superficial punctate keratitis (42%), where as it was dendritic keratitis in their study. The low incidence of dendritic keratitis in present study may be due to early diagnosis & immediate treatment being given to a patient.

KV Raju et al in their study also reported similar incidence of epithelial keratitis, with superficial punctate keratitis (35.6%) being the most common, matching with that of present study.⁽¹⁰⁾

In present study, among patients of stromal keratitis, disciform keratitis was found in 22% & necrotizing stromal keratitis was found in 1% which is comparable to other studies.^(9,10)

Recurrences & complications: Recurrences pattern & complications of present study matches with study done by KV Raju et al.⁽¹⁰⁾

Conclusion

HSV keratitis is a major cause of unilateral blindness. There is rising trend of its occurrence in developing countries like India. Diagnosis is mainly clinical. Careful evaluation & appropriate management could restrict corneal damage & reduce incidence of severe visual loss.

Acknowledgements

The authors would like to thank all the faculty and technical staff members of the Department of Ophthalmology, Government Medical College, Rajnandgaon (C.G.), India for their immense cooperation and support during the entire study period.

Funding: No funding sources

Conflict of interest: None declared

Ethical approval: The study was approved by the Institutional Ethics Committee.

References

1. Lairson DR, Beqrey CE, Reynolds TF, Wilhelmus KR. Prevention of herpes simplex virus eye disease. A cost effectiveness analysis. Arch ophthalmol 2003;121:108-112.
2. Darougars, Wishart MS, Viswalingam ND, Epidemiological & Clinical features of primary herpes simplex virus ocular infection. Br. J Ophthalmol, 1985;69(1):26.
3. Rolinski J, HUSI, Immunological aspects of acute & recurrent herpes simplex keratitis. J Immunol Res. 2014;2014:513-560.
4. Kaufman HE, Azcuy AM, Varnell ED, Sloop GD, Thompson HW, Hill JM, HSV-1 DNA in tears & saliva of normal adults. Invest Ophthal Vis Sci 2005;46(1):241-7.
5. Janker GH, 1962, Ophthalmologica;144:405.
6. AK Khurana, HR Gutain, IPS Parmar (1984), IJO Vol32, issue-4:205-208.
7. Uchio E, Hatano H, Mitsuk et al. A retrospective study of herpes simplex keratitis over the last 30 years.

8. Wilhelmus KR, Epidemiology of ocular infections, In Baum J, Liesegang TJ, eds. Duane's Foundations of Clinical Ophthalmology, Vol2, Philadelphia: Lippincott Williams & Wilkins, 1998:1-46.
9. Pramod NP, Rajendra P, Kannan KA et al. Herpes simplex in South India, Clinico-virological correlation, Jpn J Ophthalmol 1999, 43:303-7.
10. KV Raju, Jyothi PT, Shimna Iqbal, Clinical Profile of herpes simplex keratitis, K J of Ophthalmology, Vol XXIII, No.1, Mar 2011:33-37.