

Analysis of various risk factors in the development of retinopathy of prematurity in semi urban population

Sangamithira Mathiyalagan^{1,*}, Helen Rosita²

¹Assistant Professor, ²Senior Assistant Professor, Dept. of Ophthalmology, Thanjavur Medical College, Thanjavur

***Corresponding Author:**

Email: sangamithrasenthil@gmail.com

Abstract

Background: Retinopathy of prematurity (ROP) is a disease of the eye that generally affects premature babies receiving intensive neonatal care. It is thought to be due to disorganized growth of retinal blood vessels which results in scarring and retinal detachment. Mild ROP resolves spontaneously but serious cases may lead to blindness. All preterm babies are at risk for ROP, and very low birth weight is an additional risk factor. Development of ROP is contributed to by both oxygen toxicity and relative hypoxia.

Aim: To determine the frequency of occurrence of retinopathy of prematurity and to determine possible risk factors that contribute to the development of retinopathy of prematurity in a study population of preterm babies drawn from a semiurban population.

Materials and Methods: Prospective one year study, with 102 babies who satisfied the inclusion criteria were subjected to complete fundus examination with indirect ophthalmoscope and followed up till 45 week of post conceptional age.

Results: The prevalence of ROP was calculated to be 36.2% in the current study. Early preterm babies (85.7%, p=0.0002), extremely low birth weight babies (100%, p=0.00003), respiratory distress syndrome (44.3%, p=0.004), blood transfusion to babies (71.4%, p=0.002), oxygen therapy through continuous positive airway pressure (90.9%, p=0.003) and oxygen therapy through ventilator (100%, p=0.0001) were emerged as independent risk factors for the development of ROP

Conclusion: In India, ROP is emerging as a leading cause of preventable childhood blindness. The word 'preventable' suggests that there exists an effective treatment which helps to prevent disease progression. Timely screening and early management is the key for the management of ROP.

Keywords: Blindness, Gestational age, Low birth weight, Retinopathy of prematurity, Screening.

Introduction

Retinopathy of prematurity (ROP) is a disease that generally affects premature babies who are receiving intensive neonatal care. It is due to disorganized retinal blood vessels growth which leads to scarring and retinal detachment.⁽¹⁾ Mild ROP resolves spontaneously but severe ROP will to blindness. All preterm babies are at risk for ROP and additional risk factor is very low birth weight. Both oxygen toxicity and relative hypoxia will contribute to the development of ROP. Globally, the incidence of blindness in childhood is about 1.4 million of which 40% is preventable.⁽²⁾ Recently there is an increase in occurrence of ROP due to improvement of neonatal care and increased survival rate of low birth weight preterm babies. The key for the management of ROP is timely screening and early management. To determine the possible risk factors for the development of retinopathy of prematurity and to determine the frequency of occurrence of retinopathy of prematurity in a study population of preterm babies drawn from a semi urban population.

Materials and Methods

This prospective, observational one year study was done from January 2016 to December 2016, at the Department of Ophthalmology, Thanjavur Medical College, Thanjavur with 102 babies who satisfied the inclusion criteria were subjected to complete fundus

examination with indirect ophthalmoscope and followed up till 45 weeks of postconceptional age.

Inclusion Criteria:

- Gestational age at birth of ≤ 36 weeks
- Birth weight of ≤ 2500 g

Exclusion Criteria:

- Term infants.
- Infants who were lost to follow up.

The prenatal risk factors were divided per birth weight⁽³⁾ into extremely low birth weight (ELBW) with birth weight less than 1000g, very low birth weight (VLBW) with birth weight between 1000-1499 g, low birth weight (LBW) with birth weight between 1500 - 2499g. According to gestational age group, the babies were divided into early preterm with 26 to 31 weeks of gestational age, moderate preterm with 32 to 34 weeks of gestational age, late preterm with 35 to 36 weeks of gestational age group.

All babies were screened at 26 weeks of gestational age or four weeks of chronological age whichever was later.⁽⁴⁾ The antenatal details birth details and treatment details of the babies were recorded in the ROP proforma.

Mixture of phenylephrine 2.5% and tropicamide 0.5% was used for dilatation. The retinal examination was done with indirect ophthalmoscope and 20 D lens. The international classification (ICROP) was used to document all retinal examination findings.⁽⁵⁾ Those

babies with ROP were given further appointments depending upon the stage of ROP and zone of the disease.⁽⁶⁾ Follow-up examinations recommended by American Academy of Pediatrics (AAP) guidelines are 1 week follow up for babies with stage 1 or 2 ROP in zone 1, for regressing ROP in zone 1, stage 2 ROP in zone 2 and for stage 3 ROP in zone 3. Two week follow up for babies with stage 1 ROP in zone 2 and for regressing ROP in zone 2. Three weeks follow up for babies with stage 1 or 2 in zone 3 and for regressing ROP in zone 3. Screening was continued till complete vascularization. SPSS software was used for statistical analysis.

Results

In our study, 102 babies were totally screened for ROP. Out of this, 37 babies had ROP (Fig. 1). In this study the prevalence was 36.2%. ROP was found to be present in 20 (33.8%) of 59 male infants and in 17 (39.5%) of 43 female infants (Fig. 2) ($p=0.99$). ROP occurred in 27 (34.9%) of 79 single birth and in 10 (43.4%) of 23 twin birth babies ($P=0.57$)(Fig. 3). ROP was found to be present in 14 (37.8%) of 37 babies that had been born by normal vaginal delivery and in 23 (35.3%) of 65 babies born through LSCS in the study population ($p=0.97$)(Fig. 4). None of these differences was statistically significant.

ROP was found in 12(85.7%) of 14 babies in the early preterm group but in only 22 (33.8%) of 65 babies in the moderate preterm group and in three (13%) of 23 babies in the late preterm group in the study population ($p=0.00004$)(Table 1). Moreover, ROP was noted in all four (100 %) babies in the extremely low birth weight group, 21 (55.26%) of 38 babies in the very low birth weight group and in 12(20%) of 60 babies in the low birth weight group in the study population ($p=0.00003$)(Table 2). All these differences were statistically significant.

ROP was noted in one (14.2%) of seven babies born to a mother with gestational diabetes mellitus and in seven (35%) of 20 babies born to mothers with pregnancy- induced hypertension in the study population; these maternal features did not appear to be significant risk factors ($P=0.39$)(Table 3).

ROP was detected in 35 (44.3%) of 79 babies with RDS (statistically significant, $P=0.004$), in one (14.2%) of seven babies with CHD (not significant, $P=0.21$), in 16(48.4%) of 33 babies with sepsis (not significant, $P=0.12$), in 10(71.4%) of 14 babies that had received a blood transfusion (statistically significant, $P=0.0081$) and in 22(37.9%) of 58 babies that had received phototherapy (not significant, $P=0.85$)(Fig. 5).

With reference to oxygen therapy received through a cannula, ROP was noted in five (13.6%) of 36 babies that had received this for less than three days and in 16 (55.1%) of 29 babies that had received this for more than three days (difference not significant, $P=0.8476$). With reference to oxygen therapy received through a

hood, ROP was detected in one (50%) of two babies that had received this for less than three days and in one (50%) of two babies that had received this for more than three days (difference not significant, $P=0.6835$). Interestingly, with regard to oxygen therapy received through continuous positive airway pressure (CPAP), ROP was detected in three (33.3%) of nine babies that had received this for less than three days and in 10(90.9%) of 11 babies receiving this for more than three days (difference statistically significant, $P=0.003$). ROP was also noted in 2 (100%) babies receiving oxygen through a ventilator for less than three days and in all 11 (100%) babies receiving this for more than three days (difference statistically significant, $P=0.0001$) (Fig. 6).

Table 1: Number of ROP among various gestational age groups in the study population

Gestational age group	Retinopathy of prematurity		Total
	Present	Absent	
Early preterm(EPT)	12	2	14
Moderate preterm(MPT)	22	43	65
Late preterm(LPT)	3	20	23
Total	37	65	102

Table 2: Number of ROP among various between birth weight category in the study population

Birth weight category	Retinopathy of prematurity		Total
	Present	Absent	
Extremely low birth weight	4	0	4
very low birth weight	21	17	38
Low birth weight	12	48	60
Total	37	65	102

Table 3: Possible association between maternal risk factors and ROP in the study population

Maternal Risk factors	ROP	Percentage
GDM	1	2.70%
PIH	7	18.92%
NIL risk factor	29	78.38%
Total	37	100%

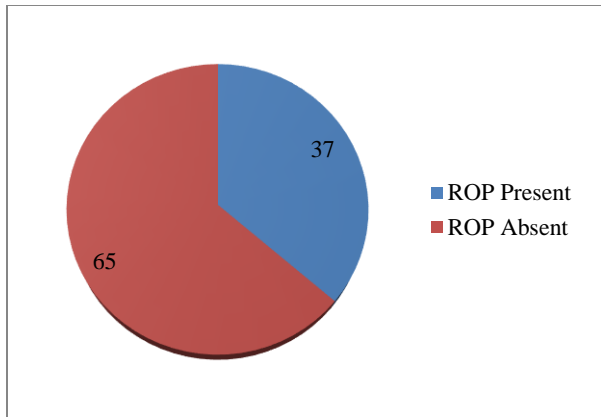


Fig. 1: Frequency of occurrence of retinopathy of prematurity in the study population

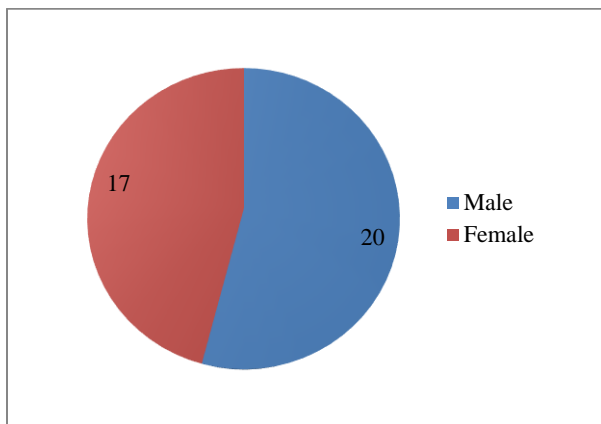


Fig. 2: Sex distribution of ROP in the study population

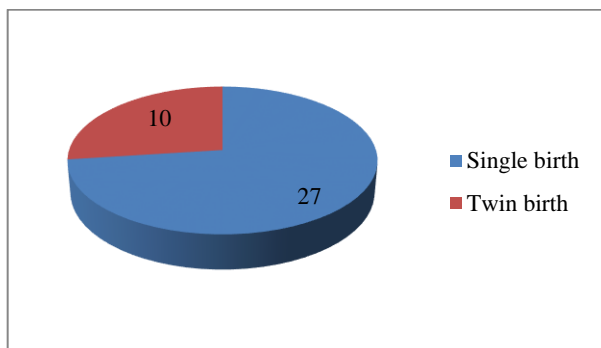


Fig. 3: Number of ROP among single birth /twin birth

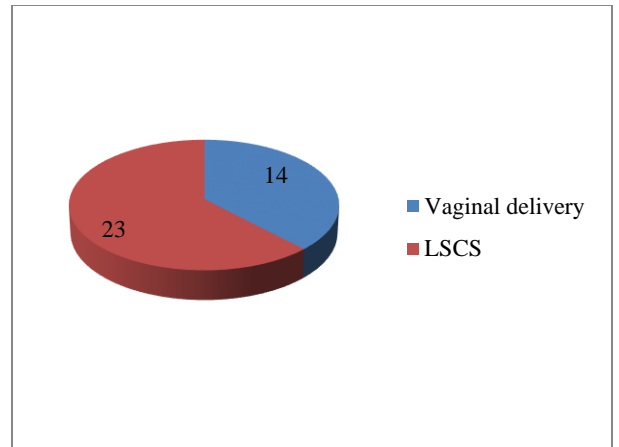


Fig. 4: Number of ROP among normal vaginal delivery/lower segment caesarian section

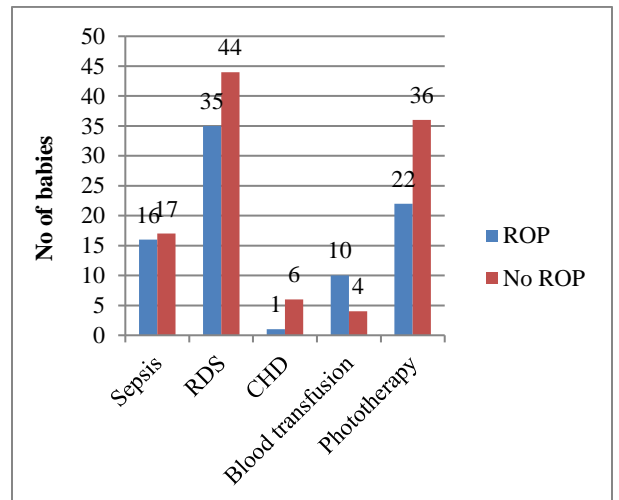


Fig. 5: Number of ROP babies with postnatal risk factors

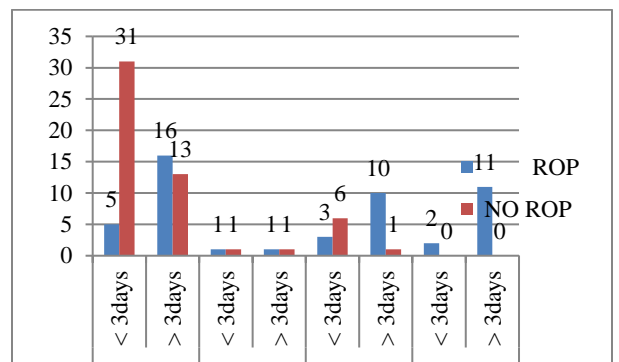


Fig. 6: Association between oxygen therapy and ROP in the study population

Discussion

The overall prevalence of ROP in this study was 36.2%. In the current study, the cut off for screening was ≤ 36 weeks of gestational age and with birth weight of ≤ 2500 gm. ROP was found to be present in a total of 25 babies who were more than 28 weeks of gestational

age, and in 12 babies with birth weight greater than 1500 g. These constituted 46.8% and 20.6%, respectively, of the total of 37 babies with ROP, who would have been otherwise missed using the AAP screening guidelines. The findings of the current study support Anand et al⁽⁷⁾ study which recommend a higher cut off for gestational age and birth weight for ROP screening in the Indian population when compared with the Western population.

In the current study, ROP occurred more often in male babies (57.8%), but the difference from female babies (42.1%) was not statistically significant. Thus, the results suggest that there is no definite gender associated risk factors in the development of ROP. Among maternal risk factors, pregnancy induced hypertension (PIH) was found in 20 (19.6%) mothers of the screened babies; however, ROP did not occur significantly in babies born of mothers with PIH.

In the current study, univariate analysis showed that the following risk factors occurred statistically significant in babies with ROP than in babies without ROP: Early preterm babies, extremely low birth weight, administration of oxygen through continuous positive airway pressure administration of oxygen through ventilator, respiratory distress syndrome and blood transfusion.

Conclusion

Most Indian studies need to develop standard guidelines incorporating the high gestational ages and birth weights of babies seen with ROP. If Western guidelines are simply adopted, then many Indian children may not be afforded the opportunity to receive vision saving treatment. Prenatal risk factors of early preterm, extremely low birth weight and post natal risk factors of respiratory distress syndrome, blood transfusion, oxygen therapy all appeared to contribute significantly to development of ROP. Other risk factors also occurred, but were not shown to be statistically significant, perhaps due to the small (less than optimal) sample size.

In India, the leading cause of preventable blindness in childhood is ROP. The challenge is to identify the individuals that would benefit from vision saving therapy. Timely screening and early management is the key for the management of ROP.

Awareness of this condition and screening of preterm infants by detailed clinical examination, as well as meticulous recording of other details such as prenatal risk factors, postnatal risk factors and maternal risk factors, will go a long way to ensure that ROP, if present, is detected at an early stage, for which a favorable outcome can be obtained.

References

1. Early Treatment for Retinopathy of Prematurity Cooperative Group: Final visual acuity results in the early

2. Kumar, Vinay "Chapter 29: Eye, Retina and Vitreous, Retinal Vascular Disease". Philadelphia: Saunders/Elsevier 2007; ISBN 978-1416029731.
3. Disorder related to short gestation age and low birthweight-ICD10, P05 disorder related to length of gestation and fetal growth ICD -10. ELBW infant article by K N Siva Subramanian MD e med 2007-11-28.
4. Analysis of risk factors for the development of retinopathy of prematurity in preterm infants at tertiary referral hospital in south India Krishna R Murthy, Nagendra, Actamedica lituanica 2006 vol 13 No.3P 147-151.
5. International Committee for the Classification of Retinopathy of Prematurity. The international classification of retinopathy of prematurity revisited. Arch Ophthalmol 2005;123(7):991-9.
6. Fierson WM; American Academy of Pediatrics, Section on Ophthalmology; American Academy of Ophthalmology; American Association for Pediatric Ophthalmology and Strabismus; American Association of Certified Orthoptists. Screening examination of premature infants for retinopathy of prematurity. Pediatrics 2013;131(1):189-95.
7. Retinopathy of prematurity in Asian Indian babies weighing greater than 1250 grams at birth: Ten year data from a tertiary care center in a developing Country Anand Vinekar, MS, FRCS, Mangat R Dogra, MS, Tiakumzuk Sangtam, MS, Anil Narang, MD, and Amod Gupta, MS, Indian J Ophthalmol 2007;55:331-6.
8. Hakeemet al, study of prevalence and risk factors of ROP, Middle East Afr j ophthal2012 jul;19(3):289-294.
9. Darlow BA, Hutchinson JL, et.al. Prenatal risk factors for severe retinopathy of prematurity among very preterm infants of the Australian and New Zealand Neonatal Network Pediatrics 2005 Apr;115(4):990-6.