

## B scan ultrasonography before surgery in eyes with dense cataracts

Ram Kumar<sup>1,\*</sup>, Deepti Yadav<sup>2</sup>, Akash Srivastava<sup>3</sup>

<sup>1</sup>Professor, <sup>2,3</sup>Junior residents, Dept. of Ophthalmology, B.R.D. Medical College, Gorakhpur

\*Corresponding Author:

Email: ramkumarjaiswal35@yahoo.com

### Abstract

**Aim:** To determine the proportion of posterior segment abnormalities in patients with or without risk factors having dense cataract prior to surgery using B scan ultrasonography.

**Materials and Methods:** A cross sectional study was performed on 240 eyes with dense cataract using B scan ultrasonography. Patients having history of blunt/penetrating trauma, previous ocular surgery or known case of posterior segment pathology were excluded from the study.

**Results:** Out of 224 patients in our study 152 patients were without any systemic risk factor. 12 patients had diabetes mellitus, 6 patients had hypertension, 42 patients had age < 50 years, 16 patients had bilateral dense cataract. 152 patients did not have any systemic risk factor and 2 of them present with detectable posterior segment abnormality on ultrasound. Out of 240 eyes examined 200 eyes did not have any ocular risk factor in which 2 eyes detected with posterior segment abnormality. Out of 22 eyes with posterior synechiae 6 eyes detected with posterior segment abnormality. Out of 8 eyes had iris coloboma 6 eyes detected with posterior segment abnormality. Out of 12 eyes with elevated IOP 4 eyes detected with abnormal ultrasound. Out of 6 eyes with small cornea all 6 eyes detected with abnormal ultrasound. Out of 240 eyes with dense cataract examined preoperatively with B-scan ultrasound 31 eyes had detected with posterior segment abnormality. Out of 240 eyes 10 eyes detected with retinal detachment, 5 eyes detected with PVD, 2 eyes detected with retinal detachment with choroidal coloboma, 2 eyes had vitreous haemorrhage, 4 eyes had choroidal coloboma with optic disc coloboma, 4 eyes had posterior staphyloma, 4 eyes had cupping of optic nerve head.

**Conclusion:** In our study Patients with systemic and ocular risk factors showed high incidence of posterior segment pathology. Ideally all the patients with dense cataract should undergo with a B scan examination but most patients with dense cataract are currently encountered in developing countries, most hospitals in these area do not have an easy access to ultrasound So the patients with systemic and ocular risk factors should be referred to the centers where the facility is available in order to plan better management and to determine proper visual prognosis before surgery.

**Keywords:** B scan ultrasonography, Dense cataract, PVD, Retinal Detachment.

### Introduction

B Scan ultrasonography is a non-invasive, efficient, reliable and inexpensive diagnostic technique for evaluation of ocular pathology. Both A scan and B Scan techniques are important for the diagnosis of posterior segment lesion. B (Brightness) mode is useful for a better demonstration of the shape and topographic relationship of lesion in the posterior segment.<sup>(1,2)</sup> B Scan provide cross sectional display of the diseased tissues and is valuable in detecting unsuspected posterior segment disease.<sup>(1,2,3)</sup> B scan ultrasonography is an important adjuvant for the clinical assessment of various ocular and orbital diseases. With the understanding of the indications for ultrasonography and proper examination technique, one can gather a vast amount of information not possible with clinical examination alone. B Scan ultrasonography has enabled us to study posterior segment of the eye in the presence of opaque media. its most common use is in a contact mode for evaluation of the posterior segment of eyes with media opacification,<sup>(4)</sup> and provides a method of assessing the structural changes in the posterior segment of eye in such patients.<sup>(5,6)</sup> Most frequent findings of posterior segment lesions associated with perforating and blunt trauma and also without trauma are recorded on B scan ultrasound, like retinal

detachment, vitreous haemorrhage, intraocular foreign body, neoplasia and posterior vitreous detachment.<sup>(7,8,9)</sup> In dense cataract, is essential before surgery to aid surgical planning and guide the expectations of patients.

Indications for examination<sup>(10-14)</sup> B-scan ultrasound most useful when direct visualization of intraocular structures is difficult or impossible. Situations that prevent normal examination include-Lid problems e.g. severe edema, partial/total tarsorrhaphy, corneal opacities, scars, severe edema, hyphaema, hypopyon, miosis, papillary membrane, dense cataract, vitreous opacities (e.g. hemorrhage, inflammatory debris). In such case, diagnostic B-scan ultrasound can accurately image intraocular structures and give valuable information and give valuable information on the status of lens, vitreous, retina, choroid, and sclera.

A-scan (amplitude modulation scan) produces a single dimensional display of multiple spikes of any place through the eye. The plane is obtained by passing the vector A-scan on B-scan image. The spikes on A-scan represent amplitude/reflectivity of an echo on the plane. Thus B scan produces a real time 2D image of a particular plane through the eye. Multiple images can be obtained by moving the probe, in horizontal, vertical and transverse planes. The most important advantage of B mode is ability to study the real time movement of

various lesions in the vitreous cavity, the echo poor vitreous act as a natural contrast for ultrasound evaluation of the posterior segment. Since eye is a fluid filled, cystic organ, superficially placed in the orbit therefore B scan ultrasonography is ideal, non-invasive, imaging method to visualize the details of ocular pathologies.

The purpose of study is to evaluate usefulness of diagnostic B scan ultrasound and to know the prevalence of posterior segment abnormalities in patients with dense cataract prior to surgery by ultrasonography.

### Objective

To determine the proportion of posterior segment abnormalities in patients with dense cataract prior to surgery using B-scan.

### Materials and Methods

Data for the study is collected from patients attending/referred to outpatient department of ophthalmology Nehru Chikitsalaya B.R.D. Medical college Gorakhpur having dense cataract. The study Period is Dec 2015 to Nov 2016.

A cross sectional study of sample size of a minimum 240 eyes in 224 patients fulfilling the mentioned inclusion criteria included in this study. They had evaluated using a standard USG Machine Appasamy associates AB-Scan with UBM equipped with a real time high frequency probe with the contact method, the probe is placed over the closed eyelid after application of coupling gel. The study is conducted on the patients of both sex and all age group having dense contract.

#### Patient evaluation done as mentioned below

- Patient particulars-Name, Age, Sex
- Presenting history-Diminution of vision, Trauma, Leucocoria

#### Inclusion criteria

- Patient clinically presenting with dense contract Without risk factor

With risk factors

Ocular risk factor-keratic precipitates, high IOP, posterior synechiae, any congenital anomaly, coloboma, Iris hypoplasia, small cornea

Systemic risk factors-diabetes mellitus, Systemic hypertension, early age (less than 50 years), bilateral cataract.

Exclusion criteria- Patient with active ocular surface infection, with high risk of /with extrusion of intraocular contents, with old or recent penetrating or blunt orbital trauma, with known presence of posterior segment pathology in eye to be operated, with afferent

papillary conduction defect, with previous ocular surgery.

For past history patient was enquired about any previous disease or any hospital admission. Patient was asked regarding presence of symptoms of Diabetes mellitus, Hypertension, Tuberculosis, Vascular disorder.

Examination -general and systemic examination performed in all the patients and in local examination all the patients underwent for Refraction, Slit lamp examination, Tonometry (with Schiotz tonometer), direct and indirect ophthalmoscopy and B-scan ultrasonography. B-scan ultrasonography is usually done either with eyelid closed and other eye kept open fixing at a target or with open eye after application of topical anesthetic eye drop. Coupling medium like methylcellulose is applied on the B-scan probe.

### Results

This cross-sectional study sought to find out the proportion of posterior segment abnormalities in patients with dense cataract prior to surgery. A total 224 patients who met the inclusion criteria during the study period were enrolled and examined with B-scan ultrasound.

**Table 1: Showing age distribution of patients**

Age group	No. of cases	Percentage
0-10	04	01.78
11-20	02	00.89
21-30	00	00.00
31-40	08	03.57
41-50	28	12.50
51-60	50	22.32
61-70	98	43.75
71-80	34	15.18
Total	224	100.0

**Table 2: Showing sex distribution of patients**

Sex	No. of cases	Percentage
Male	138	61.61
Female	86	38.39
Total	224	100

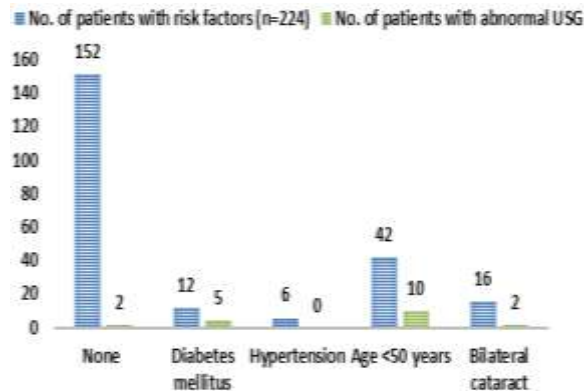
**Table 3: Showing percentage of eyes affected**

Eye	No. of cases	Percentage
Right eye	100	44.64
Left eye	108	48.12
Both eyes	16	7.14
Total	224	100

**Table 4: Showing systemic risk factors and incidence of abnormal ultrasonograph**

Systemic risk factor	No. of patients with risk factors (n=224)	No. of patients with abnormal USG	Percentage (of patients with risk factor having abnormal USG)
None	152	2	0.89
Diabetes mellitus	12	5	2.23
Hypertension	06	0	00
Age <50 years	42	10	4.46
Bilateral cataract	16	2	0.89
	228*	19	7.92

\*4 patients having age <50 years and bilateral cataract so total number exceeds 224.

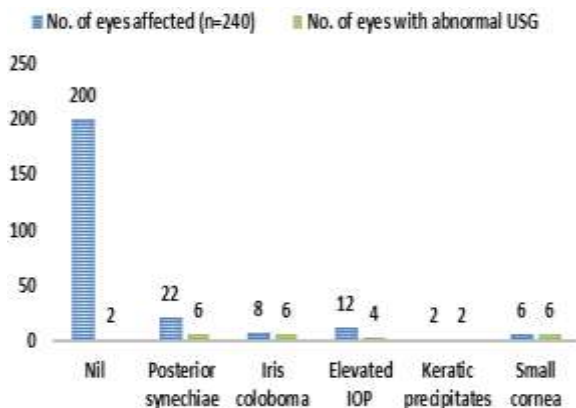


**Fig. 1: Systemic risk factors and incidence of abnormal ultrasonograph**

**Table 5: Showing ocular risk factors and incidence of abnormal ultrasonography**

Ocular risk factors	No. of eyes affected (n=240)	No. of eyes with abnormal USG	Percentage of yes having abnormal USG
Nil	200	2	0.83
Posterior synechiae	22	6	2.50
Iris coloboma	08	6	2.50
Elevated IOP	12	4	1.67
Keratic precipitates	02	2	0.83
Small cornea	06	6	2.50
	250	26	

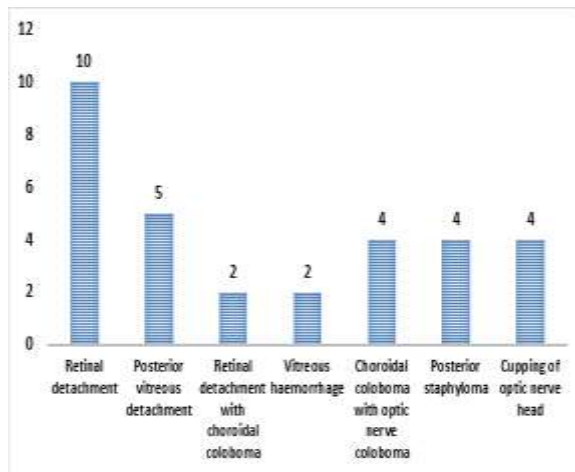
2 eye had posterior synechiae, elevated IOP and keratic precipitates. All 6 eyes with small cornea had iris coloboma. So total no. of eyes exceeds n=240 eyes.



**Fig. 2: Ocular risk factors and incidence of abnormal ultrasonography**

**Table 6: Showing incidence of abnormalities detected on preoperative ultrasonography**

Abnormal finding on USG	Frequency (n=240)	Percentage
Retinal detachment	10	04.16
Posterior vitreous detachment	05	2.08
Retinal detachment with choroidal coloboma	02	00.83
Vitreous haemorrhage	02	00.83
Choroidal coloboma with optic nerve coloboma	04	01.67
Posterior staphyloma	04	01.67
Cupping of optic nerve head	04	01.67
Total	31	12.91



**Fig. 3: Incidence of abnormalities detected on preoperative ultrasonography**

### Discussion

In our study out of 224 patients (including patients of all age group) maximum no. of cases were shared among groups 51-60 and 61-70 as incidence of cataract is maximum in this age group, 138 male cases (62.61%) outnumbered 86 female cases (38.39%), 100 patients (44.64%) presented with Right eye dense cataract, 108 patients (48.12%) presented with Left eye dense cataract and 16 patients (7.14%) presented with both eye dense cataract. Out of 224 patients in our study 152 patients (67.86%) were without any systemic risk factor. 12 patients (5.36%) had diabetes mellitus, 6 patients (2.68%) had hypertension, 42 patients (18.75%) had age <50 years, 16 patients (7.14%) had bilateral dense cataract. 152 patients (67.86%) did not have any systemic risk factor and 2 (0.89%) of them presented with posterior segment abnormality on ultrasound. Out of 12 patients with diabetes mellitus 5 patients (2.23%) detected with abnormal ultrasound. Out of 6 patients with hypertension no patient detected with any posterior segment abnormality. Out of 42 patients age <50 years 10 patients (4.46%) detected with posterior segment abnormality. Out of 16 patients with bilateral cataract 2 patient (0.89%) detected with posterior segment abnormality.

Out of 240 eyes examined 200 eyes (83.33%) had no ocular risk factor, 22 eyes (9.17%) had posterior synechiae, 8 eyes (3.33%) had iris coloboma, 12 eyes (5.00%) had elevated IOP, 2 eyes (0.83%) had keratic precipitates and 6 eyes (2.50%) had small cornea. 2 eyes had 3 ocular risk factors posterior synechiae, keratic precipitates and elevated IOP. Out of 8 eyes with iris coloboma 6 eyes also had small cornea and 6 eyes detected with posterior segment abnormality.

Out of 240 eyes examined 200 eyes did not have any ocular risk factor in which 2 eyes (0.83%) detected with posterior segment abnormality. Out of 22 eyes with posterior synechiae 6 eyes (2.50%) detected with posterior segment abnormality. Out of 8 eyes had iris coloboma 6 eyes (2.50%) detected with posterior

segment abnormality. Out of 12 eyes with elevated IOP 4 eyes (1.67%) detected with abnormal ultrasound. Out of 6 eyes with small cornea all 6 eyes (2.50%) detected with abnormal ultrasound. Out of 240 eyes with dense cataract examined preoperatively with B-scan ultrasound 31 eyes (12.91%) had detected with posterior segment abnormality. Out of 240 eyes 10 eyes (4.16%) detected with retinal detachment, 5 eyes (2.08%) detected with PVD, 2 eyes (0.83%) detected with retinal detachment with choroidal coloboma, 2 eyes (0.83%) had vitreous haemorrhage, 4 eyes (1.67%) had choroidal coloboma with optic disc coloboma, 4 eyes (1.67%) had posterior staphyloma, 4 eyes (1.67%) had cupping of optic nerve head.

We have many studies performed on the patients having dense cataract for the detection of posterior segment abnormalities with B-scan ultrasound. Different studies comes out with different results, the difference in results may be because the studies performed in patients with different socioeconomic status or may be because all the studies have different inclusion and exclusion criteria like we excluded traumatic cataract in our study but several studies consider these cases in their study too which affect the final outcome of the studies.

Though the results of different studies are different, all the studies shows higher percentage of posterior segment abnormality in patients have some systemic or ocular risk factors. In absence of these risk factors possibility of detecting abnormalities on preoperative ultrasonography in eyes with dense cataract is very less. However every patient undergoing cataract surgery should be examined with a B-scan ultrasound but if the facility is not available we can refer selective patients to the center where the facility is available and that will help in planning the surgery and guiding the visual expectations to the patient after surgery.

### References

1. Kendall CJ, Prager TC, Cheng H, Gombos D, Tang RA, Schiffman JS. Diagnostic ophthalmic Ultrasound for Radiologists. *Neuroimaging Clin North Am* 2015;25(3):327-65.
2. Byrne SF, Green RL. *Ultrasound of the Eye and Orbit*. 2nd ed. St. Louis, Mosby Year Book; 2002.
3. Mustafa M, Motgomery J, Atta H. A novel educational tool for teaching ocular ultrasound. *Clin Ophthalmol* 2011;5:857-60
4. Athey PA, McClendon L. *Diagnostic Ultrasound for Radiographers*. 1st ed. Multimedia Publishing Inc: Denver, 1983.
5. Richard L, Hart LJ. *Ultrasound Diagnosis of the eye and orbit. Principle and Practice of Ophthalmology*. 1997;5:98.
6. Mundt GH, Hughes WF. Ultrasonics in ocular diagnosis. *Am J Ophthalmol*. 1956;41:488-98.
7. Baum G, Greenwood I. The application of ultrasonic locating technique to ophthalmology. *Arch Ophthalmol*. 1958;60:263-79.
8. Bronson N R, Turner FT. A simple B-scan ultrasonoscope. *Arch Ophthalmol*. 1973;90:237-238.

9. Parchand S, Singh R Bhalekar S. Reliability of ocular ultrasonography findings for pre surgical evaluation in various Vitreo-retinal disorders. *Semin Ophthalmol* 2014;29(4):236-41.
10. Coleman DJ, Silverman RH, Lizzi FL, Rondeau MJ. *Ultrasonography of the Eye and Orbit*. 2<sup>nd</sup> ed. Lippincott Williams & Wilkins; 2006
11. Byrne SF, Green RL. *Ultrasound of the Eye and Orbit*. St. Louis, Mo: Mosby Year Book;1992.
12. A simplified B-Scan ultrasonoscope for ocular diagnosis. *Ann Ophthalmol*. 1975;7(7):927-33.
13. Fisher YL. Contact B-scan ultrasonography: a practical approach. *Int Ophthalmol Clin*. 1979;19(4):103-25.
14. Javed EA, Chaudhry AA, Ahmed I, Hussain M. Diagnostic applications of B-scan. *Pak J Ophthalmol*. 2007;23(2):80-83.