

## Evaluation of endothelial cell density and central corneal thickness in cases of pseudoexfoliation

Nishat Sultana<sup>1,\*</sup>, Apoorva Mithranand<sup>2</sup>, Vinuta Mohan Kulkarni<sup>3</sup>

<sup>1</sup>Professor, <sup>2,3</sup>Junior Resident, Dept. of Ophthalmology, Minto Ophthalmic Hospital, BMCRI, Bangalore

**\*Corresponding Author:**

Email: nishatsultana29@gmail.com

### Abstract

**Background:** Aim of the study is to evaluate endothelial cell density and central corneal thickness in cases of pseudoexfoliation admitted for cataract surgery in tertiary care hospital using specular microscopy.

**Materials and Methods:** Total of 30 cases were studied prospectively in a period of 10 months during march,2016 to jan,2017 to evaluate the endothelial cell density and CCT using specular microscopy with detailed history and ocular examination.

**Result:** In our study of 30 cases, it was shown no gender predilection and bilaterality was seen in 83%.80% of cases had endothelial cell density less than 2500cells/ $\mu\text{m}$  on specular microscopy. 93% of cases had CCT less than 545 $\mu\text{m}$  which is grossly significant as seen in previous studies.

**Conclusion:** Pseudo exfoliative syndrome presents challenges to the operating surgeon that require careful pre-operative evaluation. Our study showed that these cases have significantly lower endothelial cell density and increased risk of corneal decompensation after intra ocular surgeries. These pseudo exfoliative cases also have significantly low central corneal thickness which may under estimate the IOP reading and overlook an early glaucomatous damage. Thus evaluation of endothelial cell density and central corneal thickness becomes an imperative pre-operative step in cases of pseudo exfoliation.

**Keywords:** Central corneal thickness, Endothelial cell density, Pseudoexfoliation, Specular microscopy.

### Introduction

Pseudoexfoliation which was first described by Lindberg in 1917,<sup>(1)</sup> is a age related systemic disorder with primary ocular manifestation with strong genetic component.<sup>(2-4)</sup> Genetically linked to lysyl-oxidase-like-one(LOXL-1) gene<sup>(5)</sup> and disorder is shown to be associated with accumulation of greyish white fibrogranular extracellular pseudoexfoliative material produced by abnormal basement membrane of ageing epithelial cell in trabeculum, lens capsule, iris, ciliary body of the eye, corneal endothelium.<sup>(6)</sup> These changes have shown to be related to cataract, glaucoma, lens subluxation, pseudouveitis, retinal vein occlusion and keratopathy.<sup>(7)</sup> The corneal endothelium which consists of a monolayer of polygonal cells maintain the corneal Deturgescence throughout the life. Average endothelial cell count is about 3000 cells/ $\text{mm}^3$  that decreases at the rate of 0.6% every year. At density less than 500cell/ $\text{mm}^3$ , cornea decompensates and loses transparency affecting the vision.<sup>(8)</sup> In patients with PEX qualitative and quantitative morphological changes in corneal endothelium predispose to endotheliopathy that may be more susceptible to the effects of intra ocular surgery.<sup>(9)</sup> Studies have shown that high CCT lead to overestimate and low cct leads to underestimation of IOP readings<sup>(10)</sup> Hence, underestimation of IOP in cases of PEX would cause serious implication as such cases show faster progression of optic disc damage and poorer prognosis. PEX cases have shown to be associated with 5 times more likelihood of intra operative complications such as zonular instability, insufficient mydriasis, dropped lens material, vitreous prolapse, shallow anterior

chamber and thus make routine cataract surgery a challenging task.<sup>(11)</sup> So meticulous examination and early diagnosis of PEX becomes essential to alert surgeon regarding complications. The aim of this study is evaluation of endothelial cell density and central corneal thickness in cases of pseudoexfoliation.

### Materials and Methods

On approval from the ethical committee, prospective study was conducted on 30 patients admitted in Minto Ophthalmic Hospital, Bangalore medical college and research institute, Bangalore for cataract surgery in period of 10 months from March 2016 to Jan 2017. Sample included patients diagnosed to have pseudoexfoliation on slit lamp biomicroscopy .After taking informed consent all patients underwent detailed examination including visual acuity using Snellen chart, slit lamp biomicroscopy, IOP using perkins applanation tonometry, fundus evaluation with Indirect ophthalmoscope with 20D and 90D.All the patients were subjected to specular microscopy with TOMEY EM-3000 specular microscopy, average endothelial cell density and CCT were noted. Data was analysed statistically using chi square tests.

### Results

In our study of 30 cases, 15 were males and 15 females, showing no gender predisposition. Among 30 patients, pseudoexfoliation was seen in 83% of the cases and unilateral in 27% of the cases. Out of 30 cases, 30% of the cases had associated systemic illness like diabetes, hypertension and 70% with no systemic co-morbidities. In the present study of 30 cases, 80%

cases (n=24) were observed to have endothelial cell density less than 2500cell/mm<sup>3</sup> on specular microscopy, and 30% cases among them with endothelial cell count as low as less 2000cell/mm<sup>3</sup>. Considering another variable, among 30 cases 93% of the cases (n=23) were observed to have CCT of less than 545μm which is grossly significant. 43% of the cases with less 500 μm and 6% with as low as less than 450μm were observed.

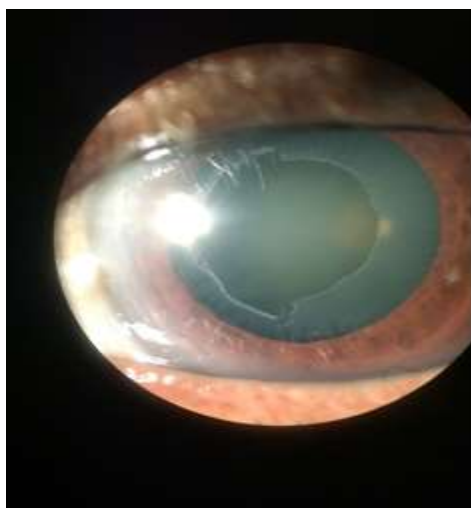


Fig. 1: Pseudoexfoliation

Table 1: Patients Demographics

Age	Males	Females	Total	Percentage
<50	0	0	0	0
50-60	2	2	4	13.33
60-70	5	8	13	43.33
70-80	8	4	12	40
80-90	0	1	1	3.33
> 90	0	0	0	0
	15	15	30	100

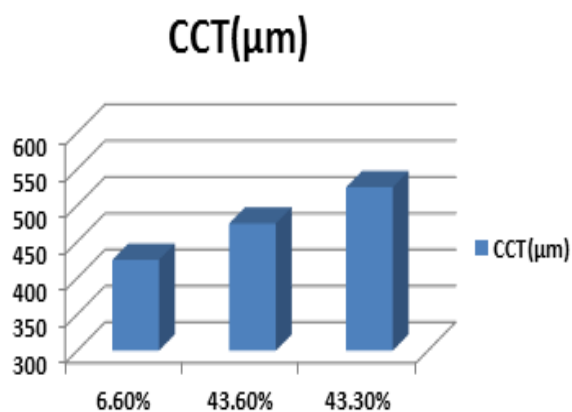


Fig. 2: Evaluation of CCT

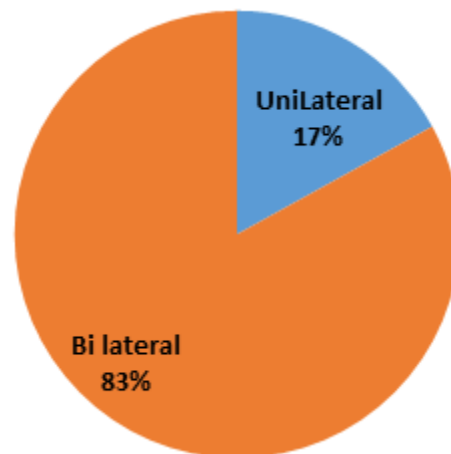


Fig. 3: Distribution of pseudo exfoliation

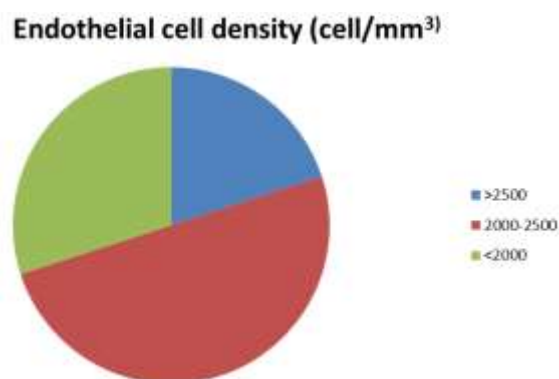


Fig. 4: Evaluation of Endothelial Cell Density

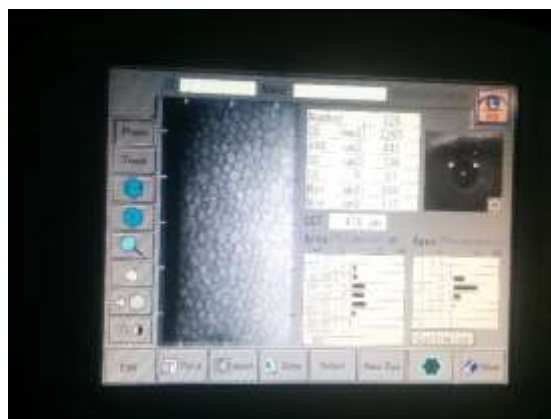

Fig. 5: Specular Microscopy of a pseudo exfoliation



**Fig. 6: TOMHEY EM-3000 Specular Microscopy**

## Discussion

Pseudoexfoliation syndrome is a systemic disorder which is a result of abnormal metabolic changes in cell leading to accumulation of fibrillary material in anterior segment of the eye and other organs. Frequently seen in cases of cataract as its prevalence increases with age. Insufficient mydriasis, zonular weakness, more chances of posterior capsule rupture, more risk of endothelial decompensation which acts as challenging task to surgeon during operating cataract in such cases. In our study, among 30 patients with pseudoexfoliation, 80% are observed to have significantly low endothelial cell density. Our findings are consistent with various other research studies such as Zheng et al.,<sup>(12)</sup> Kovliulas et al.,<sup>(13)</sup> Zarnowski et al.<sup>(14)</sup> and Quiroga et al.<sup>(15)</sup> These researchers have clearly shown that pseudo exfoliation significantly influences cell density of corneal endothelium, the main reason is shown to be pseudo exfoliative material that settles on the endothelium penetrating it in the direction of descemet's membrane and breaking the connections between the individual hexagonal cells, resulting in accelerated apoptosis of the cells. Apart from these other factors are Hypoxia of anterior chamber, changes in fibro blast of the endothelium and elevated concentration of TGF- $\alpha$  1.<sup>(16)</sup> Endothelial cell density of less than 800 cells results in corneal decompensation, allowing aqueous/ocular fluid to seep into the corneal stroma causing loss of corneal transparency.<sup>(17)</sup> To determine patients that are at risk for corneal decompensation a simple test of knowing endothelial cell density can be used and alert surgeon to take necessary precautions. Among 30 patients central corneal thickness obtained from specular microscopy shown that about 93% (n = 28) of the cases have corneal thickness less than 545 micro meters. Among them 43% (n = 13) have shown to have central corneal thickness of less than 500  $\mu$ m. 6% of the cases had central corneal thickness as low as 450  $\mu$ m. The results are consistent with the studies presented by Kitsos et al.,<sup>(18)</sup> where they used ultrasonic pachymeter for the assessment of central corneal thickness. Our study findings are consistent with findings given by another

study conducted by Acar et al.<sup>(19)</sup> Another study conducted by Yagci et al.<sup>(20)</sup> and Sobottka et al.<sup>(21)</sup> also noticed that people with pseudo exfoliation had lower central corneal thickness value. In contrast to this, study conducted by Hepesen et al and Arnarsson et al showed that thickness of cornea of pseudo exfoliation cases is greater than normal people. However the study published by Zheng et al identified deposits of pseudo exfoliative material in the cornea and showed that number of keratocytes in the corneal stroma of pseudo exfoliative cases was lesser than cases with pseudo exfoliation. They also concluded this pseudo exfoliative material induces apoptosis of corneal stroma keratocytes and results in thinning of cornea and greater susceptibility to elevated intra ocular pressure.<sup>(12)</sup> Mechanisms of IOP elevation in exfoliative glaucoma-associated open angles may include local production of exfoliative material, endothelial cell damage of the trabecular meshwork, and passive deposition of exfoliative material and pigment originating from elsewhere in the anterior segment. It has also been observed that the probability of developing glaucomatous optic neuropathy is higher in eyes with exfoliative glaucoma than in other forms of glaucoma at similar IOP levels, suggesting an intrinsic vulnerability in the optic nerve in the former group. Although disc area and other morphometric features of the optic nerve head do not differ between non glaucomatous eyes with and without exfoliation, glaucomatous neuroretinal rim damage tends to be more diffuse with exfoliative glaucoma. Immunoelectron microscopic studies of the lamina cribrosa have shown elastosis, suggesting abnormal regulation of elastin synthesis or degradation, or both, in the optic nerve head of patients with the exfoliation syndrome, consistent with the role of LOXL1. Zonular dialysis, poor dilatation, vitreous loss, capsular fibrosis, posterior capsule rupture and decentration of lens implant are the challenges surgeon has to face in pseudoexfoliation cases. Helpful tips for cataract surgery are to make the capsulorrhexis large so as to enable the nucleus or pieces of the nucleus to prolapse into the anterior chamber, thus minimizing zonular stress; a large capsulorrhexis also helps prevent capsular phimosis, which is common in eyes with exfoliation syndrome. During hydrodissection, care should be taken to tap on the center of the nucleus from time to time to decompress fluid pressure on a weak posterior capsule. If zonular weakness is evident intraoperatively, a capsule tension ring or capsule tension segments can be helpful. In addition to taking special care to minimize zonular stress during nucleus manipulation and removal of the cortex, if the pupil size is small, the surgeon should consider mechanically dilating and maintaining pupil dilatation. Given the presence of endotheliopathy, the surgeon should also be generous when using their viscoelastic agent of choice to protect the corneal endothelium. The use of a posterior chamber intraocular lenses is well tolerated in

patients with the exfoliation syndrome, although there may be a greater risk for fibrinoid reaction in these patients.<sup>(22)</sup> When choosing an intraocular implant, a 3-piece intraocular lens implant should be considered in all patients with PXF. The 3-piece lens plays a dual role by acting as a pseudo-CTR and reducing zonular stress with the haptics providing tension to place the capsular bag on stretch. Moreover, if there is only 1 to 2-clock hours of dialysis, the 3-piece lens may be sufficient to stabilize the capsular bag (i.e., a form of poor man's CTR) if the haptics are placed along the axis of zonular weakness or dehiscence. In addition to intraoperative concerns, PXF post-cataract surgery eyes have postoperative issues to consider. PXF is associated with iris vascular leak and a compromised blood-aqueous barrier. PXF patients have more postoperative inflammation and a higher risk of postoperative pressure spikes. PXF cataract patients often need to be treated more aggressively with postoperative steroids and perhaps for a longer duration. Another concern noted previously is capsular phimosis. If observed, the capsular contraction can be treated using a neodymium-doped yttrium aluminum garnet laser by placing relaxing incisions in the anterior lens capsule at the 4 cardinal positions.<sup>(23)</sup> Our study concludes that pseudo exfoliative cases have low central corneal thickness attributed to the hydro dynamic forces exerting constant pressure on the walls of the eye with greater susceptibility to intra ocular pressure causing reduction corneal thickness.

## Conclusion

Pseudo exfoliative syndrome presents challenges that require careful pre-operative evaluation. Our study showed that these cases have significantly lower endothelial cell density and increased risk of corneal decompensation after intra ocular surgeries. These pseudo exfoliative cases also have significantly low central corneal thickness which may under estimate the IOP reading and overlook an early Glaucomatous damage. Early detection of pseudoexfoliative glaucoma can aid to render appropriate treatment. Thus evaluation of endothelial cell density and central corneal thickness becomes an imperative pre-operative step in cases of pseudo exfoliation.

## Reference

1. Tarkkanen A, Kivela T, "John G. Lindberg and the discovery of exfoliation syndrome" *Acta Ophthalmol Scand*.2002;80:151-4.
2. R R Allingham, M Loftsdottir, M S Gortfredsdottir et al "Pseudoexfoliation syndrome in Iceland families" *british journal of ophthalmology* 2001;vol 85,702-707.
3. U Schlotzer-Schrehardt, M r Koca, G O H Naumann and H Volkholz "Pseudoexfoliation syndrome: ocular manifestation of a systemic disorder" *American journal of ophthalmology*,2006,141 vol,921-933.
4. R Ritch and U Schlotzer-Schrehardt, "exfoliation syndrome", *survey of ophthalmology*,2001,45,265-315.
5. Thorleifsson G, Magnusson KP, Sulem P, Walters GB, Gudbjartsson DF et al "common sequence variants in the LOXL1 gene confer susceptibility to exfoliation glaucoma", *Science*,2007,317,1397-1400.
6. Streten BW, Li ZY, Wallace RN, Eagle RC, Jr, Keshgegian AA "Pseudoexfoliative fibrilopathy in visceral organs of a patient with pseudoexfoliation syndrome", *arch Ophthalmol*,1992,110,1757-62.
7. G Martone, F Casprini, C Traversi, F Lepri, P Pichierri and A Caporossi "Pseudoexfoliation syndrome: in vivo confocal microscopy analysis", *clinical and experimental ophthalmology*,2007,35,no 6,582-585.
8. Brad Bowling Kanski'S *Clinical Ophthalmology-ASystemic Approach*,8<sup>TH</sup> edition,chap-6,p168.
9. G O H Naumann, U Schlotzer-Schrehardt, "corneal endothelial involvement in pseudoexfoliation syndrome" *Arch Ophthalmol*,1994,112,297-298.
10. M J Doughty and M L Zaman "human corneal thickness and its impact on intra ocular pressure measures:a review and meta-analysis approach". *Survey of ophthalmology*,2000,vol 44,no 5,367-408.
11. Scorolli L, Scorolli L, Campos EC, Bassein L, Meduri RA, "Pseudoexfoliation syndrome: A Cohort study on intra operative complications in cataract surgery".1998,212,278-80.
12. X. Zheng, A. Shirashi, S. Okuma et al, "In vivo confocal microscopic evidence of keratopathy with pseudoexfoliation syndrome", *Investigative Ophthalmology and Visual Science*,2011,vol 52,No 3,1755-1761.
13. E. Kovalionas, S. Stech, and N. Jurkute, "Characteristics of the corneal endothelium and pseudoexfoliation syndrome in patients with senile cataract," *Acta Ophthalmologica*, vol. 90, supplement 249, 2012.
14. T. 'Zarnowski, A. Lękawa, and A. Dyduch, "Gęstość 'sr'odblonka rog'owki u chorych z jaskrą," *Klinika Oczna*, vol. 107, no. 7-9, pp. 448-451, 2005.
15. L. Quiroga, C. van Lansingh, M. Samudio, F. Y. Pe~na, and M. J. Carter, "Characteristics of the corneal endothelium and pseudoexfoliation syndrome in patients with senile cataract," *Clinical and Experimental Ophthalmology*, vol. 38, no. 5, pp. 449-455, 2010
16. G. O. Naumann, U. Schl'otzer-Schrehardt, and M. K'uchle, "Pseudoexfoliation syndrome for the comprehensive ophtalmologist. Intraocular and systemic manifestations," *Ophthalmology*, vol. 105, no. 6, pp. 951-968, 1998.
17. T. Olsen and J. S. Eriksen, "Corneal thickness and endothelial damage after intraocular lens implantation," *Acta Ophthalmologica*, vol. 58, no. 5, pp. 773-786,1980.
18. G. Kitsos, C. Gartzios, I. Asproudis, and E. Bagli, "Central corneal thickness in subjects with glaucoma and in normal individuals (with or without pseudoexfoliation syndrome)," *Clinical Ophthalmology*, vol. 3, no. 1, pp. 537-542,2009.
19. B. T. Acar, I. B. Buttanri, and M. S. Sevim, "Evaluation of anterior segment parameters in pseudoexfoliation syndrome patients," *Turkish Journal of Ophthalmology*, vol. 40, no. 4, pp. 217-222,2010.
20. R. Yagci, U. Eksioğlu, I. Midillioglu, I. Yalvac, E. Altıparmak, and S. Duman, "Central corneal thickness in primary open angle glaucoma, pseudoexfoliative glaucoma, ocular hypertension, and normal population," *European Journal of Ophthalmology*, vol. 15, no. 3, pp. 324-328,2005.
21. A. C. Sobottka Ventura, M. B'ohnke, and D. S. Mojon, "Central corneal thickness measurements in patients with normal tension glaucoma, primary open angle glaucoma,

- pseudoexfoliation glaucoma, or ocular hypertension,”  
British Journal of Ophthalmology, vol. 85, no. 7, pp.  
792–795,2001.
22. Allingham, R. Rand, Shields Textbook of Glaucoma, 6th  
Edition, Chap-15,p 256-257.
  23. Desai M. A., Lee R. K. The medical and surgical  
management of pseudoexfoliation glaucoma.  
International Ophthalmology Clinics. 2008;48(4):95–113.