

Peri-papillary retinal nerve fiber layer thickness analysis in pre-clinical diabetic retinopathy using optical coherence tomography

Manjunath B. H.¹, Sunitha M. N. Gowda², Shruti P. Choudhari^{3,*}

¹Professor, ^{2,3}P.G. Student, Dept. of Ophthalmology, JJM Medical College, Davanagere

***Corresponding Author:**

Email: shru.c1990@gmail.com

Abstract

Introduction: Diabetic retinopathy is one of the leading causes of blindness according to vision 2020 protocol. There is evidence of structural changes prior to clinically detectable vascular complications. With newer technologies, like optical coherence tomography (OCT) it is possible to obtain optical section biopsies and it aids in quantifying the effects of diabetic retinopathy on the retinal nerve fibre layer thickness.

Objectives: To establish the role of OCT in evaluating the RNFL thickness in diabetics without clinically evident diabetic retinopathy.

Materials and Methods: This study presents a total of 60 eyes of 60 patients attending the OPD at Bapuji hospital and Chigateri general hospital attached to J.J.M medical college, Davanagere from September 2014 to September 2016. All patients were subjected to RNFL analysis using OCT.

Results: In our study, we found a tendency towards thinning in RNFL thickness globally and significant RNFL thinning in the superior quadrant with increasing duration of diabetes (<5 years-120.24±17.54 and > 5 years-112.88±19.63). No significant change was observed with other variables.

Conclusion: OCT may be used to detect earlier signs and structural changes of DR, leading to earlier diagnosis and intervention. The RNFL loss in diabetics without retinopathy could be an indicator of likely neuronal loss in early DR. Further clarifications are required in this regard, we believe that OCT measurements may be one of the useful methods to elucidate the characterization of early structural changes of DR.

Keywords: Diabetic retinopathy (DR), Retinal nerve fibre layer thickness, OCT.

Introduction

- Diabetic retinopathy and the associated visual dysfunction have been attributed to vasculopathy. It is becoming increasingly clear that neuronal cells of the retina also are affected by diabetes mellitus, resulting in neuronal dysfunction and eventually neuronal degeneration.⁽¹⁾ Studies have found evidence of structural and functional changes prior to clinically detectable vascular complications.⁽²⁾
- Multiple studies support the prospect that RNFL thinning may develop independent to micro-angiopathy and that RNFL can be considered as another potential ophthalmic marker of diabetic retinopathy.⁽³⁾
- Optical coherence tomography (OCT), a noninvasive technique for cross-sectional tomographic imaging of the eye, can reproducibly measure RNFL thickness circumferentially around the ONH. Off late, spectral domain OCT (SD-OCT) has been used to evaluate RNFL thickness.⁽⁴⁾

Materials and Methods

- This prospective protocol adhered to the tenets of the Declaration of Helsinki
- A written informed consent was obtained from all subjects.

Exclusion criteria

- Subjects presenting with any ocular disease or systemic condition known to affect the ONH and

RNFL (e.g., diabetes, neurological disorders) were excluded.

Inclusion criteria:

- Age ≥ 25 years.
- Type II DM without retinopathy changes.
- Spherical equivalent $\leq \pm 6$ diopters.
- Absence of previous ocular surgery.
- IOP < 21 mmhg.
- Cup-to-disc ratio ≤ 0.4 .
- Absence of RNFL defects or optic disc hemorrhage.

Procedure:

- Baseline data included age, gender and self-described race.
- After inclusion, all patients underwent peri-papillary RNFL thickness measurement using SD-OCT (Zeiss CIRRUS™ HD OCT (500)).
- Optic disc cube 200×200 was obtained. Three of the best obtained scans were selected.
- Mean RNFL thickness was recorded globally and separately for the superior, inferior, nasal and temporal quadrants.
- Quality control of the scans was set to ≥ 7 (signal strength, 0-10).

Statistical Analysis

- Categorical variables were analyzed with frequency & percentages. Mean & standard deviation were calculated for continuous variables.
- Comparison of clinical variables with sex difference, Duration of DM as Less than 5 yrs. & more than 5 yrs. was done by Student's unpaired t test.

Results and Discussion

- Sixty subjects with type 2 diabetes mellitus without clinically evident retinopathy (60 eyes) were included in the analysis.
- Mean age was 55.17 ± 11.06 years (range: 30 to 84 years).
- Study included 33 males and 27 females.
- The mean of the average RNFL thickness is $89.50 \pm 10.99 \mu\text{m}$.
- The mean in all quadrants –
 - Superior- $117.05 \pm 18.68 \mu\text{m}$,
 - Inferior- $111.30 \pm 25.84 \mu\text{m}$,
 - Nasal- $70.68 \pm 12.52 \mu\text{m}$,
 - Temporal- $61.70 \pm 12.49 \mu\text{m}$.
- This study showed a tendency towards thinning in RNFL thickness globally and significant RNFL thinning in the superior quadrant (<5 years- 120.24 ± 17.54 and > 5 years- 112.88 ± 19.63) with increasing duration of diabetes.
- No significant change was observed with other variables.

Multiple studies have indicated that neuronal and vascular abnormalities are associated with the pathogenesis of early diabetic retinopathy.⁽⁵⁻⁷⁾

Oshitari et al,⁽⁸⁾ in their immunohistochemical studies of cross-sections of human retinas demonstrated an increase in expression of Bax, caspase-3 and caspase-9 in retinal ganglion cells (RGCs) from diabetic patients, thus suggesting loss of some RGCs via apoptosis.

In our study, we found significant peripapillary RNFL thinning in the diabetic patients with no diabetic retinopathy, which is similar to the observations of Sugimoto et al,⁽³⁾ Lopez de faria et al,⁽²⁾ Peng et al,⁽⁹⁾ Park et al,⁽¹⁰⁾ Xiaofei chen et al.⁽¹¹⁾

Barber et al,⁽¹²⁾ suggested that, apoptosis starts soon after the onset of diabetes mellitus and continues at a relatively constant rate and the apoptotic cells include retinal ganglion cells and other neural cells.

Sugimoto et al,⁽²⁾ reported significant RNFL thinning in the superior quadrant in diabetics with no retinopathy.

Xiaofei chen et al,⁽¹¹⁾ in their meta-analysis of 13 studies (663 subjects) reported a significant reduction of RNFL thickness in the superior quadrant in diabetics without retinopathy as compared to healthy controls.

Aleksandra Araszkiwicz et al,⁽¹³⁾ in their study evaluated patients with type 1 diabetes, with 2 subgroups, i.e., those with diabetic retinopathy and without retinopathy. Compared with patients without

retinopathy, subjects with retinopathy had thinner parafoveal retina, mean RNFL, inferior and nasal RNFL, superior and inferior GCL. Significant correlations were found between duration of diabetes and nasal RNFL thickness and parafoveal retinal thickness. They noted RNFL thinning with increase in duration of diabetes mellitus.

However, Oshitari T et al,⁽¹⁴⁾ in contrast to our study, did not find any significant peripapillary RNFL thinning in diabetics without retinopathy.

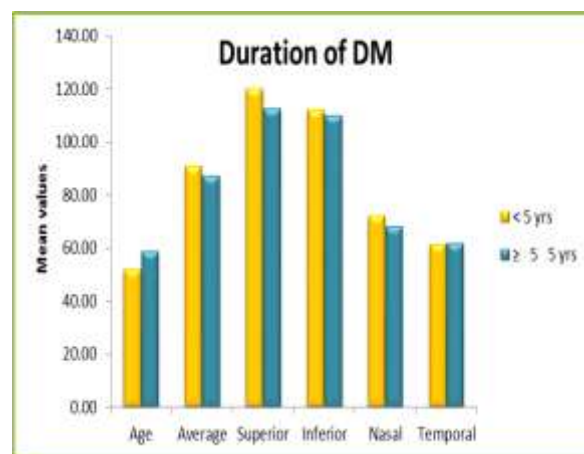


Fig. 1: Comparison of RNFL thickness in each quadrant (in microns) with duration of diabetes mellitus (in years)

Limitations

- Larger population based study is needed to assess the efficacy and significance of this measurement.
- Evaluation of association of diabetic retinopathy with RNFL changes and other systemic correlates like hba1c, hypertension and fasting blood sugar.
- Longitudinal SD-OCT evaluation of diabetic eyes showing progression of the disease is needed to confirm our findings.
- Correlation between structural changes in neural retina and functional change may expand the understanding of the early neurodegenerative process in diabetes.

Conclusion

- The RNFL loss in diabetics without retinopathy could be an indicator of likely neuronal loss in early diabetic retinopathy.
- Measurement of peri-papillary RNFL thickness may become a novel way to evaluate and monitor early retinal changes in diabetic patients and appears to be related to duration of diabetes mellitus.
- Also similar to other studies we noted a vulnerability of superior quadrant to the above changes.

- Multiple studies with larger population are needed to assess the efficacy and importance of this measurement.

References

1. Kern TS, Barber AJ, "Retinal ganglion cells in diabetes" *Journal of physiology* (2008);586:4401-08.
2. Lopes de Faria JM, H Russ, VP Costa, "Retinal nerve fiber layer loss in patients with type 1 diabetes mellitus without retinopathy" *British Journal of Ophthalmology* (2008);86(7):725-28.
3. Masahiko Sugimoto, Mikio Sasoh, Masashi Ido, Yoshikatsu Wakitani, Chisato Takahashi, Yukitaka Uji, "Detection of early diabetic change with optical coherence tomography in type 2 diabetes mellitus patients without retinopathy", *Ophthalmologica* (2005);219(6):379-85.
4. James G Fujimoto, Costas pitris, Stephen A Bopart, Mark E Brezinnski. *Optical Coherence Tomography*, "An emerging technology for biomedical imaging and optical biopsy", *Neoplasia* (2000);2((1-2)): 9-25.
5. Veronica Asnaghi, Chiara Gerhardinger, Todd Hoehn, Abidemi Adeboje, Mara Lorenzi, "A role for the polyol pathway in the early neuroretinal apoptosis and glial changes induced by diabetes in the rat" , *Diabetes*, february (2003);52:506-11.
6. AJ. Barber, Erich Lieth, Sonny A Khin, David A Antonetti, Adam G Buchanan, Thomas W Gardner, "Neural apoptosis in the retina during experimental and human diabetes. Early onset and effect of insulin", *Journal of clinical investigations* (1998);102(4):783-91.
7. Pamela M Martin, Penny Roon, Tracy K Van Ells, Vadivel Ganapathy, Sylvia B Smith, "Death of retinal neurons in streptozotocin-induced diabetic mice", *Investigative Ophthalmology & Visual Science* (September 2004);45(9):3330-36.
8. T Oshitari, S Yamamoto, N Hata, S Roy, "Mitochondria- and caspase-dependent cell death pathway involved in neuronal degeneration in diabetic retinopathy", *British journal of ophthalmology* (2008);92:552-56.
9. Pai-Huei Peng, Huey-Shyan Lin, Shan Lin, "Nerve fiber layer thinning in patients with preclinical retinopathy" (2009) Aug;44(4):417-22.
10. Hae Young-Lopilly Park, In Tae Kim, Chan Kee Park "Early diabetic changes in the nerve fiber layer at the macula detected by spectral domain optical coherence tomography" *British Journal of Ophthalmology* (2011);95:1223-28.
11. Xiaofei Chen, Chuang Nie, Yan Gong, Ying zhangxin Jin, Shihui Wei, Maonian Zhang, "Peripapillary retinal nerve fiber layer changes in preclinical diabetic retinopathy: A Meta-Analysis" *plos ONE* may (2015);10(5): e0125919.
12. Alistair J Barber, Thomas W Gardner, Steven F Abcouwer, "Neural apoptosis in the retina during experimental and human diabetes. Early Onset and Effect of Insulin. *The Journal of Clinical Investigation*" (1994);102(4):783-91.
13. Araszkievicz A1, Zozulińska-Ziólkiewicz D, Meller M, Bernardczyk-Meller J, Piłaciński S, Rogowicz-Frontczak A, Naskręt D, Wierusz-Wysocka B, "Neurodegeneration of the retina in type 1 diabetic patients, *Pol Arch Med Wewn.* (2012);122(10):464-70.
14. T Oshitari, K Hanawa, E Adachi-Usami, "Changes of macular and RNFL thicknesses measured by stratus OCT in patients with early stage diabetes" *Eye* (2009);23: p. 884-89.