

## Clinical indications of penetrating keratoplasty in Punjab

Shakeen Singh<sup>1</sup>, Pawan Prasher<sup>2</sup>, Mandeep Kaur<sup>3,\*</sup>, Arushi Kakkar<sup>4</sup>, Manish Chhabra<sup>5</sup>

<sup>1</sup>Professor & HOD, <sup>2</sup>Professor, <sup>3</sup>Assistant Professor, <sup>4,5</sup>Junior Resident, Sri Guru Ram Das Institute of Medical Sciences & Research, Punjab

**\*Corresponding Author:**

Email: sidhumandeep\_73@hotmail.com

### Abstract

**Purpose:** To study the indications for penetrating keratoplasty (PKP) in Punjab.

**Design:** Retrospective study.

**Methods:** Retrospective analysis of medical records of patients who underwent PKP at Sri Guru Ram Das Institute of Medical Sciences and Research, Amritsar from January 1, 2015 to January 1, 2017 was conducted to study the indications of PKP.

**Results:** A total of 102 eyes of 94 patients were included in the current study, of which 75 (79.78%) were males. The mean age of the patients was  $53.1 \pm 17.2$  (range 15 to 85) years. The most common indication for PKP was corneal opacity in 43 (42.15%) cases, followed by active infectious keratitis in 16 (15.69%), adherent leucoma in 12 (11.76%), bullous keratopathy in 10 (9.8%), failed graft in 9 (8.82%), staphyloma in 6 (5.88%), keratoconus in 1 (0.98%), and miscellaneous causes in 5 (4.9%) cases. Post infectious cause was the most common subcategory in the corneal opacity group, followed by post-trauma and post chemical burns.

**Conclusions:** Corneal opacity, most commonly as a result of post-infectious scarring, is the most common indication for PKP in Punjab. Patient education, preventive measures, and improvement in primary eye health care services are required to reduce the burden of corneal blindness in this region.

**Keywords:** Corneal opacity, Indications, Infectious keratitis, Penetrating keratoplasty

### Introduction

Corneal diseases are amongst the common causes of blindness in developing countries. According to National Programme for Control of Blindness, over 1, 20, 000 people suffer from corneal blindness in India, and about 25000 to 30000 new cases are being added every year.<sup>(1)</sup> Penetrating keratoplasty (PKP) or cornea transplantation, which involves replacement of the diseased cornea with a healthy donor corneal tissue, is the only treatment option in majority of such cases. PKP is one of the most common tissue transplants performed across the globe. The indications for PKP vary with geographical location, socioeconomic status and changing demographic characteristics of a community. A recent review, analyzing the data for over 34 years of PKP performed all over the world, reported that post cataract surgery edema was the predominant indication in north America; keratoconus was the leading indication in Europe, Australia, Middle east, Africa, and South America; whereas keratitis was the primary indication in Asia.<sup>(2)</sup> Also, the indications may show varying trends over a period of time with change in population demographics as well as advancements in surgical techniques. Over the recent two decades, there has been a paradigm shift towards performing lamellar keratoplasty instead of full thickness keratoplasty for pathologies not involving the full thickness of cornea.<sup>(2-4)</sup>

The knowledge about the indications in a particular area is extremely important in terms of planning of eye banking and corneal transplant services in both public and private sectors. Although, there have been few studies from other parts of India,<sup>(5-9)</sup> to the best of

authors' knowledge, a study of this type has not yet been published from Punjab. The aim of the current study was to analyze the current indications of PKP in a medical college in Amritsar, a border district in the state of Punjab, located in north India.

### Methods

A retrospective analysis of the medical records of patients who underwent PKP at Sri Guru Ram Das Institute of Medical Sciences and Research, Amritsar from January 1, 2015 to January 1, 2017 was conducted. The study was approved by hospital ethics committee and followed the tenets of Helsinki declaration. The data points analyzed included patients' age, sex, eye, indications for keratoplasty, type of keratoplasty, and adjunctive cataract surgery with intraocular lens (IOL) implantation. Indications for PKP were categorized into following different groups: corneal opacity (healed post-infectious, post-traumatic and post chemical injury), bullous keratopathy (aphakic or pseudophakic), active infectious keratitis (with perforation or impending perforation), re-grafting (graft rejection, infection or failure), adherent leucoma, anterior staphyloma, keratoconus, corneal dystrophy, and miscellaneous (degenerations, metabolic disorders or tectonic patch grafts for peripheral corneal thinning). In cases, where there were multiple clinical indications, only single primary indication was included in the data analysis.

### Results

A total of 102 eyes of 94 patients were included in the current study of which 75 (79.8%) were males. The mean age of the patients was  $53.1 \pm 17.2$  (range 15 to 85)

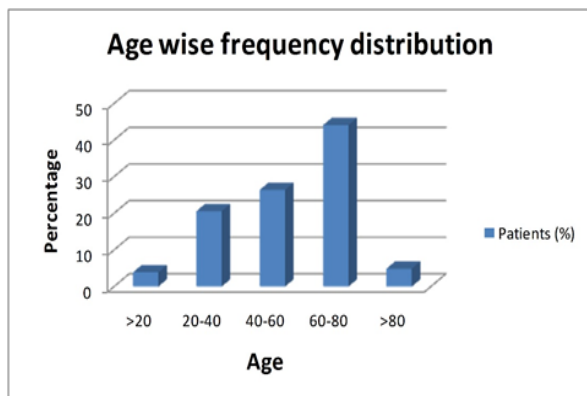
years. Right eye was involved in 54 (52.9%) cases and left in 48 (47.1%) cases. Fig. 1 shows distribution of patients in different age groups. Most of the patients, 78 (77.5%), were more than 40 years of age. The most common indication for PKP was corneal opacity in 43 (42.15%) cases, followed by active infectious keratitis in 16 (15.69%), adherent leucoma in 12 (11.76%), bullous keratopathy in 10 (9.8%), failed graft in 9 (8.82%), staphyloma in 6 (5.88%), keratoconus in 1 (0.98%), and miscellaneous causes in 5 (4.9%) cases (Fig. 2). There was no patient with corneal dystrophy or metabolic disorder related opacification of cornea in this series. Of the 43 patients with corneal opacity, 29 (67.44%) were attributed to be post-infectious, 4 (9.3%) post-traumatic, 2 (4.65%) post chemical burns and 8 (18.6%) due to miscellaneous causes. Table 1 describes the details of surgical procedures performed. Optical PKP was performed in majority (78.4%) of cases followed by therapeutic PKP (20.59%).

**Table 1: Types of Penetrating keratoplasty**

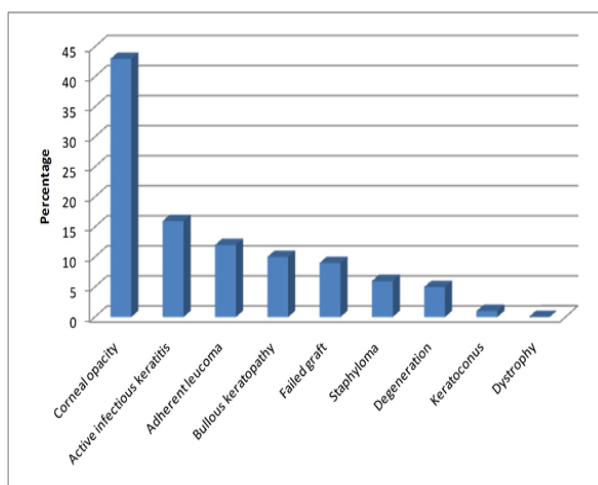
Optical PKP	80 (78.4%)
	Plain optical PKP- 59 (73.75%)
	With ECCE and PCIOL - 15 (18.75%)
	With SFIOL – 2 (2.5%)
	IOL explant and SFIOL- 2 (2.5%)
Therapeutic	21 (20.59%)
	Perforated corneal ulcer – 8 (38.1%)
	Non healing ulcer- 7 (33.33)
	Staphyloma- 6 (2.86%)
Tectonic	1 (0.98%)
PKP- Penetrating keratoplasty, ECCE- Extracapsular cataract extraction, PCIOL- Posterior chamber intraocular lens, SFIOL- Scleral fixated intraocular lens	

**Table 2: Clinical indications of penetrating keratoplasty in different countries**

Study	Region	Corneal opacity	AIK	PBK	ABK	Regrafts	Keratoconus	Corneal Dystrophy	Miscellaneous
Current study	North India	42.15	15.69	8.82	0.98	8.82	0.98		4.9
Sony et al <sup>(6)</sup>	North India	38.03	28.38	6.18	7.27	11.5		3.85	
Raj et al <sup>(7)</sup>	North India	33.1	20.68	24.83	2.06	11.7	0.68	2.75	
Joshi et al <sup>(9)</sup>	Western India	42.54		17.67	12.5	14.36		4.97	7.39
Dandona et al <sup>(5)</sup>	South India	35.6	12.2	10.6	11.8	17.1	6	9.6	5.9
Dasar et al <sup>(8)</sup>	South India	60.7	2.94	2.94	5.88	12.7	4.9		9.8
Dobbins et al <sup>(14)</sup>	USA	11.2		31.5	7.5	8.9	11.4	23.2	
Rahman et al <sup>(15)</sup>	UK		9	21		20	24	14	
Bajracharya et al <sup>(13)</sup>	Nepal	26.8	40.9	9		11.3	7	1.7	
Kanavi et al <sup>(19)</sup>	Iran	18.68		9.19	6.09	5.28	34.51	6.47	
Xie et al <sup>(17)</sup>	China	16	31	13		5	13	4	
Al-Arfaiet al <sup>(20)</sup>	Saudi Arabia	10.7		13.8		9.1	53.1	4.9	
Pariyakanok et al <sup>(10)</sup>	Thailand	20.44	19.15	16.81		10.75		11.08	
Padilla et al <sup>(12)</sup>	Philippines	23.9	17.6	19.7	5.6	9.8			



**Fig. 1: Distribution of patients in different age groups**



**Fig. 2: Frequency distribution of different indications of penetrating keratoplasty**

## Discussion

The current study reports indications of penetrating keratoplasty in Punjab. Corneal opacity, followed by active infectious keratitis, was the leading indication of penetrating keratoplasty in our study. This is in accordance with previous studies from India and other developing nations,<sup>(5-13)</sup> however; this is in contrast with developed countries where bullous keratopathy and keratoconus are the leading indications.<sup>(2-4,14,15)</sup> Table 2 describes the comparison of common indications for PKP in different countries. The reasons for the high prevalence of corneal opacity in the current study can be attributed to higher incidence of corneal trauma, infections including trachoma, Vitamin A deficiency, use of harmful traditional eye medications and home remedies, and lack of access to specialized eye care in our patient population.<sup>(16)</sup>

Active infectious keratitis is the second most common indication in the current series. In contrast, studies from other Asian countries like China<sup>(17)</sup> and Vietnam<sup>(18)</sup> have reported a higher incidence of infectious keratitis as compared to corneal opacity in their PKP patients. We believe both these indications are

inter-related, as corneal opacity quite often is the sequelae of infectious keratitis. So, demographic characteristics of both these groups are likely to be similar as most of the corneas with active infective keratitis without perforation are bound to end up with corneal opacities; and those with perforation result in formation of adherent leucomas or anterior staphylomas. It could be one of the reasons for higher percentage of adherent leucomas and staphylomas in the current series. It could also be the reason for the higher percentage of males in our series, as males are more likely to be involved in outdoor agricultural or other professional works, where they have a higher risk of ocular injuries and secondary infections. Ours is a charitable hospital, which provides free keratoplasty services to all patients irrespective of their socioeconomic status. It could be one of the reasons for referral of active infectious keratitis patients of lower socioeconomic status to our institute, and hence a higher number of therapeutic keratoplasties in the current series.

Bullous keratopathy, mostly due to pseudophakic bullous keratopathy (PBK), was the indication for PKP in 9.8% of patients in the current study. It can be attributed to surgical trauma during cataract surgery; however, unlike studies from developed countries,<sup>(2,4)</sup> most of our patients presented quite late after the cataract surgery and had developed severe subepithelial fibrosis, stromal scarring and pannus formation because of which the option of endothelial keratoplasty could not be considered in these patients. It can be emphasized that ophthalmologists in developing countries should be sensitized about early referral of patients with endothelial decompensation to the cornea surgeons so that less invasive endothelial keratoplasty can be considered in such cases.

We had only one case of keratoconus and no case of corneal dystrophy in the current series. This is in contrast with studies from Middle East,<sup>(19-20)</sup> where keratoconus is a common indication for PKP. The reasons for this difference can be attributed to different genetic and demographic characteristics of our patient population. It is possible that prevalence of keratoconus is low in our area, and a population based study can be helpful in establishing its prevalence in Indian population.

In conclusion, corneal opacity, most commonly as a result of post-infectious scarring, is the most common indication for PKP in Punjab. Patient education, preventive measures, and improvement in primary eye health care services are required to reduce the burden of corneal blindness in this region.

## References

1. National Programme for Control of Blindness. Available from: <http://pbhealth.gov.in/pdf/Blindness.pdf>.
2. Matthaei M, Sandhaeger H, Hermel M, Adler W, Jun AS, Cursiefen C, Heindl LM. Changing Indications in Penetrating Keratoplasty: A Systematic Review of 34 Years of Global Reporting. *Transplantation*. 2016 Jun 22.

3. Park CY, Lee JK, Gore PK, Lim CY, Chuck RS. Keratoplasty in the United States: A 10-Year Review from 2005 through 2014. *Ophthalmology*. 2015 Dec;122(12):2432-42.
4. de Sanctis U, Alovisi C, Bauchiero L, Caramello G, Giroto G, Panico C, Vinai L, Genzano F, Amoroso A, Grignolo F. Changing trends in corneal graft surgery: a ten-year review. *Int J Ophthalmol*. 2016 Jan 18;9(1):48-52.
5. Dandona L, Ragu K, Janarthanan M, Naduvilath TJ, Shenoy R, Rao GN. Indications for penetrating keratoplasty in India. *Indian J Ophthalmol*. 1997 Sep;45(3):163-8.
6. Sony P, Sharma N, Sen S, Vajpayee RB. Indications of penetrating keratoplasty in northern India. *Cornea*. 2005 Nov;24(8):989-91.
7. Raj A, Gupta N, Dhasmana R, Nagpal RC, Bahadur H, Maitreya A. Indications and Visual Outcome of Penetrating Keratoplasty in Tertiary Eye Care Institute in Uttarakhand. *J ClinDiagn Res*. 2016 Jun;10(6):NC01-4.
8. Dasar L, Pujar C, Gill KS, Patil M, Salagar M. Indications of penetrating keratoplasty in southern India. *J ClinDiagn Res*. 2013 Nov;7(11):2505-7.
9. Joshi SA, Jagdale SS, More PD, Deshpande M. Outcome of optical penetrating keratoplasties at a tertiary care eye institute in Western India. *Indian J Ophthalmol*. 2012 Jan-Feb;60(1):15-21.
10. Pariyakanok L, Erjongmanee S, Saonanon P. Indications for corneal transplantation in Thailand between 1996 and 2008. *Asian Biomedicine* 2011 December;5(6):843-848.
11. Tabin GC, Gurung R, Paudyal G, Reddy HS, Hobbs CL, Wiedman MS, Ruit S. Penetrating keratoplasty in Nepal. *Cornea*. 2004 Aug;23(6):589-96.
12. Padilla MB, Eltanal-Pascual MA. Indications for penetrating keratoplasty in the Philippines. *Philipp J Ophthalmol* 2005;30(1):148-52.
13. Bajracharya L, Gurung R, Demarchis EH, Oliva M, Ruit S, Tabin G. Indications for keratoplasty in Nepal: 2005 - 2010. *Nepal J Ophthalmol*. 2013 Jul-Dec;5(2):207-14.
14. Dobbins, Kendall R.B. , Price, Francis W. Jr., Whitson, William E. Trends in the Indications for Penetrating Keratoplasty in the Midwestern United States. *Cornea*. 2000;19(6):813-6.
15. Rahman I, Carley F, Hillarby C, Brahma A, Tullo AB. Penetrating keratoplasty: indications, outcome and complications. *Eye*. 2009;23:1288-94.
16. Gupta N, Tandon R, Gupta SK, Sineevas V, Vashshat P. Burden of Corneal Blindness in India. *Indian J Community Med*. 2013 Oct-Dec;38(4):198–206.
17. Xie L, Song Z, Zhao J, Shi W, Wang F. Indications for penetrating keratoplasty in north China. *Cornea*. 2007 Oct;26(9):1070-3.
18. Dong PN, Han TN, Aldave AJ, Chau HT. Indications for and techniques of keratoplasty at Vietnam National Institute of Ophthalmology. *Int J Ophthalmol*. 2016 Mar 18;9(3):379-83.
19. Kanavi MR, Javadi MA, Sanagoo M. Indications for penetrating keratoplasty in Iran. *Cornea*. 2007 Jun; 26(5):561-3.
20. Al-Arfai KM, Yassin SA, Al-Beshri AS, Al-Jindan MY, Al-Tamimi ER. Indications and techniques employed for keratoplasty in the Eastern province of Saudi Arabia: 6 years of experience. *Ann Saudi Med*. 2015 Sep-Oct;35(5):387-93.