

Isolation of common fungi and treatment of mycotic keratitis

Jayashree S Shah^{1*}, Satya Swapnika Y², MS Padma Jothi³

¹Professor & Unit Head, ²Junior Resident, ³Professor, Dept. of Ophthalmology, Sri Siddhartha Medical College & Hospital, SAHE University, Tumkur, Karnataka

***Corresponding Author:**

Email: drjss13@gmail.com

Abstract

Background: This study was conducted to isolate the common fungi from the corneal ulcer of the patients and to treat fungal keratitis with appropriate antifungal drugs.

Methods: All the patients with corneal ulcer who visited the Ophthalmology OPD at SSMCH, Tumkur were evaluated. Further, all the cases of corneal ulcer were examined with slit lamp biomicroscopy and corneal scrapings taken are subjected to KOH preparation and those with fungal etiology were identified and taken up for the study. The patients were taken into the study irrespective of the previous disease and previous medication.

Results: Out of 20 patients recognised as fungal corneal ulcer, most of the patients belong to the age of 11 to 50 years as they are the working population. The patients with fungal corneal ulcer showed minimal symptoms than signs we lead to delayed avail to treatment. The earliest time the patient visited the hospital after the onset of the disease, was 2 days and the longest duration was 2 months. Those patients with a history of agricultural trauma had either remained negligent in early stage or tried all possible remedies within their easy reach in their initial conditions and come only when the pain became intractable with loss of vision.

Conclusion: A high index of suspicion should be raised in cases with history of trauma and clinical features highly suggestive of fungal corneal ulcer (dry elevated surface, stromal infiltration with hyphate margins). 10% KOH smear is a rapid and sensitive method of diagnosis which is confirmed by SDA cultures that is the most sensitive and specific test available. *Aspergillus* and *Fusarium* are the most common isolates. Fluconazole and Natamycin are the drugs of choice in most filamentous keratitis. Most of the cases heal with some grade of opacity, ultimately requiring a therapeutic Penetrating Keratoplasty to regain useful vision.

Keywords: *Aspergillus*, Corneal ulcer, Corneal opacity, Fungal Keratitis, *Fusarium*, Penetrating keratoplasty

Introduction

The cornea is a tissue specialized to refract and transmit light and is responsive for three quarters of the dioptric power of the eye and hence any injury to it can cause considerable visual disturbances.⁽¹⁻²⁾

The increasing incidence of fungal keratitis is related to: A greater recognition of the clinical features, Improvement in laboratory techniques and better reporting, indiscriminate use of corticosteroids, antibiotics and immunosuppressive drugs. In early stage fungal Keratitis can be confused with other types of corneal ulcers.⁽²⁾ Diagnosis and treatment of fungal Keratitis at the earliest is important in preventing vision threatening complications.⁽³⁾

Mycotic Keratitis due to one or other of the multitude of the species is known to affect man. In India, such infections have long been one of the main ophthalmic problems.^(4,5,6) In the last few decades, the incidence of corneal infections has increased considerably in western countries, which seems to be due to two factors, an upset of the normal symbiosis between bacteria and fungi since the introduction of antibiotics into ophthalmic therapy, and resistance of the tissues from the topical use of corticosteroids which allow fungi normally saprophytic and symbiotic to become facultative pathogens.^(7,8)

In a tropical country like India, It is not uncommon to find infections of the cornea with varied organisms of the soil where agriculture is the main occupation of the

people and mycotic keratitis often encountered in ophthalmological practice.^(9,10,11,12)

The publications on mycotic infections of the eye have been increasing over the past few years as the result of better diagnostic methods and the ability to recognise that fungi which heretofore have been considered non-pathogenic do have the ability to infect the eye. Furthermore, absolute increase in the number of fungus infections has probably resulted from the widespread and indiscriminate use of corticosteroids in ocular therapy.

The consideration of fungal infection today and in the future rests on the historical admonition of earlier workers to keep in mind, not only that proper diagnosis be established, but perhaps of greater importance, to prevent fungal infections. Corneal blindness is a major challenge to the modern world which in majority due to corneal ulcers. So far as ophthalmological lesions are concerned, keratomycosis is of importance because of the ravages it causes leaving the eye blind.⁽¹³⁻²⁰⁾ The ocular mycosis should always be one's guard when one recognizes corneal ulcers.^(21,22)

Regarding the treatment there are various antifungal agents which are available. The problem of therapy of mycotic infections is still today an open chapter. Based on the above background, this study is conducted to isolate the specific fungi of mycotic infections of the cornea.

Materials and Methods

All the patients attending the Ophthalmology OPD with corneal ulcer were examined and those with fungal etiology were identified and taken up for the study. A detailed history was taken in every case including personal information (Name, age, occupation, their residence and their socio-economic status), History of trauma and its nature, foreign body getting into the eye and the nature of foreign bodies (dust, inflorescence, vegetable matter etc.). Previous application of antibiotics, corticosteroids, Antifungals, native medicines etc. was asked and noted. Previous history of any illness especially skin disease of fungal origin was taken to corroborate the present condition wherever relevant

Symptoms of pain, redness, watering, lid swelling, visual disturbance, photophobia, foreign body sensation were recorded.

After a rough general examination a detailed ocular examination was done using slit lamp. The unaffected eye was also examined for pathology. Characteristics of the ulcer were observed and features suggesting of keratomycosis like the dry elevated surface of the ulcer and the stromal hyphate infiltrations were noted. Other features looked for were satellite lesions, endothelial plaques, Anterior Chamber reaction with hypopyon and immune ring.

After examination scrapings from the ulcer were taken at the slit lamp under topical anaesthesia using 4% Xylocaine drops. Smears were made immediately and observed using 10% KOH mount and Grams stain. The specimen was inoculated on Sabouraud's Dextrose agar and cultures were kept at room temperature for 2 weeks before interpreting as negative. Identification of the fungus was made by Lacto phenol Cotton Blue mount from the culture.

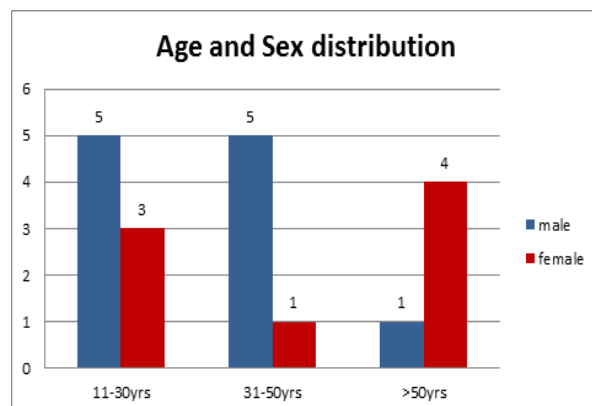
Only those ulcers with corroborative laboratory evidence were taken for study and not just on clinical features or history. All the cases considered for the study were KOH positive irrespective of clinical features, KOH and culture positive and culture positive, irrespective of clinical features and smears.

The cases included in the study were primarily treated with 0.3% fluconazole every 1 hour and tapered with good progress based on KOH smear. Adjuvant therapy in the form of 1% Atropine ointment was used along with Tablet Acetazolamide 250 mg twice or thrice daily (if digital tension was raised) and Vitamin-A & C Tablets were also given. Pad and Bandage was applied and if no improvement noted within 72 hours, 5% Natamycin was added. In cases with raised, dry lesions, a daily or twice a week debridement was done to debulk the fungus load and allow better drug penetration. Daily assessment was made by slit lamp examination and drawings were made.

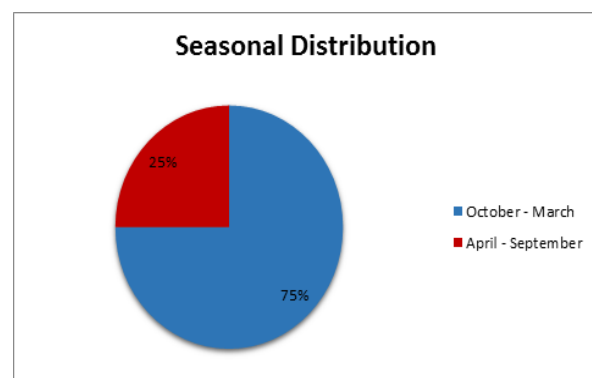
Results

In this study patients who were KOH positive and

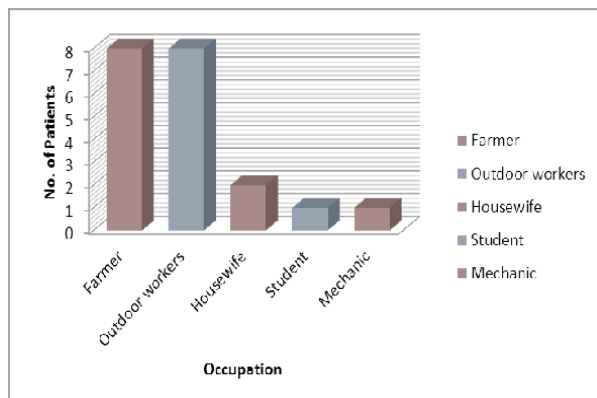
SDA positive were taken. The others were excluded. Total number of Corneal Ulcers examined was 50, out of which 20 cases were of fungal etiology. Most of the affected cases (80%) were observed in the age group of 11 to 50 years, as they are more involved in outdoor and physical activities, the results of which are shown in the following table 1. 60% of the patients were males and most of them belong to low socio economic status.



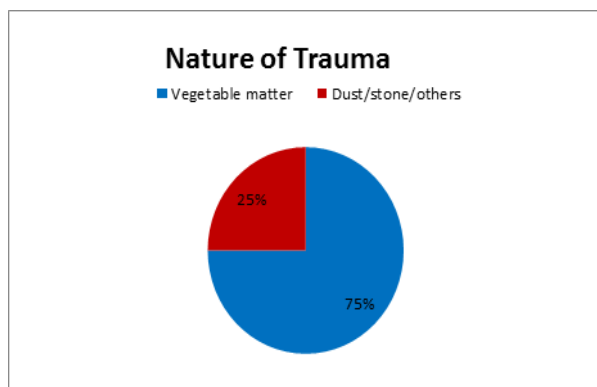
This study showed peak incidence of the fungal corneal ulcer in the months of October- March, as shown in the following Fig.



Farmers and outdoor workers constituted 80% of the cases, as they are more prone to injury with vegetative matter as shown in the following graph.



A definite history was present in 70% of cases. 75% of these were with vegetable matter and 25% with dust/stone. Out of the 15 cases with history of trauma with vegetable matter, most of them were with stick, paddy husk or weed.



Treated by	No	%
General Practitioner	4	20
Ophthalmologist (Ed)	4	20
Native Eye Medicine (TEM)	3	15
TEM + GP	2	10
TEM + Ed	2	10
No Treatment taken	5	25

Post trauma with the vegetative matter only 20% of patients sought treatment within two days, while 65% between 1st and 2nd weeks. This reflects on both the accessibility to health care facilities and negligence. 35% of cases, coming to our hospital, sought treatment between 1-10 days and 50% of cases visited between 11-20 days. The cases which reported later went in for complications like perforation and endophthalmitis.

Type	No.	%
TEM	3	15
Antibiotics	10	50
Antifungals	4	20
Steroids + Antibiotics + antivirals	2	10
TEM + Antibiotics	0	0

Antibiotic + Antifungals	1	5
--------------------------	---	---

Before visiting our OPD, 20% of cases approached another Ophthalmologist while no treatment was taken in 25% of cases. Native medicine was taken in 15% of cases. Treatment was started with Antifungals in 4 cases, out of which one case was started on combination therapy of antifungal with antibiotics. Poor visual outcome was noticed in the cases started on early steroid therapy.

Size in mm	Number	%
<2	3	15
2.1-5.0	15	75
>5	2	10

Depth	Number	%
Anterior 1/3	12	60
Middle 1/3	05	25
Posterior 1/3	03	15

Of the 3 perforated cases, 2 were > 5mm in size and 1 was 4 mm in size, 3 had posterior 1/3rd stromal infiltration. Hence ulcers > 5 mm with posterior 1/3rd stromal infiltration should be cautiously treated with anticipation of complications and therefore all attempts towards corneal preservation should be attempted i.e., conjunctival hood followed by a therapeutic keratoplasty.

Severity was based on the progression, area, depth perforation, scleral suppuration.

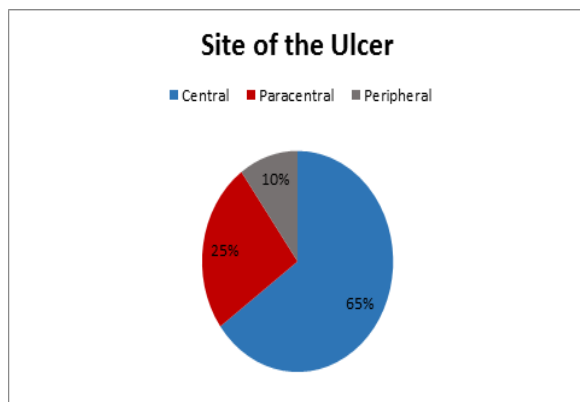
Severity	Number	%
Non-severe	15	75
Severe	05	25

The most common feature was the dry surface of the ulcer followed by hyphate edges, Descemet's folds and hypopyon. Endothelial plaque and immune ring portended poor prognosis but sample size was small.

There was not much significant difference in the number of cases with central and those with paracentral ulcers and of these 18 cases, 13 cases had good visual outcome. Two cases were total ulcers of which one perforated and one went in for endophthalmitis.

Lacrimal syringing and random blood sugars to rule out diabetes was done in all the patients. Patients having chronic dacryocystitis underwent Dacryocystorhinostomy. If Diabetes was diagnosed the patients were treated accordingly.

In this study both Fusarium and Aspergillus were found in equal numbers. The patients who reported to the Hospital early had good response to treatment.



Fungus	Number	%
Fusarium	8	40
Aspergillus	8	40
Curvularia	3	15
Penicillium	1	5
Candida	-	-

Out of the 20 cases, after treatment 18 healed with opacity of which 7 were of macular grade, 6 were of nebular grade and 5 were of leucomatous grade. Of the remaining 2 cases, 1 perforated and 1 case went for endophthalmitis. Outcome of the perforated cases was also observed. Anterior staphyloma was seen in 1 case, Pthisis bulbi in one case and spontaneous reformation of AC with adherent leucoma in 1 case.

Treatment response with antifungals is described as good or poor response as shown in the table below.

Drug	No. of patients	Response	
		Good	Poor
Topical Fluconazole	11	09	02
Topical Fluconazole/ with Natamycin	06	03	02
Topical Fluconazole/ with Nistin	03	03	-

Almost i.e., 55 to 60% of the patients were treated with topical Fluconazole alone had good response. In other patients topical natamycin and nistin were used who did not respond to only fluconazole. In some of the cases except those with impending perforation and deep stromal infiltration, therapeutic debridement was done. Patients with corneal opacity were referred to higher centre for optical keratoplasty.

Discussion

Out of the 50 cases of corneal ulcers, 20 cases were of fungal etiology. Hence one should have a high index of suspicion of fungal etiology. Although males were affected more than females and 10-50 age group affected more, outdoor activity and trauma were the most significant predisposing factors. The earliest time the patient visited the hospital after the onset of the disease,

was 2 days and the longest duration was 2 months. Those patients with a history of agricultural trauma had either remained negligent in early stage or tried all possible remedies within their easy reach in their initial conditions and come only when the pain became intractable with loss of vision.

The diagnosis was missed in early stages when antibiotics were prescribed and precious time was thus lost. Even when fungal ulcer was diagnosed, the frequency of application of antifungals was inadequate. Clinical suspicion should be high in cases of hypopyon corneal ulcers. Dry, elevated appearance and hyphate edges can be considered almost pathognomic of fungal etiology.⁽²³⁻³⁰⁾ Endothelial plaques and immune rings portend poorer prognosis.

Course of the disease, their efficacy could not be assessed. Due to lack of facility and scarcity of donor cornea, therapeutic keratoplasty could not be done and if done would have saved the globe or given some useful vision to the patient.^(30,31,32,33,1,2,8)

Hence, corneal ulcers should be diagnosed with a high index of suspicion especially in patients who have a history of trauma with vegetable matter.

Mixed Bacterial and Fungal infection were found in some of the patients in this study.

Topical Antibiotics were used along with antifungals in patients with mixed bacterial infection.

Amongst the laboratory investigations, SDA was found to be highly sensitive, being positive in 96% of cases and positive in an additional 14% of cases found negative by KOH and Gram Stain. One case with negative on SDA showed positive growth on Chocolate agar providing the importance of multiple media for culture methods. Fusarium and Aspergillus were found in most of cases each. Fusarium presented with greater severity and had poorer prognosis because of its predilection for the posterior chamber.

In this study fluconazole was used as the first line drug in 20 cases. A second drug like topical Natamycin / Nistin was added if no signs of improvement were seen inspite of treatment within one week. Since systemic antifungals were started late in the

Conclusion

Fungal keratitis is an infection of young healthy people, who are more involved in outdoor work and history of trauma to the eye with vegetative matter.^(34-40,2,9,10) A high index of suspicion should be raised in cases with such history and clinical features highly suggestive of it via a dry elevated surface, stromal infiltration with hyphate margins. 10% KOH smear is a rapid and sensitive method of diagnosis which is confirmed by SDA cultures that is the most sensitive and specific test available.⁽⁴¹⁾

Aspergillus and Fusarium are the most common isolates. Fluconazole and Natamycin is the drug of choice in most filamentous keratitis. Most of the cases heal with some grade of opacity, ultimately requiring a

therapeutic Penetrating Keratoplasty to regain some useful vision.

References

- Alfonso E C, Rosa RH Jr: Fungal Keratitis In: Krachmer, Mannis, Holland eds. Cornea, Vol II, Mobsy - Year Book Inc, Missouri, 1997:1253-1263.
- Agarwal Vinay et al: Current Perspectives in Infectious Keratitis, Ind. J. Ophthalmology, Dec 1994, Vol. 42, No.4:3-7.
- Allan B S, Dart J KG: Strategies for the management of Microbial Keratitis Br. J. Ophthal 1995,79:777-786.
- Brishner J II, Burd E M: Principles of Diagnostic Ocular Microbiology In: Tabbara K F, Hynduik RA, eds; Infections of the Eye, 2nd edition Boston/Toronto: Little Brown 1986:69-83.
- Clich T E et al: Fungal Keratitis from Nylon line Lawn Trimmers, Am. J. Ophthalmol, Oct 1992,114:437-440.
- Col. Deshpande et al: Evaluation of Fungal infection in Corneal Ulcer -A Study of 50 cases, Indian Ophthalmology, 1996:10-12.
- Forster R.K. Rebell G: The Diagnosis and Management of Keratomycoses I. Cause and Diagnosis, Arch Ophthalmol 1975,93:975-978.
- Forster R.K. Rebell G: The Diagnosis and Management of Keratomycoses II Medical and Surgical management, 1975,93:1134-1136.
- Forster R K et al: Ocular Toxicity of Topical antifungal agents, Arch Ophthalmol 1981,99:1081-1084.
- Halde C: Ocular Mycology, in Tabbara KF, Hynduik RA, eds. Infections of the eye, Boston / Toronto, Little Brown, 2ⁿ edition, 1986:153-164.
- Ishibashi Y: Oral Ketoconazole therapy for Keratomycosis, Am. J. Ophthalmol, 1983,95:342-345.
- Ishibashi Y et al: Direct examination Vs Culture of biopsy specimens for the Diagnosis of Keratomycosis, Am. J. Ophthalmol, 1987,103:636-640.
- Jones B R: Principles in the management of Oculomycosis. XXXI Edward Jackson Memorial Lecture, Am. J. Ophthalmol, 1975,79,719-751.
- Jones D B et al: Fusarium Solani Keratitis Treated with Natamycin (Pimaricin): Eighteen Consecutive cases, Arch Ophthalmol, 1972,88:147-154.
- Jones D B: Diagnosis and Management of Fungal Keratitis in Tasman William and Jaeger E A eds, Duane's Clinical Ophthalmology, vol-4, Lippincott-Raven Publishers, Philadelphia. New York, Revised edition, 1996:1-19.
- Kaufman H E and Woods R M: Mycotic Keratitis, Am. J. Ophthalmol, 1965,59:993-1000.
- Leisegang TJ: Fungal Keratitis in Kaufman HE, Barron BA, Mc Donald MB eds, The Cornea, 2nd Edition, Butterworth-Heinemann Publication, Boston/Toronto/London. 1998:219-240.
- Maskin SL and Alfonso E; Fungal Keratitis after Radial Keratotomy, Am.J. Ophthalmol, 1992,114(3):369.
- Narsing AR; A Laboratory Approach to Rapid Diagnosis of Ocular Infections and Prospects for Future, Am. J. Ophthalmol, 1989,107:283-285.
- Naumann G et al: Mycotic Keratitis - A Histopathologic study of 73 cases, Am. J. Ophthalmol, 1967,64:668-681.
- O'Brien TP and Peter Rhee: Pharmacotherapy of Fungal Infections of the Eye. In Zimmermann TJ, Koener KS, Sharir M, Fetchner R D ed Textbook of Ocular Pharmacology, Lippincott-Raven Publishers Philadelphia/ New York, 1997:597-607.
- O'Day DM, Burd EM: Fungal Keratitis in Smolin G, Thoft RA, The Cornea, 3 Edition, Little Brown, Boston/Toronto/New York/London, 1994:229-251.
- PK Mohanty et al: Prevalence of Mycotic Infections of External Eye, Indl. J. Ophthal, May 1984,82:153-155.
- Philip A Thomas et al: Oral Ketoconazole in Keratomycosis, Ind. J. Ophthal, 1987,35(4):197-203.
- Prajna V N et al: Use of Traditional Eye Medicines by Corneal Ulcer Patients Presenting to a Hospital in South India, Ind. J. Ophthal 1999,47:15-18.
- Rage N K et al: A Case of Fungal keratitis caused by Scopulariopsis brevicaulis: Treatment with Antifungal agents and Penetrating Keratoplasty, Br. J. Ophthalmol 1990,74:561-562.
- Saunders N: Penetrating Keratoplasty in Treatment of Fungal Keratitis, Am. J. Ophthalmol, 1970,70:24-30.
- Schwartz S D et al: Collagen Shield Delivery of Amphotericin B, Am. J. Ophthalmol, June 1990,109:70-704.
- Savithri Sharma et al: Early Diagnosis of Mycotic Keratitis: Predictive Value of Potassium Hydroxide Preparation, Ind. J. Ophthal, 1998,46:31-35.
- S. Kotigadde et al: Mycotic Keratitis: A Study in Coastal Karnataka, Ind. J. Ophthalmol, Dec 1988,106:708-714.
- Srinivasan M et al: Epidemiology and Etiological Diagnosis of Corneal Ulceration In Madurai, South India, Br. J. Ophthal, 1997,81:965-971.
- Thomas Kuriakose, Philip A T: Keratomycotic Malignant Glaucoma, Ind. J. Ophthal, July-Sept 1991,39(3):118-121.
- Wilhelmus K R et al: Fungal Keratitis in Contact Lens Wearers, Am. J. Ophthalmol, Dec 1988,106:708-714.
- Wilson L A and Sexton R R: Laboratory Diagnosis in Fungal keratitis, Am. J. Ophthalmol, 1968,66:646-653.
- Yee R W, Boone D E, Rinaldi MG: Antifungal agents in Tabbara KF, Hynduik RA eds Infections of the Eye, Boston/Tronto; Little Brown, 2nd Edition 1986:249-264.
- Yee R W et al: Fungal keratitis in Tabbara KF, Hynduik R A eds Infections of the Eye, Boston/ Toronto: Little Brown 2nd Edition 1986:349-356.
- M.J. Bharathi, R. Ramakrishnan, S. Vasu, Meenakshi, R. Palaniappan, Aetiological Diagnosis of Microbial Keratitis in South India - A Study of 1618 Cases. Indian Journal of Medical Microbiology (2002)20(1):19-24. Original Article.
- Lixin Xie, Xianguang Dong, Weiyun Shi Treatment of fungal keratitis by penetrating keratoplasty from BJO Vol. 85, No.9 September 2001, (1070-1074) BJO Vol.5, No. 1, Page 42-46.
- Libowitz Corneal disorders Clinical Diagnosis & Management Second Edition Chapter 26, Fungal Keratitis. Davis M.O. Day Md Page 711-713.
- Spencer Ophthalmic Pathology An Atlas & Text Book 4th Edition, Vol.I Cornea, Page 213.
- Kaufmann the Cornea 2nd Edition Herbert. E. Kaufman - Bruce. A. Barron Margurite. B. Mc. Donald. Cornea, Fungal keratitis Page Thomas J. Liesegang Page 219 to 241.