

Retrospective study of central serous chorioretinopathy in females at tertiary care hospital

Anbuselvi Thirunavukkarasu^{1,*}, Sangamithira Madhiyalagan²

^{1,2}Assistant Professor, Dept. of Ophthalmology, Thanjavur Medical College, Tamil Nadu

***Corresponding Author:**

Email: anbuselvi21@gmail.com

Abstract

Background: Central serous chorioretinopathy (CSCR) is an exudative neurosensory retinal detachment. CSCR can be associated with or without a retinal pigment epithelium detachment. Most of the CSCR patients were found between 20 - 50 years of age. The incidence in male and female is approximately 6: 1. The mean annual age-adjusted incidences per 100000 females were 1.7 and per 100000 males were 9.9.

Aim and Objective: To study the predisposing factors, clinical features and outcome of CSCR in a female population.

Methods: Records of female patients (>20 years of age) who attended the retina clinic with a clinical diagnosis of CSCR between July 2015 to July 2016 were reviewed. Data collected include predisposing factors, visual acuity, Fundus Fluorescein angiographic features, optical coherence tomography features, time to resolution and final outcome.

Results: Data on 37 eyes of 37 patients were analyzed. Females comprised 21.4% of study population with CSCR. Mean age in females was 41.27 years (range 20-51 years) which was significantly greater ($p < 0.01$) than that in males (mean age 32.76 years). Common predisposing factors were steroid use (24%), pregnancy (16%), and hypertension (11%). Ink blot leak was the commonest FFA finding (46%). Patients treated with LASER had faster and better visual recovery.

Conclusion: CSCR tends to occur in older women and time for resolution is more prolonged. Pregnancy and steroid usage are the important risk factors. Early FFA needed to identify the leaks for LASER treatment.

Keywords: Central serous chorioretinopathy, Females, FFA finding, Risk factors, Steroid, pregnancy.

Introduction

Central serous chorioretinopathy is an exudative chorioretinopathy which is characterized by neuro sensory retinal detachment. CSCR can be associated with or without a retinal pigment epithelium detachment. CSCR usually results in micropsia and metamorphopsia. CSCR was recognized by Albrecht von Graefe⁽¹⁾ in 1866. Most of the CSCR patients were found between 20 - 50 years of age. The incidence in male and female is approximately 6: 1. The mean annual age-adjusted incidences per 100000 females were 1.7 and per 100000 males were 9.9.⁽²⁾

Pregnancy is a common risk factor for CSCR in females.⁽³⁾ CSCR is associated with type A personality, stress, exogenous corticosteroids, endogenous corticosteroids, obstructive sleep apnea,⁽⁴⁾ activation of mineralocorticoid pathway⁽⁵⁾ and systemic hypertension. Eplerenone which is used for treatment of hypertension, was found improve visual acuity in CSCR and significantly reduce the central macular thickness.⁽⁶⁾ In one study, within 1 month of presentation 52% of CSCR patients were used exogenous steroids when compared to 18% of control patients.⁽⁷⁾ In one study, the incidence of CSCR among Cushing syndrome was 5% which is higher when compared to general population.⁽⁸⁾ Sildenafil has been found to be associated with CSCR development.⁽⁹⁾ Recurrence rate in the ipsilateral eye was 30%. The incidence of CSCR in the fellow eye was 32%.⁽¹⁰⁾ In a study, H.pylori infection was found to be associated with CSCR.⁽¹¹⁾

CSCR patients have an increased susceptibility to RPE and choroidal hyper permeability with steroids. Autonomic dysfunction may cause focal disturbance in the choroidal circulation.⁽¹²⁾ In these groups, choroidal vasoconstriction which is mediated by epinephrine may cause choroidal ischemia and choroidal hypermeability.⁽¹³⁾ Plasma proteins exudation will cause increase in oncotic pressure which result in RPE malfunction and RPE leak.⁽¹⁴⁾ This outer blood-retinal barrier disruption will lead to detachment of neuro sensory retina.⁽¹⁵⁾ Damage in the RPE active transport mechanisms may play a role in the pathogenesis of CSCR.⁽¹⁶⁾ Clinical features of CSCR are acute onset of central scotoma, micropsia and metamorphopsia. Visual acuity is usually corrected with a minimal hyperopic correction. CSCR cause decrease in color saturation and contrast sensitivity. Macular photo stress recovery time is increased in CSCR.

Contact lens biomicroscopy was used to demonstrate neurosensory retinal detachment. RPE detachments, RPE atrophy, sub retinal lipid and sub retinal fibrin may also been observed. Approximately 90% of CSCR patients recovered vision within 8 weeks due to spontaneous resolvment. Even if Snellen visual acuity returns to 6/6, but subtle nyctalopia, dyschromatopsia and metamorphopsia may persist. Visual acuity may gradually decline with every recurrence. Multiple recurrences of CSCR are associated with cystoid macular degeneration and CNV. The mainstays of CSCR management are observation, laser procedures and photodynamic therapy (PDT).⁽¹⁷⁾

Aim

Overall aim of the study is to evaluate the characteristics of central serous chorioretinopathy (CSCR) in female population.

Objectives

1. Prevalence of CSCR in females as compared to males.
2. To study the predisposing factors and clinical features.
3. To study the time taken for resolution and final visual outcome.

Inclusion criteria: All female patients with clinical diagnosis of CSCR.

Exclusion criteria: CSCR associated with optic disc pit, recurrent CSCR, hypertension, exudative retinal detachment associated with inflammation and renal disease.

Materials and Methods

This hospital based retrospective study was done from July 2015 to July 2016, at the Department of ophthalmology, Thanjavur Medical College, Thanjavur. All consecutive female patients more than 20 years of age who attended the retina clinic with a clinical diagnosis of CSCR were subjected to complete fundus examination with indirect ophthalmoscope and followed up at 1 month, 2 months and 4 months interval.

Diagnosis was made clinically using binocular indirect ophthalmoscope and biomicroscopic examination of the retina (Fig. 1). Data collected include predisposing factors, visual acuity at presentation, Fundus Fluorescein Angiographic features (Fig. 2), optical coherence tomography features (Fig. 3), treatment performed, time to resolution and final visual outcome at 1 month, 2 months, 4 months follow up. Statistical analysis was performed using SPSS software. Chi square test was applied for univariate analysis.

Results

A total of 173 patients attended the retina clinic with the diagnosis of CSCR during the study period. Out of 173 patients, 37 patients (21.4%) were females. (Table 1)

37 eyes of 37 female patients were included in the study and analyzed. Mean age at presentation in females was 41.27 years (range 20-51 years) (Table 2) which was significantly greater ($p < 0.01$) than that in males (mean age was 32.76 years) (Table 3).

Out of 37 females, 26 females were housewives and 11 females were employed (Table 4). Common predisposing factors were steroid use [9(24%)], pregnancy [6(16%)], and hypertension [4(11%)] (Table 5).

Among 37 eyes, the visual acuity recorded on initial presentation was 6/9 in 11 patients (29.7%), 6/12 in 6 patients (16.2%), 6/18 in 7 patients (18.9%), 6/24

in 5 patients (13.6%), 6/36 in 6 patients (16.2%), $>6/36$ in 2 patients (5.4%)(Table 6).

FFA findings (Table 7) among 37 eyes were Ink blot leak [Fig. 2] in 17 eyes (46%), smoke stack leak was in 7 eyes (19%) and no leak in 7 eyes (19%). Ink blot leak was the commonest FFA finding. FFA was not done in 6 pregnant females (16%).

Regarding the management, 21(57%) patients received laser treatment and 16(43%) patients were observed for spontaneous resolution (Table 8). Among the 21 LASER treated patients, 9 patients at 1 month follow up (42.8%), 10 patients at 2 months follow up (47.6%) and 2 patients at 4 months follow up visit (9.6%) have recovered visual acuity of 6/6 [Table 9]. In the observation group(16 patients), number of patients who attained visual acuity of 6/6 at 1 month was 2(12.5%), at 2 months was 4(25%) and at 4 months was 8(50%) [Table 10]. In the observation group visual acuity 6/6 was not attained in 2(12.5%) patients at 4 months follow up.

Table 1: Sex Distribution

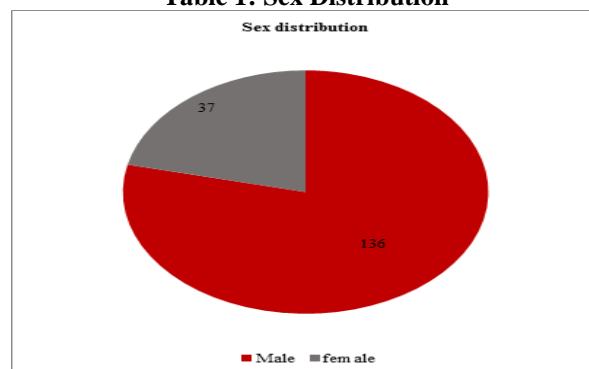


Table 2: Age Distribution in Females

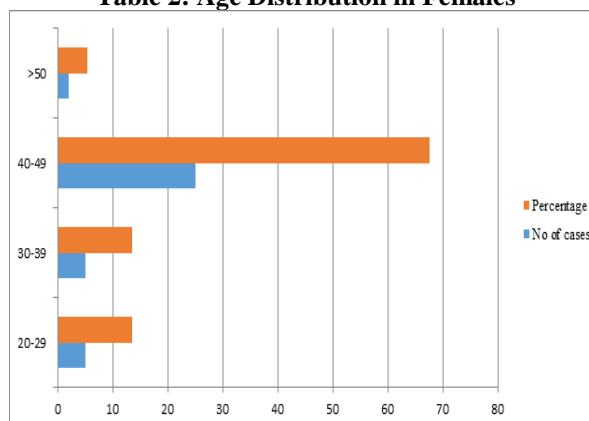


Table 3: Age Distribution in Males

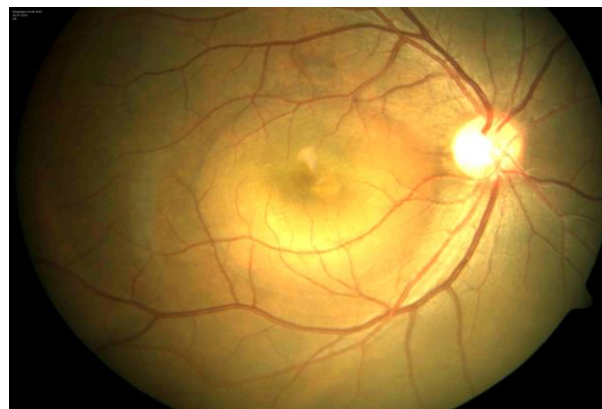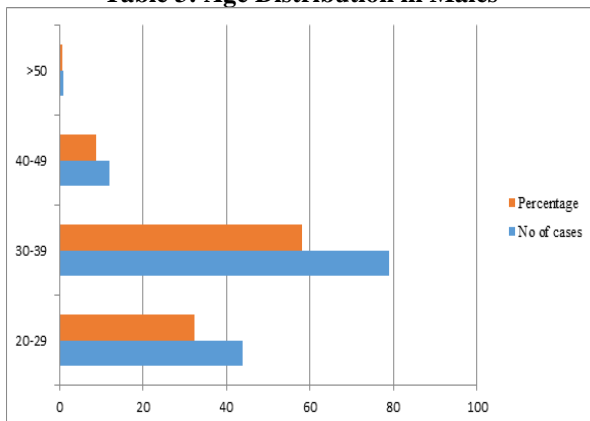


Fig. 1: Fundus Picture

Table 4: Risk factors for CSCR in females

Risk factors	Number	%
Steroid	9	24
Pregnancy	6	16
Hypertension	4	11
Without risk factors	18	49
Total	37	100

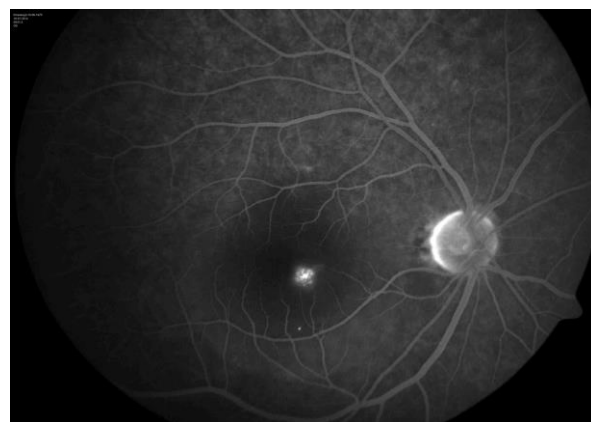

Fig. 2: FFA – Ink Blot leakage

Table 5: Fundus Fluorescein Angiographic features

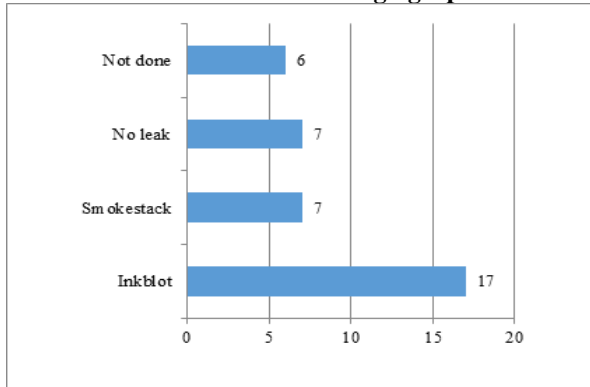


Table 6: Visual Outcome

Visual Outcome of 6/6	No of cases treated with LASER	No of cases under Observation
1 month	9	2
2 months	10	4
4 months	2	8
Not obtained	0	2
Total	21	16

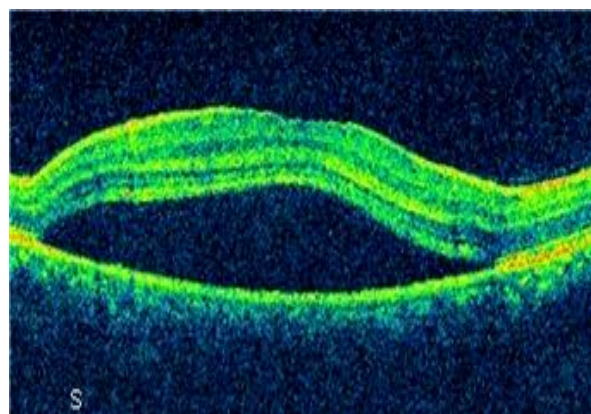


Fig. 3: OCT - CSCR

Discussion

CSCR occurs more frequently in men when compared to women. It has been hypothesized that this is related to job-related stress that is encountered more frequently in males than females. With increasing number of females getting employed, the incidence of CSCR in women would be expected to rise. Females with CSCR were older than males in our study similar to other studies (Quillen et al 1996).⁽¹⁸⁾ Steroid usage has been a known risk factor for CSCR and was associated in 24% of our patients. Pregnancy was associated in 16% of our patients. These associated risk

factors may lead to occurrence of CSCR in elderly females. Half of the patients have no obvious risk factors (48%). The pathophysiological features leading to development of CSCR in these patients remains unclear.

Among various fundus fluorescein angiographic findings, Ink Blot leakage was the commonest feature in our study. The time taken for resolution was earlier in patients who received LASER than in patients kept under observation. The final visual outcome of 6/6 was obtained in all patients who received LASER treatment. In the observation group 12.5% of patients did not attain visual outcome of 6/6 at 4 months follow up. Hence early LASER intervention leads to better visual recovery and resolution was slower in females in our study. During pregnancy, inability to do FFA and to deliver laser may be a possible cause for prolonged resolution time in females in our study. Perkins ET al⁽¹⁹⁾ also found that CSCR takes longer time to resolve in females, especially in older women.

Conclusion

CSCR tends to occur in older women when compared to males. Pregnancy and Steroid usage are the important risk factors. With the increasing proportion of working women the incidence of CSCR in females is expected to increase. Fundus fluorescein angiographic study has to be performed earlier to identify the leaks amenable to LASER treatment for better and earlier visual recovery.

References

1. von Graefe, A. Ueber central recidivierende retinitis. *Graefes Arch Clin Exp Ophthalmol.* 1866;12:211-215.
2. Kitzmann AS, Pulido JS, Diehl NN et al. The incidence of central serous chorioretinopathy in Olmsted County, Minnesota, 1980-2002. *Ophthalmology.* 2008;115:169-173.
3. Haimovici R, Koh S, Gagnon DR, Lehrfeld T, Wellik S. Risk factors for central serous chorioretinopathy: a case-control study. *Ophthalmology.* 2004;111:244-249.
4. Yavas GF1, Kusbeci T, Kasikci M, Günay E, Dogan M, Unlü M, Inan UÜ. Obstructive sleep apnea in patients with central serous chorioretinopathy. *Curr Eye Res* 2014;39(1):88-92.
5. Leveque TK, Yu L, Musch DC, et al. Central serous chorioretinopathy and risk for obstructive sleep apnea. *Sleep Breath.* 2007;11:253-257.
6. Daruich A, Matet A, Dirani A, Bousquet E, Zhao M, Farman N, et al. Central serous chorioretinopathy: Recent findings and new physiopathology hypothesis. *Prog Retin Eye Res.* 2015 Sep. 48:82-118.
7. Bousquet E, Beydoun T, Zhao M, Hassan L, Offret O, Behar-Cohen F. Mineralocorticoid receptor antagonism in the treatment of chronic central serous chorioretinopathy: A pilot study. *Retina* 2013;33:2096-102.
8. Allibhai ZA, Gale JS, Sheidow TS. Central serous chorioretinopathy in a patient taking sildenafil citrate. *Ophthalmic Surg Lasers Imaging.* 2004;35:165-167.
9. Fraunfelder FW, Fraunfelder FT. Central serous chorioretinopathy associated with sildenafil. *Retina.* 2008;28:606-609.
10. Bujarborua, D, Chatterjee, S, Choudhury, A, et al. Fluorescein angiographic features of asymptomatic eyes in central serous chorioretinopathy. *Retina.* 2005;25:422-429.
11. Asensio-Sanchez VM, Rodriguez-Delgado B, Garcia-Herrero E, Cabo-Vaquera V, Garcia-Loygorri C. Central serous chorioretinopathy as an extra digestive manifestation of Helicobacter pylori gastric infection. *Arch Soc Esp Ophthalmol.* 2008;83:177-182.
12. Tewari HK, Gadia R, Kumar D, et al. Sympathetic-parasympathetic activity and reactivity in central serous chorioretinopathy: a case-control study. *Invest Ophthalmol Vis Sci.* 2006;47:3474-3478.
13. Jampol LM, Weinreb R, Yannuzzi L. Involvement of corticosteroids and catecholamines in the pathogenesis of central serous chorioretinopathy: a rationale for new treatment strategies. *Ophthalmology.* 2002;109:1765-1766.
14. Spitznas M. Pathogenesis of central serous retinopathy: A new working hypothesis. *Graefes Arch Clin Exp Ophthalmol.* 1986;24:321-324.
15. Marmor MF. New hypotheses on the pathogenesis and treatment of serous retinal detachment. *Graefes Arch Clin Exp Ophthalmol.* 1988;26:548-552.
16. Marmor M, Tan F. Central serous chorioretinopathy: bilateral multifocal electroretinographic abnormalities. *Arch Ophthalmol.* 1999;117:184-188.
17. Central serous chorioretinopathy: what we have learnt so far KahHie Wong, Kin Pong Lau, Jay Chhablani, Yong Tao, *Acta Ophthalmologica Special Issue: Chinese Ophthalmology and Eye Research Volume 94, Issue 4, pages 321-325, June 2016.*
18. Quillen et al 1996 CSCR I women *ophthalmology* 103;72-79.
19. Perkin et al, clinical characteristic of central serous chorioretinopathy in women *ophthalmology* 2002;109,262-66.