

Clinical profile of cataract patients with co-existent pseudoexfoliation syndrome

MB Dongre¹, Khaire BS², Bhalerao Ravindra³

¹Associate Professor, Dept. of Ophthalmology, SRTR Govt. Medical College, Maharashtra

***Corresponding Author:**

Email: dr.mbd@rediffmail.com

Abstract

Introduction: Pseudoexfoliation syndrome (PEX) is a common and clinically important systemic condition characterized by the pathological production and accumulation of an abnormal fibrillar extracellular material in many intraocular and extraocular tissues. Patients with PEX syndrome have a significantly higher risk for a variety of complications during cataract surgery.

Aim and Objective: To study the clinical profile of cataract patients with co-existent pseudoexfoliation syndrome.

Methodology: 85 patients with Cataract patients diagnosed with pseudoexfoliation on the basis of slit lamp examination. Data includes demographic profile of patient, detailed ophthalmological history and ocular Examination. Visual acuity testing, Slit lamp examination, Gonioscopy, Indirect ophthalmoscopy and Intra Ocular Pressure (IOP) was taken with the help of Schiotz tonometer. Keratometry and A scan was done to calculate IOL power.

Results: Males formed a majority of cases. Majority of the cases were in their sixth decade. In this PEX material was most commonly deposited on Anterior lens capsule 84.7%. Poor pupillary dilatation (<5mm) was seen in as many as 63% cases. 86% eyes had intra-ocular pressure in the range of 14mmHg- 21 mm Hg.

Discussion and Conclusion: PEX material most commonly deposited on anterior lens capsule. Mixed cataract were more common in pseudoexfoliation syndrome.

Keywords: Cataract, Pseudoexfoliation

Introduction

Pseudoexfoliation (PXS, PXF, PEX) syndrome is an age-related systemic disease with primarily ocular manifestations characterized by deposition of whitish-grey, fibrogranular amyloid like material on the anterior lens capsule, zonules, ciliary body, pupillary margin of the iris, corneal endothelium, anterior vitreous and trabecular meshwork.^(1,2) Pseudoexfoliation was first described by Lindberg in 1917⁽³⁾ who said that this material created by earlier inflammation. It was also described by Swiss Ophthalmologist Alfred Vogt in 1918⁽³⁾ who said it as a film on the anterior lens capsule as remnant of pupillary membrane. Evidence states that similar material is also deposited in orbital tissues, skin and visceral organs, long recognized only in the eye because of its visibility on the slit-lamp and the fact that it causes glaucoma.⁽⁴⁾

There is variation in prevalence of pseudoexfoliation. The prevalence may range from 0.4% to 3.8% in south India.⁽⁵⁾ Nuclear cataract and secondarily subcapsular cataract are more frequently found in eyes with PEX than in eyes without PEX.⁽⁶⁾

Patients with PEX syndrome have a significantly higher risk for a variety of complications during cataract surgery which include corneal endotheliopathy, small pupil, zonular weakness, posterior capsule dehiscence, vitreous loss, post-operative spectrum of complications include postoperative IOP spike, corneal edema, posterior capsular opacification, anterior capsular phimosis, macular edema etc. These complications can be minimized by careful pre-operative analysis. Meticulous pre-operative planning, modification of intra-operative techniques such as use

of highly cohesive viscoelastics, pupillary expansion devices and capsular tension devices, etc. can help in reducing the incidence of complications.

There are relatively few studies of cataract patients with pseudoexfoliation syndrome in our settings. Therefore, we conducted this study to see the clinical profile of these patients.

Methodology

Present study was an observational study in a tertiary care hospital in Maharashtra. All Cataract patients diagnosed with pseudoexfoliation on the basis of slit lamp examination in Ophthalmology during study period (December 2014 - November 2016.) were included in the study.

Inclusion Criteria: 1. All patients of either sex with age equal to or more than 50 years diagnosed to have cataract with pseudoexfoliation on the basis of slit lamp examination. 2. Those willing to give voluntary, written consent.

Exclusion Criteria: 1. Patients with traumatic cataract, complicated cataract. 2. Any previous ocular surgery. 3. Patients with advanced glaucomatous optic damage & with preexisting corneal opacity.

Approval from Institutional Ethics committee was taken before starting study. Informed written consent of all patients was taken. Pretested questionnaire was used to collect the data. Data includes demographic profile of patient, detailed ophthalmological history. General examination and systemic examination was done to see for febrile, pallor, icterus, pulse rate, BP, lymphadenopathy and clubbing. Thorough ocular Examination was done. Head position, ocular position

and extraocular movements were examined. Visual acuity testing: best corrected visual acuity (BCVA) was recorded for both distance and near using Snellen's distant and Jaeger's near vision charts respectively. Slit lamp examination of anterior segment was done. Undilated pupillary diameter was measured on slit lamp by narrow beam of light and dim illumination setting in darkened room. Gonioscopy was done with Goldmann 4 mirror gonioscope. Pupillary reaction to rule out posterior segment disorder was seen. Posterior segment evaluation of both eyes, if fundus was visible was done. Indirect ophthalmoscopy was done in patients with advanced cataract having hazy media. Intra Ocular Pressure (IOP) was taken with the help of Schiotz tonometer. Patency of lacrimal duct was tested with sac syringing. Keratometry and A scan was done to calculate IOL power. B scan was advised wherever it was necessary.

Results

Data was collected from a total of 85 patients attending our institute and conforming to regular follow-up.

Table 1: Distribution of patients according to age

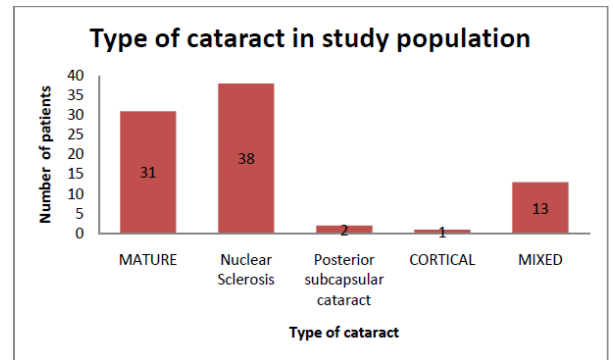
Sr. No	Age group	Patients	Percentage
1	<50	2	2.35
2	51-60	13	15.29
3	61-70	49	57.64
4	71-80	21	24.71
5	Total	85	100

As shown in Table 1. In this study the highest prevalence of PEX syndrome was in the 7th decade 57.6% (n=49). Present study included 59% males (n=50) and 41% females (n=35) with PEX syndrome and cataract. PEX syndrome was found to be unilateral in 55% (n=47) and bilateral in 45% (n=38).

In this study, it is seen that PEX material was most commonly deposited on Anterior lens capsule 84.7% (n=72) followed by the pupillary margin 71.8% (n=61). And least deposition was seen at Iris i.e. in 9.4% (n=8) of cases. In 56.5% (n=48) cases PEX material was seen on both pupillary margin and anterior lens capsule.

In this study 73 eyes had intra-ocular pressure in the range of 14mmHg- 21 mm Hg 86% (n=73). Six eyes had intra-ocular pressure <14mm Hg, and 6 eyes had intra-ocular pressure >21mmHg.

In our study we see that a majority of patients had a poorly dilating pupil, with post mydriasis diameter of 3-5mm in 58.8% (n=50), less than 3mm in 5.8% cases (n=5) while 35.4% cases (n=30) had post mydriasis diameter of more than 5mm.



The prevalence of different types of cataract in our study patients is as follows (Fig. 1) Mixed - two co-existing forms of cataract for e.g. nuclear sclerosis + cortical, etc. Thus, it is evident from the above Fig. 7, that nuclear sclerosis was seen in 38 eyes (44.7%) which is the most prevalent type, followed by mature cataract in 31 eyes (36.4%). Mixed type of cataract was seen in 13 eyes (15.3%). Cortical cataract was least prevalent type, seen in one eye. In this study, out of 85 patients Small Incision Cataract Surgery was done in 65 patients while Phacoemulsification surgery was done in 20 patients. Out of the 85 cases, 83 patients underwent Posterior Chamber Intra-ocular Lens (PCIOL) implantation in the primary sitting. Two patients had to be left aphakic due to zonular dialysis and posterior capsular rent. These 2 patients were referred for secondary scleral-fixated IOL (SFIOL) implantation.

Discussion

In this study number of patients between the age group 60-69 years was 49 (57.6%). These are comparable to the findings of the study done by Yeshigeta et al.⁽⁷⁾ who found incidence of PXF patients above the age of 60 year in 68.8%. These findings are also comparable with the studies of Jawad et al.⁽⁸⁾ (63%), Pranathi et al.⁽⁹⁾ (100%) and Astrom et al.⁽¹⁰⁾ (23%).

In this study, 59% (n=50) patients were male and 41% (n=35) were females. These findings are comparable with the results of Sufi et al.⁽¹¹⁾ who found 68% males and 42% females, Jawad et al.⁽⁸⁾ found 84% males and 16% females, Naseem et al.⁽¹²⁾ found 67% males and 33% females and Pranathi et al.⁽⁹⁾ found 53.8% males and 46.2% females. As evident, preliminarily it appears that PEX syndrome is predominantly a disorder of males, at least in the Indian sub-continent. This might be due to the fact that males seek medical attention (due to cataract) more than females in these regions due to socio-economic reasons. Also, males in rural parts of India are involved extensively in outdoor farm work compared to women, thus exposing them to higher temperatures and solar ultra-violet (UV) rays. UV rays have been implicated in the causal relationship with PEX syndrome.

In our study, anterior lens capsule (85%) and pupillary margin (72%) were the most common sites of deposition of PEX material. Sufi et al.⁽¹¹⁾ reported pupillary margin involvement in 73% of their patients while Yeshigeta and Yemariamwork⁽⁷⁾ reported the same in 92.4% patients. In the APEDS,⁽¹³⁾ it was present in the papillary margins of 58% eyes and on the lens of 63% subjects. This study confirms the fact that pupillary margin and the anterior capsule of lens are the most common sites of PEX deposition. Intra-ocular pressure was within the normal range in 93% (n=79) while 7% (n=6) had increased IOP. Yeshigeta and Yemariamwork⁽⁷⁾ found increased IOP in 28.5% of their patients while Junejo et al.⁽¹⁴⁾ observed the same in 63% of their patients. Low incidence of increased intra-ocular pressure in our study is due to the fact that we excluded patient's having pseudoexfoliation glaucoma, as glaucoma would have confounded post-operative visual outcome.

Pupillary dilatation is poor in patients with PEX syndrome. This was reiterated by our findings where 64.6% of patients had a pupillary diameter of less than or equal to 5mm after pharmacological mydriasis. Jawad et al.⁽⁸⁾ reported 'fair' (5-6 mm) pupillary dilatation in 48% of their subjects. Sufi et al.⁽¹¹⁾ reported statistically significant difference in the preoperative pupillary dilatation between PEX and control group. The same was noted by Hyams et al.⁽¹⁵⁾ (21.2% in PEX group and 6% control group). Once the pupil resists dilatation, the entire process of subsequent cataract surgery becomes challenging. These results indicate that adequate pupil dilatation surgery becomes challenging. These results indicate that adequate pupil dilatation for cataract extraction is more difficult to be obtained in patients with pseudoexfoliation.

This study demonstrated that nuclear sclerosis seen in 44.7% (n=38) was the most prevalent type, followed by mature cataract seen in 36.4% (n=31). Most studies have found nuclear sclerosis to be commonest morphological form associated with PEX syndrome, in Africa⁽⁷⁾ as well as Indian sub-continent.^(13,16,17) However, like this study, Pranathi et al.⁽⁹⁾ observed that combined form of cataract was the most common form occurring in PEX syndrome. It has been hypothesized that high-levels of epithelial metabolic activity may be beneficial for ion pumps and electrolyte environment of cortical fibres, hence these are protected.⁽¹⁶⁾

Conclusion

During this study, males formed a majority of cases. Majority of the cases were in their sixth decade. Poor pupillary dilatation (<5mm) was seen in as many as 63% cases. Combined form of cataract was more common.

References

1. Naumann GO, Schlotzer-Schrehardt U, Kuchle M. Pseudoexfoliation syndrome for the comprehensive

- ophthalmologist. Intraocular and systemic manifestations. *Ophthalmology*. (1998);105:951-968.
2. Schlotzer-Schrehardt U, Naumann GO. Ocular and systemic pseudoexfoliation syndrome. *Am J Ophthalmol*. (2006);141:921-937.
3. Lindberg JG. Clinical investigations on depigmentation of the pupillary border and translucency of the iris in cases of senile cataract and in normal eyes in elderly persons. *Acta Ophthalmol Suppl*. 1989;190:1-96.
4. Basic M, Kastelan S. Pseudoexfoliation syndrome and cataract surgery by Phacoemulsification. *CollAntropol* 2005; 29(Suppl.10):163-6.
5. Arvind H, Raju P, Paul PG, Baskaran M, Ramesh SV, George RJ, et al. Pseudoexfoliation in South India. *Br J Ophthalmol*. 2003;87:1321-3.
6. Andrikopoulos GK, Gartaganis SP. Pseudoexfoliation and Cataract. Published in: 'Cataract surgery'. ISBN:978-953-51-0975-4. Available at: <http://www.intechopen.com/books/cataract-surgery/pseudoexfoliation-andcataract>. last accessed: June 5, 2014.
7. Yeshigeta G, Yenariamwork T. Clinical Characteristics of Cataract Patients with Pseudoexfoliation Syndrome at Jimma University Specialized Hospital, South West Ethiopia. *Ethiop J Health Sci*. Mar 2012;22(1):1-6.
8. Jawad M, Nadeem AU, Khan AU, Aftab M. Complications of cataract surgery in patients with pseudoexfoliation syndrome. *J Ayub Med Coll Abbottabad* 2009;21:33-6.
9. Pranathi K, Magdum RM, Maheshgauri R et al. A study of complications during cataract surgery in patients with pseudoexfoliation syndrome. *J of Clin Ophthalmol Res* 2014;2(1):7-11.
10. Astrom C, Linden S. Incidence and Prevalence of pseudoexfoliation and open angle glaucoma in northern Sweden: I. Baseline report. *Acta Ophthalmol Scand* 2007;85(8):828-31.
11. Sufi AR, Singh T, Mufti AA et al. Outcome of Phacoemulsification in patients with and without Pseudoexfoliation syndrome in Kashmir. *BMC Ophthalmol* 2012;12:1471-2415.
12. Naseem A, Khan S, Khan MN, et al. Cataract Surgery in Patients with Pseudoexfoliation. *Pak J Ophthalmol* 2007;23(3):155-60.
13. Thomas R, Nirmalan PK, Krishnaiah S. Pseudoexfoliation in Southern India: The Andhra Pradesh Eye Disease Study. *Invest Ophthalmol Vis Sci*. 2005;46(4):1170-6.
14. Junejo SA, Jatoti SM, Khan NA, Qureshi MA. Prevalence of Pseudoexfoliation at a Tertiary Eye Care Centre in Sindh, Pakistan: A Hospital based study. *Pak J Med Sci* 2008;24(6):821-6.
15. Hyams M, Mathalone N, Herskovitz M et al. Intraoperative complications of phacoemulsification in eyes with and without pseudoexfoliation. *J Cataract Refract Surg* 2005;31:1002-5.
16. Young AL, Tang WW, Lam DS. The prevalence of pseudoexfoliation syndrome in Chinese people. *Br J Ophthalmol* 2004;88:193-5.
17. Abdul-Rahman AM, Casson RJ, Newland HS, et al. Pseudoexfoliation in a rural Burmese population: the Meiktila Eye Study. *Br J Ophthalmol* 2008;92:1325-8.