

Study of correlation of cup disc ratio with visual field loss in primary open angle glaucoma

Pankaj Soni^{1,*}, Ashwani Srivastava², Akash Srivastava³, Deepti Yadav⁴

¹Assistant Professor, ^{2,3,4}Junior Resident, B.R.D. Medical College, Uttar Pradesh

***Corresponding Author:**

Email: drpankajpbh@gmail.com

Abstract

Objective: To correlate the cup/disc ratio with visual field defect in primary open angle glaucoma patient using magnified photograph of optic disc and Humphrey field analyzer. Method: Cross sectional study includes 114 eyes of 60 patients suffering from primary open angle glaucoma. All patients were 40 years age having IOP 21 mmHg and gonioscopically open angle of anterior chamber. The things assessed includes IOP, angle of anterior chamber, optic disc and visual field.

Results: Total 114 eyes of 60 patients with primary open angle glaucoma included in study. Mean age of patient in our study was 58.7±10.26 year. Out of 60 patients, 31 (51.66%) were male and 29 (48.33%) were female. 12 eyes (10.52%) had IOP in the range of 21-24 mmHg, 52 eyes (45.61%) had IOP in the range of 25-29 mmHg, 48 eyes (42.10%) had IOP in the range of 30-34 while only 2 eyes (1.75%) had IOP > 35 mmHg. Mean IOP of 114 eyes was 27.9±3.23 mmHg. 32 patient (28.07%) had C:D ratio of 0.6 whereas 30 patient (26.31%) had C:D ratio 0.7. Mean C:D ratio of POAG was 0.64±0.07. Considering other parameter of the optic nerve head it was seen that Bayonetting sign was present in 60 eyes. Meanwhile baring of vessels was seen in 46 eyes. Lamellar dot sign, on the other hand was seen in 72 eyes. Beta zone peripapillary atrophy was seen in 78 eyes. Another important parameter of the optic disc is notching. In 53 eyes notching was seen. Out of these, 35 eyes show superior notching, of which 33 eyes (94.3%) correlated with inferior field defects. 18 eyes show inferior notching, and all of them showed superior field defect. Inferior neuroretinal thinning is found in 55 eyes, out of which 50 eyes (90.9%) had correlating visual field defect while 32 eyes (86.5%) with superior neuroretinal thinning correlate visual field defect. Maximum number of eyes show superior zone defect i.e. 54 eyes (47.36%) followed by inferior zone defect in 25 eyes (22.0%). The least common visual field defect in our study is baring of blind spot in 3 eyes (3.0%). Finally, the patients were divided into 2 group depending on their cup disc ratio, and their association with the field defects was evaluated. Group 1- patients with c:d ratio < 0.7; Group 2- patients with c:d ratio 0.7. The pattern defects signifying the localized defects were then compared between the two group. The average pattern defect in group- 1 was found to be 6.16 db, while the average pattern deviation in group- 2 was 9.62 db. The association of c:d ratio 0.7 with PD was seen to be significant with a p < 0.001. Conclusions: This was a cross sectional study done over a period of 1 year to correlate the optic disc changes with the visual field defects by using optic disc evaluation and Humphrey visual field analyzer done. The correlation between cup disc ratio and intra.

Keywords: Cup disc ratio, Gonioscopy, Neuroretinal rim, Bayonetting sign, Peri papillary atrophy

Introduction

Chronic Open Angle Glaucoma (COAG) may be defined as a chronic progressive optic neuropathy accompanied by characteristic visual field defects and disc changes, with intraocular pressure being the commonest risk factor. By definition there is no apparent obstruction of the trabecular meshwork by structures such as the iris on gonioscopic examination.

Glaucoma is the leading cause of irreversible blindness in the world. World Health Organization statistics, published in 1995, indicate that glaucoma accounts for blindness in 5.1 million persons, or 13.5% of Global Blindness. According to world health organization Glaucoma is the second leading cause of blindness in the world.

The common denominator of all the glaucomas is characteristic Optic Neuropathy, which derives from various risk factors including increased intraocular pressure (IOP). Although elevated intraocular pressure is the most frequent causative risk factor for glaucomatous optic neuropathy, it is not the only factor.

Once the blindness of glaucoma has occurred, there is no known treatment that will restore the lost vision.

However, in nearly all the cases, blindness from glaucoma is preventable. This prevention requires early detection and proper treatment. Detection depends on the ability to recognize the early clinical manifestations of the various glaucomas.

The most important component of the constellation of signs and symptoms of glaucoma is the characteristic visual field loss along with the typical glaucomatous optic neuropathy which presents as an asymmetric loss of the neuroretinal rim of the optic nerve head, widening of the cup, baring of the lamina cribrosa, pallor of the neuroretinal rim, peripapillary atrophy, and later cavernous atrophy of the optic nerve head. On Direct Ophthalmoscopy, the above signs can be elucidated. Examination by Direct Ophthalmoscopy under a red-free light also reveals the slit or later the wedge shaped defects in the nerve fiber layer.

Glaucomatous optic atrophy

Focal Atrophy: Selective loss of neural rim tissue in glaucoma occurs primarily in the inferotemporal region of the optic nerve head and, less commonly in the superotemporal sector leading to enlargement of cup in

a vertical or oblique direction. The focal atrophy of neural rim often begins as a small, discrete defect referred to as polar notching. When the local thinning of neuroretinal rim tissue reaches the disc margin a sharpened rim is said to be produced. If a retinal vessel crosses the sharpened rim it will bend sharply at the edge of the disc- bayonetting at disc edge².

Deepening of the cup: Exposure of the underlying lamina cribrosa by the deepening cup is often recognized by the grey fenestra of the lamina which is referred to as the laminar dot sign.

Pallor/ Cup Discrepancy: In the early stages of glaucomatous optic atrophy, enlargement of the cup may progress ahead of the area of pallor. The ultimate result of glaucomatous optic atrophy is total cupping, seen as a white disc with loss of all neural rim tissue and bending of all vessels at the margin of the disc.

Vascular Signs: Splinter hemorrhages, usually near the margin of the optic nerve head, are a common feature especially in normal tension glaucoma. In many normal optic nerve heads, one or two vessels may curve to outline a portion of the physiologic cup. With glaucomatous enlargement, these circumlinear vessels may be barred from the margin of the cup. Peripapillary changes associated with glaucomatous optic atrophy- loss of axonal bundles produces visible defects in the nerve fiber layer which appear as dark strips or wedge shaped defects of varying width in the peripapillary area. They often correlate highly with visual field defects.

Typical Glaucomatous Visual Field Defects

1. **Scatter:** patients with glaucomas have substantially greater scatter during one examination (short term fluctuation) as well as from one test to another (long term fluctuations). It is an early warning sign of impending absolute field loss.
2. **Paracentral Defects:** Field defects appear first as one or more localized defects or paracentral scotomas in the Bjerrum's area.
3. **Seidel's Scotoma:** the early paracentral scotoma may connect with the blind spot and taper to a point in a slightly curved course, called as Seidel's scotoma.
4. **Arcuate/ Bjerrum's Scotoma:** as the defects enlarge and coalesce, they form an arching scotoma that eventually fills the entire arcuate area from the blind spot to the median raphe, which is called an Arcuate or Bjerrum Scotoma.
5. **Ring Scotoma:** with further progression, a double arcuate (or ring) scotoma will develop. The larger the scotoma the more rapidly it is likely to enlarge.
6. **Nasal Step:** The loss of retinal nerve fiber rarely proceeds at the same rate in the upper and lower portions of an eye. Consequently a step like defect is frequently created where the nerve fibers meet along the median raphe. Unequal contraction of the peripheral isopters due to loss of corresponding bundles of peripheral arcuate nerve fiber produces

the peripheral nasal step of Ronne. A stepwise defect along the vertical midline, referred to as a vertical step or a hemianopic offset, is a less common feature of glaucomatous field loss but has been reported to occur in approx. 20% of cases.

7. **Advanced glaucomatous field defects:** Field loss eventually develops into a complete double arcuate scotoma with extension to the peripheral limits in all areas except temporally. This results in a central island and a temporal island of vision in advanced glaucoma. With continued damage these islands of vision progressively diminish in size until the tiny central island is also totally extinguished.

Materials and Methods

This was a cross sectional study conducted in department of ophthalmology from January 2015 to December 2015 to correlate cup disc ratio with visual field defects by observing magnified fundus photographs and using Humphrey's visual field analyzer SITA standard 30-2 program. All diagnosed primary open angle glaucoma patient and glaucoma suspect attending ophthalmic OPD and IPD in NEHRU hospital attached to BRD Medical College were included in this study. The procedure and investigation were explained to the patient and informed consent was taken. A total of 60 patients who fulfilled the following inclusion criteria were included in the study.

Inclusion criteria

1. A known diagnosis of primary open angle glaucoma
2. Patients older than 40 yrs of age
3. A SCHIOTZ tonometry intraocular pressure > 21 mm Hg
4. Gonioscopically open angle
5. A combination of optic disc changes like cupping, notching, thinning or pallor of neuroretinal rim suggestive of POAG.

The following patients were excluded from the study—Participants not willing to give informed consent, Refractive error of > 5 dioptres of sphere or 2.5 dioptres of cylinder, History of amblyopia, History of any disease or trauma to the eye being tested, History of use of any medication that may affect the visual field, Patients with dense cataract, Eyes with any retinal pathologic condition that may affect visual field, Suspicious appearing optic nerve or visual field defect associated with identifiable cause such as chorioretinal scar.

After obtaining informed written consent, a comprehensive evaluation of an individual with glaucoma was begun with eliciting detailed history which includes a review of the family and ocular and systemic history, use of systemic and ocular medication, past ocular surgery and known local and systemic intolerance to the use of glaucoma medication.

All patients were examined thoroughly and refraction, IOP (with Schiottz tonometer), gonioscopy

(with Goldmann 3 mirror gonioscopic lens), optic disc evaluation (with a slit lamp and 90D lens and magnified photographs were taken with a KOWA retinal digital camera), visual field evaluation (with Humphrey visual field analyzer) done in all patients. Using the Humphrey visual field analyzer (Zeiss), SITA standard test using program 30-2 and a size 3 stimulus on a white background was performed. Calculation of the total and pattern deviation plot and global indices was done. Mean deviation and pattern standard deviation were derived using STATPAC for SITA.

Results

Total 114 eyes of 60 patients who fulfilled the inclusion criteria were selected for study. Eyes were examined for optic nerve head changes and visual field defects included in all the analysis of the result.

Table 1: Age Distribution

Age group	No. of patients	Percentage
40-49	8	13.33%
50-59	20	33.33%
60-69	22	36.66%
70-79	9	15.00%
>80	1	1.66%
Total	60	

In our study maximum number of patient belonged to 6th and 7th decade of age. Mean age of patient in our study was 58.7±10.26 year.

Table 2: Sex Distribution

Sex	Number of patient	Percentage
Male	31	51.66%
Female	29	48.33%
Total	60	

In the present study of 60 patients, 31 (51.66%) were male and 29 (48.33%) were female.

Table 3: Intraocular pressure (IOP mm Hg) distribution

IOP (mm Hg)	Number of eyes	Percentage
21-24	12	10.52%
25-29	52	45.61%
30-35	48	42.10%
>35	2	1.75%
Total	114	100%

In the present study, 12 eyes (10.52%) had IOP in the range of 21-24 mmHg, 52 eyes (45.61%) had IOP in the range of 25-29 mmHg, 48 eyes (42.10%) had IOP in the range of 30-34 while only 2 eyes (1.75%) had IOP > 35 mmHg. Mean IOP of 114 eyes was 27.9±3.23 mmHg.

Table 4: Cup: disc ratio distribution

C:D Ratio	Number of Eyes	Percentage
0.4	6	4.16%
0.5	20	17.54%
0.6	32	28.07%
0.7	30	26.31%
0.8	23	20.17%
0.9	3	2.63%

Out of 114 eyes in our study, 32 patient (28.07%) had C:D ratio of 0.6 whereas 30 patient (26.31s%) had C:D ratio 0.7. Mean C:D ratio of POAG was 0.64±0.07.

Table 5: Distribution of the various optic nerve head parameters

Disc Parameters	No. of eyes
Bayonetting	60
Baring of vessels	46
Laminar dot sign	87
Peripapillary atrophy (alpha zone)	72
(beta zone)	78

Considering other parameter of the optic nerve head it was seen that Bayonetting sign was present in 60 eyes. Meanwhile baring of vessels was seen in 46 eyes. Laminar dot sign, on the other hand was seen in 72 eyes. Beta zone peripapillary atrophy was seen in 78 eyes.

Table 6: Distribution of notching in patients and their correlation with field defects

Notching	No. of eyes correlate with visual field defect	No. of eyes not correlate with visual field defect
superior	33(94.3%)	2 (5.7%)
inferior	18(100%)	-

Another important parameter of the optic disc is notching. In 53 eyes notching was seen. Out of these, 35 eyes show superior notching, of which 33 eyes (94.3%) correlated with inferior field defects. 18 eyes show inferior notching, and all of them showed superior field defect.

Table 7: Distribution of neuroretinal rim (NRR) thinning amongst the various cases

Neuroretinal rim thinning	No. of eyes correlating with visual field	No. of eyes not correlating with visual field	Total
superior	32(86.5%)	5	37
inferior	50(90.9%)	5	55
Temporal	8(80.0%)	2	10
nasal	2(40.0%)	3	5

In the present study inferior neuroretinal thinning is found in 55 eyes, out of which 50 eyes (90.9%) had correlating visual field defect while 32 eyes (86.5%) with superior neuroretinal thinning correlate visual field defect.

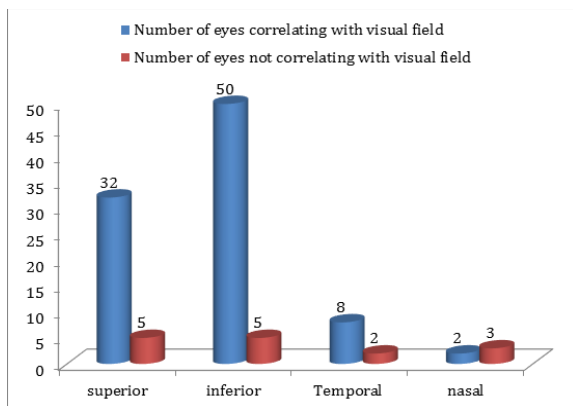
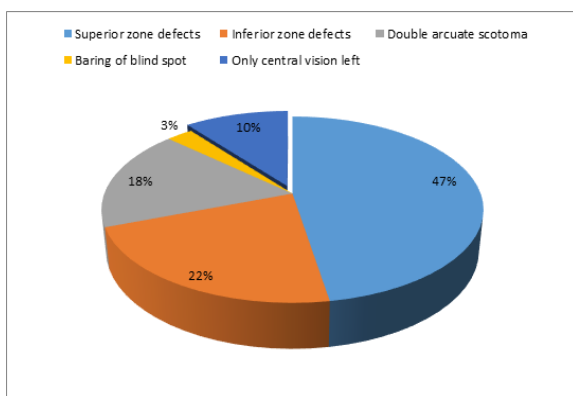


Table 8: The distribution of the various field defect

Field defects	No. of eyes
Superior zone defects	54
Inferior zone defects	25
Double arcuate scotoma	20
Baring of blind spot	3
Only central vision left	12



In the present study, maximum number of eyes show superior zone defect i.e. 54 eyes (47.36%) followed by inferior zone defect in 25 eyes (22.0%). The least common visual field defect in our study is barring of blind spot in 3 eyes (~ 3.0%).

Table 9: Mean field defect in patient with different cup disc ratio

Cup disc ratio	Mean field defect
0.4	-16.05
0.5	-17.46
0.6	-17.62
0.7	-18.50
0.8	-18.91
0.9	-19.24

In present study with increased cup disc ratio mean visual field defect increase.

Table 10: Pattern visual field defect in patient with various cup disc ratio

Cup Disc Ratio	Pattern field defects
0.4	3.74
0.5	6.40
0.6	8.50
0.7	8.38
0.8	10.13
0.9	12.14

The pattern deviation showed a significant increase with a corresponding increase in cup disc ratio.

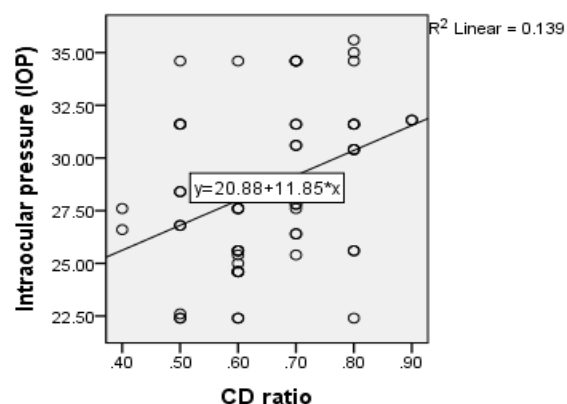
Table 11: Correlation between IOP (mmHg) and C:D ratio

Right Eye

Pearson correlation values

$r = 0.358$

$p = 0.006$

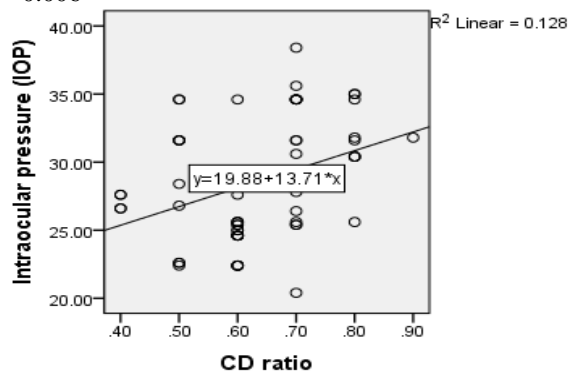


Left Eye

Pearson correlation values

$r = 0.361$

$p = 0.006$



The relationship between CD ratio and IOP was calculated using linear regression analysis with X = CD ratio and Y = IOP. The Present study shows there is a weak co-relation between IOP and CD ratio and this is statistically significant ($p < 0.05$).

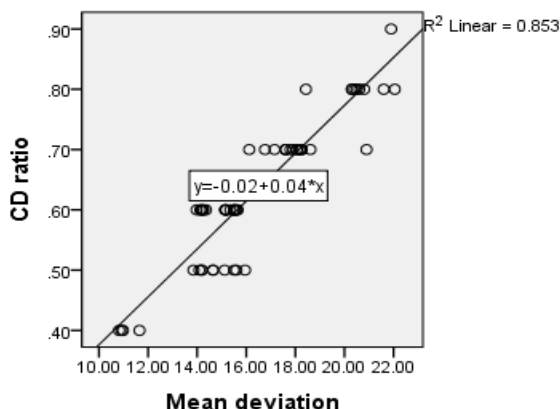
Table 12: Graph showing correlation between CD ratio & Mean Deviation by using linear line plotted against least square method

Right Eye

Pearson correlation values

$r = 0.923$

$p < 0.001$

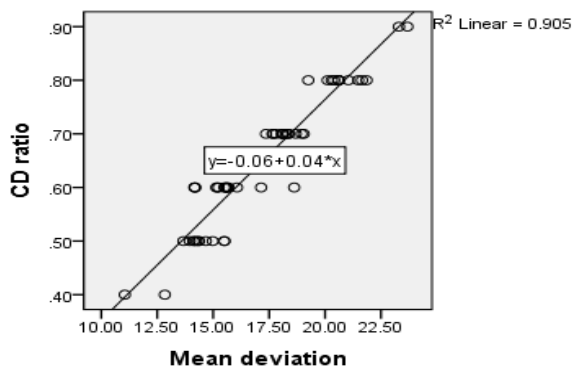


Left Eye

Pearson correlation values

$r = 0.951$

$p < 0.001$



In the present study when the increasing mean deviation (db) was correlated with larger cup disc ratio using pearson correlation value r , it was found to be statistically significant $p < 0.001$.

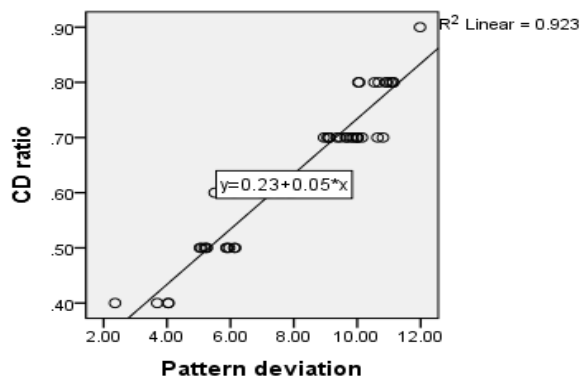
Table 13: Graph showing correlation between CD ratio & Pattern by using linear line plotted against least square method

Right Eye

Pearson correlation values

$r = 0.961$

$p < 0.001$

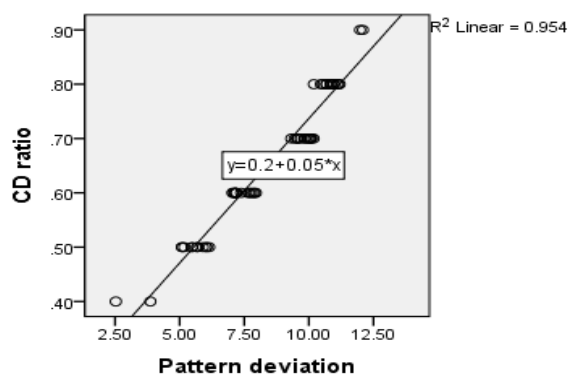


Left Eye

Pearson correlation values

$r = 0.977$

$p < 0.001$



In the present study by using least square method and pearson correlation value it was observed that cup disc ratio is positively correlated with pattern deviation which is statistically significant $p < 0.001$.

Finally, the patients were divided into 2 group depending on their cup disc ratio, and their association with the field defects was evaluated.

Group 1- patients with c:d ratio < 0.7

Group 2- patients with c:d ratio ≥ 0.7

The pattern defects signifying the localized defects were then compared between the two group. The average pattern defect in group- 1 was found to be 6.16 db, while the average pattern deviation in group- 2 was 9.62 db.

Table 14: Evaluation of significance of association between C:D ratio ≥ 0.7 with PD

C:D ratio	Mean pattern defect	SD
< 0.7	6.16 db	0.067
≥ 0.7	9.62 db	0.062

The association of c:d ratio ≥ 0.7 with PD was seen to be significant with a $p < 0.001$.

Discussion

The present cross sectional study included 114 eyes of 60 patients of primary open angle glaucoma (POAG), who fulfilled the inclusion criteria.

Visual field analysis and optic disc evaluation are critical features used in the diagnosis and management of glaucoma. SITA standard white-on-white automated perimetry is currently the gold standard for the diagnosis, grading and detection of progression of glaucomatous visual field defects in primary open angle glaucoma. These procedures make it possible to identify the occurrence of a diffuse or localized depression of retinal sensitivity and structural damage to the optic disc.

In glaucoma patients, it is important to detect glaucomatous visual field loss and begin adequate treatment as early as possible. In most cases, the optic disc changes occur prior to the visual field loss, so the optic disc assessment is a very important part of the evaluation of glaucoma and ocular hypertension. Glaucomatous optic atrophy leads to morphological changes in the disc such as loss of neuroretinal rim, deepening of the optic disc, barring of lamina cribrosa pores, enlargement of the peripapillary atrophy and localized and diffuse loss of the retinal nerve fibre layer and psychophysical defect such as visual field defect.

Only a few studies have correlated the visual field defect with the morphometric disc changes among patients with glaucoma and their results indicate that measurable optic disc changes precede visual field loss in early as well as in advanced glaucoma. Serial optic disc evaluation seems not as sensitive as visual field examination. Due to some inherent errors in visual field examination in previous studies, it may have contributed to incorrect predictions.

Therefore, the current study was done to correlate the optic disc parameters with visual field defect by assessing the optic disc and looking for the features of the optic disc commonly associated with visual field loss by Humphrey visual field analyzer 2 using Swedish Interactive Threshold Algorithm (SITA) program.

When the age distribution was studied in our 60 patients of primary open angle glaucoma, the youngest patient was of 43 years and the oldest one was of 83 years. The mean age of the studied population was 58.7 years with a standard deviation of 10.2 years. Suzuki et al in his study found the mean age of 119 POAG patients was 63.8 ± 12.0 years. Gyasi et al in his study found that the mean age of the studied population was 53.2 ± 16.3 years which was slightly lower because the mean age of onset of POAG is usually lower in African population than Asian population.

The influence of gender on glaucoma has not been as straight forward as may be expected. Results from different prevalence studies have not been conclusive in showing gender preponderance as some studies report male prevalence of POAG to be twice as high as female or vice versa while other report no such association at all. In the present study 60 patients, 31 (51.66%) were male and 29 (48.33%) were female showing no gender preponderance. Hong et al in his study, found that POAG showed a slightly higher frequency of occurrence in male (54.2%).

Intraocular pressure remains the most significant risk factor for POAG and indeed the only risk factor that can be currently modulated. The mean IOP of 114 eyes of 60 patients in the present study was found to be 29.92 ± 3.23 mm Hg. Chul Hong et al in his clinical study of 206 Korean glaucomatous patients found that mean IOP of POAG patient was 33.4 ± 15.5 mm Hg. In our study the mean IOP of 114 eyes was slightly lower may be due to the fact that maximum number of patients included in this study were known POAG patient already on antiglaucoma medication.

The cup disc ratio is the parameter that is used to define glaucoma and is also considered as a risk factor as many studies have reported a larger cup disc ratio in POAG patients. Mean cup disc ratio in 114 eyes of 60 patients was 0.64 ± 0.12 . Wensor et al in the study of prevalence of glaucoma in the Melbourne visual impairment project found that in 56 diagnosed POAG patients the mean C:D ratio was 0.74 with standard deviation of 0.28 which was similar to the result of our study.

In the study by Gyasi et al on presentation pattern of primary open angle glaucomas in North Eastern Ghana more than seventy percent eyes had cup disc ratio greater than 0.8. While in our study only 48.32% of patients has cup disc ratio of more than 0.7.

While considering other parameters of the optic nerve head, it was seen that most accurate predictor of visual field loss was the presence or absence of notching. Notching was present in 35 cases in superior quadrant, out of which corresponding inferior field defect were correctly predicted in 94.3% cases. 18 cases had inferior quadrant notching and all of them showed corresponding visual field defects. Thus inferior quadrant notching was even more accurate predictor of visual loss. These result are in accordance with those of Hitchings and Spaeth, even though they found greater accuracy in predicting inferior field defects. They achieved 83.5% and 91% accuracy in predicting superior and inferior defects respectively.

Neuroretinal rim thinning was another important predictor of glaucomatous field loss. In 86.5% of cases with superior NRR thinning, and in 90.9% of cases with inferior NRR thinning, field defects was correctly diagnosed. But it was seen that when temporal and nasal neuroretinal thinning was seen, the accuracy of prediction of field defect dropped considerably with only 50% accuracy seen in predicting field defects. One of the reason for this could be the physiological variation in the shape of the optic disc cup, resulting in a higher variability of the horizontal NRR seen physiologically. Moreover, this finding also emphasizes the fact that vertical cup disc ratio or vertical NRR is a more important indicator of glaucomatous damage, as compared to horizontal NRR.

The pattern of visual field loss in eyes with early damage is of utmost importance because it can facilitate our understanding of the pathophysiology of

glaucomatous optic nerve damage. In the present study, in the distribution of the visual field defects, out of 114 eyes of 60 patients with POAG more number of eyes had superior scotoma than inferior scotoma followed by tubular vision and double arcuate scotomas. While the visual field scotoma distribution of open angle eyes in Tabriz and Graz⁽⁴⁵⁾ showed that the most common visual field defect was nasal and peripheral scotoma beyond 20 degree of fixation.

It was found that higher the intraocular pressure, the larger the cup disc ratio. In the present study, by least square method we were able to correlate them but found that there was a weak correlation between the IOP and cup disc ratio with pearson correlation value nearly 0.36 and which was statistically significant with p value < 0.001.

Verma and colleagues found that the higher the IOP, the larger the cup disc ratio. Gyasi et al in his study found that the relationship between high intraocular pressure (IOP > 30 mmHg) and vertical cup disc ratio =1.0 (p<0.001).

Hitchings RA concluded that examination of optic disc photographs allowed accurate prediction of glaucomatous and normal visual field to be made in 82% and 95% of eyes respectively and for visual field loss to be correctly located in the upper and lower half in 83% and 91% of cases, respectively.

In our study, the cup disc ratio of all patients was measured and it was correlated with the field defect present. The visual field defect classified as mild, moderate and severe visual field defect according to Hodapp Anderson Parrish (HAP) criteria. The mean deviation and pattern deviation were obtained by the SITA standard strategy of the 30-2 program of HFA. The mean deviation and pattern deviation of only reliable field were used in the analysis.

The highest mean deviation was -22.05 db with cup disc ratio 0.8 and concentric NRR notching with central 5 degree of tubular vision, graded as severe field defect according to HAP. On correlating the mean deviation (MD) with the cup disc ratio, pearson correlation value for right eye was 0.923 whereas for left eye it was 0.951, showing correlation among them which is statistically significant (p<0.001).

It was seen that a cup disc ratio of 0.7 or more is almost confirmatory of associated field defects. The correlation of the cup disc ratio and pattern deviation was seen to be highly significant with pearson correlation value of 0.961 for right eye and 0.977 for left eye (p<0.001). The average PD in group-1 with C:D ratio <0.7 was 6.16 db while in group-2 with C:D ratio ≥0.7, it was 9.62 db. The difference was also seen to be statistically significant. Moreover, in terms of qualitative defects also, it was seen that some patients with 0.6 c:d ratio, who were suspected to have POAG, had normal visual fields. This finding is in accordance with that of Hoskins et al (1975), who showed that C:D ratio is helpful only when it reaches 0.8.

So the present study state that cup disc ratio show correlation with both mean deviation and pattern deviation but as pearson correlation value r is more for pattern deviation so cup disc ratio is more correlated with pattern deviation as compared to mean deviation.

Omodaka K et al reported that the vertical cup disc ratio had the highest correlation coefficient to the mean deviation among all the optic disc parameters. This correlate well with our study.

Cullinane BA found a significant difference in the visual field mean deviation (MD) between normal and POAG patients. Among the highest individual correlation were those found between visual field mean deviation and C:D ratio.

Lan WY et al reported that in the early stage of glaucoma, a small change in the mean deviation was accompanied by a large amount of rim loss and in later stage, a large change in mean deviation was accompanied by a small change in rim loss.

For mean deviation between 0 db to 6 db, the relative rim loss can range from 0 to 70% and for mean deviation -6 db and -12 db, the relative rim loss ranged from 40% to 80%.

The most significant correlation of the cup disc ratio was seen to be with pattern deviation, which signifies localized defect and is believed to be indicative of glaucomatous damage, with a correlation coefficient of 0.9.

Capriole and Miller earlier were also able to obtain a significant correlation between the above mentioned parameter but the strongest correlation was seen for mean deviation whereas in the present study pattern deviation is more correlated with cup disc ratio than mean deviation. One of the reasons for this could be the fact that they were using different program for visual field examination.

Conclusion

A total of 114 eyes of 60 primary open angle glaucoma patients, fulfilling the inclusion criteria were included in the study. The intraocular pressure was measured by using Schiottz tonometer and gonioscopy was performed with Goldmann 3 mirror gonioscopic lens. The optic disc was evaluated by slit lamp biomicroscopy using 90 D lens and magnified photographs were taken with a KOWA retinal digital camera. Central field testing was performed with the 30-2 program SITA standard strategies.

Correlation between the optic disc parameter and visual field defects was calculated using least square method and pearson correlation.

Mean age of patients was 58.7±10.2 years, among them 51.66% of POAG patients were male while 48.33% were female.

The mean intraocular pressure of 114 eyes of 60 patients was 29.93±3.23 mmHg.

The correlation between cup disc ratio and intraocular pressure was done using pearson coefficient

and least square method and it was found to be statistically significant with $p < 0.001$.

The visual field indices measured were mean defect (MD, signifying generalized depression) and pattern deviation defect (PD, signifying localized field depression). Both mean deviation and pattern deviation was correlated significantly with cup disc ratio (using pearson coefficient and least square method) $p < 0.001$.

The pattern deviation PD was seen to have the stronger correlation with cup disc ratio. It was seen to increase linearly along with an increase in cup disc ratio and became significantly higher when the cup disc ratio became 0.7 or more. Thus a cup disc ratio of >0.7 was seen to be almost consistent of severe field defects. However a cup disc ratio of <0.7 did not correlate well with pattern deviation.

Among the various optic disc variable, the neuroretinal rim is the most predictable variable to detect field loss. As the earliest glaucomatous disc changes which differentiate between normal and glaucomatous visual field defect was inferior neuroretinal rim notching.

Other disc parameters which were shown to be important in predicting visual field defects were-Baring of vessels with nasalization of vessels- this was seen to have high specificity in predicting field defects, Bayonetting of vessels, Laminar dot sign, Peripapillary atrophy-beta zone atrophy was found in the glaucomatous patients very commonly while it was uncommon in non-glaucomatous cases, but alpha zone atrophy was seen to be commonly present in both glaucomatous as well as non-glaucomatous eyes.

A strong correlation was found between the state of visual field and optic disc, signifying the value of optic disc evolution in assessment of visual function of a glaucomatous patient with inferior rim notching being the most predictable variable.

References

1. Resnikoff. Bulletin of the world health organization, volume 82, Number 11,811-890, November- 2004.
2. Airaksinen PJ, Tuulonen A, Alanko H I: Rate and pattern of neuroretinal rim area decrease in ocular hypertension and glaucoma, Arch ophthalmology, 1992;110:206-210.
3. Airaksinen PJ, Drance SM, Douglas GR, Schulzer M: Neuroretinal rim areas and visual field indices in glaucoma, Am J ophthalmol,99:107,1985.
4. Airaksinen PJ, Drance SM, Douglas GR, Schulzer M and Wijsman k: Visual field and retinal nerve fibre layer comparison in glaucoma, Arch ophthalmology.
5. Hoskin HD jr, Gelber EC: Optic disc topography and visual field defects in patients with increased intraocular pressure, Am J ophthalmol, 80:284,1975.
6. Hitchings RA, Spaeth GL: The optic disc in glaucoma-2, Correlation of the appearance of the optic disc with the visual field, Br J Ophthalmol, 61:107,1977.
7. Caprioli J, Miller J.M.: Correlation of structure and function in glaucoma, Quantitative measurement of disc and field, ophthalmology,95:723,1988.
8. Suzuki Y, Iwase A, Araie M, Yamamoto T, Abe H, Shirato S et al, Risk factors for open angle glaucoma in Japanese population- The Tajimi study, ophthalmology,113:1613-1617,2006.
9. Gyasi M, Amoko W, Adjuk M, Presentation pattern of primary open angle glaucoma in North Eastern Ghana. Ghana Med J, 44(1):25-30,2010.
10. Hong C, Joo JH, Shin KH, Song KY, Clinical study of Korean glaucomatous patients, Kor J ophthalmol,1:41-46,1987.
11. Wensor MD, McCarty CA, Stanislavsky YL, Livingston PM, Taylor HR, The prevalence of glaucoma in Melbourne visual impairment project, ophthalmology, 105:733-739,1998.
12. Alipanahi R et al, Common visual field defect in the open angle glaucoma eyes, R M J,33(1):99-101,2008.
13. Varma R, Hilton SC, Quigley HA, Sommer A, Neural rim area declines with increase in intraocular pressure in urban Americans. Arch ophthalmol,86:555-559,2002.
14. Hitchings RA, Spaeth LG, The optic disc in glaucoma-2: Correlation of the appearance of the optic disc with the visual field, Br J Ophthalmol,61(2):107-113,1989.
15. Omodaka K et al, Correlation between morphology of the optic disc determined by Heidelberg retinal tomography - 2 and visual function in eyes with open angle glaucoma, Clinical ophthalmology,4:765-772,2010.
16. Cullinane BA, Waldock A, Diamond PJ et al, optic disc cup slope and visual field indices in normal, ocular hypertensive and early glaucomatous eyes. Br J ophthalmol, 86:555-559,2002.
17. Lan WY, Henson BD, Kwartz JA, The correlation between optic nerve head topographic measurements, peripapillary nerve fibre layer thickness, and visual field indices in glaucoma, Br J ophthalmol,87:1135-1141,2003.