

## To evaluate the effect of intravitreal bevacizumab, macular grid laser and both in combination in patients of clinically significant macular edema

Gunjan Prakash<sup>1</sup>, Ashwini G<sup>2\*</sup>, Himanshu Kumar Yadav<sup>3</sup>, Neeraj A Awasthi<sup>4</sup>

<sup>1</sup>Assistant Professor, <sup>2</sup>Senior Resident, <sup>3,4</sup>Professor, Dept. of Ophthalmology, Sarojini Naidu Medical College, Agra, Uttar Pradesh

**\*Corresponding Author:**

Email: dr.ashwinig@gmail.com

### Abstract

**Purpose:** To compare the efficacy between intravitreal bevacizumab, macular grid photocoagulation and both in combination for the treatment of clinically significant macular edema.

**Methods:** 21 cases of clinically significant macular edema were prospectively divided in three groups randomly. In group A, patients received bevacizumab 0.05ml intravitreally. In group B, patients received macular grid photocoagulation. In group C, patients received combination of macular grid photocoagulation and bevacizumab 0.05ml intravitreally. Central macular thickness and best corrected visual acuity were the main outcomes measured.

**Results:** The difference in central macular thickness and best corrected visual acuity among the groups at baseline was not statistically significant ( $p > 0.05$ ). There was significantly more improvement in central macular thickness and best corrected visual acuity in group C than in group A and group B at two months follow-up ( $p < 0.05$ ).

**Conclusion:** The better short term therapeutic outcomes in the group C indicates that combining intravitreal bevacizumab and macular grid photocoagulation might be more effective than intravitreal bevacizumab and macular grid photocoagulation alone for the treatment of clinically significant macular edema.

### Introduction

Diabetes mellitus represents one of the most common metabolic diseases and it has assumed the proportions of a global epidemic. Diabetic retinopathy still remains one of the pre-eminent causes of visual disability worldwide. There is drastic increase in the prevalence of diabetic retinopathy in India.<sup>(1,2,3)</sup> Diabetic macular edema is considered to be the most common cause of reduced vision in diabetics. There is positive correlation between diabetic retinopathy and duration of diabetes. Laser treatment has been considered as the gold standard treatment for diabetic macular edema since the Early Treatment Diabetic Retinopathy Study (ETDRS). ETDRS demonstrated 50% reduction in the incidence of moderate visual loss in patients who underwent early treatment. Vascular Endothelial Growth Factor (VEGF) plays a key role in the pathogenesis of diabetic macular edema. Various studies have documented significant elevation of VEGF levels in vitreous of diabetic macular edema patients when compared with normal eyes.<sup>(4)</sup> Bevacizumab is a recombinant full-length humanized monoclonal antibody (149 kDa) that targets all isoforms of VEGF-A. Many recent studies have suggested the prolific need of strict glycemic control in allaying the menace of diabetic retinopathy. Hypertension contributes to microvasculature damage by releasing VEGF. The United Kingdom Prospective Diabetes Study (UKPDS) clearly demonstrated the advantageous role of strict blood glucose control in curtailing the risk of diabetic retinopathy in patients with type-2 diabetes mellitus and its role in alleviating micro-vascular complication rate by 25%. According to UKPDS,<sup>(5)</sup> strict blood pressure

control prevented the progression of diabetic retinopathy and also reduced the cardiovascular risk significantly. This study supported the significance of strict control of hyperglycemia and hypertension in order to obtain favorable cardiovascular and microvascular outcomes. The Diabetes control and Complications Trial (DCCT)<sup>(6)</sup> emphasized the need of strict glycemic control to slow down the risk of developing diabetic retinopathy in type-1 diabetic patients. Obesity has turned out to be a leading determinant of diabetes, which is a matter of grave concern. It is associated with increased risk of diabetic retinopathy. Few clinical trials have been conducted to evaluate the additive synergistic effect of combining anti-VEGF with laser therapy in treating diabetic macular edema. Giulio Barteselli, Igor Kozak Elemam, Jay Chhablani<sup>(7)</sup> evaluated the effectiveness of combination treatment of bevacizumab and laser therapy in diabetic macular edema and concluded that standardized combination therapy was more beneficial in improving vision. Other anti- VEGF drugs approved for the management of diabetic macular edema include pegaptanib sodium, ranibizumab and aflibercept. Intravitreal steroids have also been found effective in improving vision in DME patients. Intravitreal injection of triamcinolone acetonide received great acclaim for its anti- proliferative and anti- angiogenic properties. Ozurdex, dexamethasone implant and Retisert, fluocinolone acetonide implant are approved by FDA for the treatment of diabetic macular edema. Vitrectomy has been considered as the treatment of choice for DME patients who have coexistent vitreomacular traction and those who are not responding to above mentioned treatment modalities.

## Material and Methods

A prospective clinical interventional study was conducted to compare the efficacy of bevacizumab intravitreally, macular grid laser and both in combination in patients of clinically significant macular edema. Research ethics board approval was granted by ethics committee of our college.

**Participants:** The present study included 21 treatment-naïve patients of clinically significant macular edema from November 2012 to October 2014. Cases with previous episodes of cerebro-vascular accidents, cases having proliferative changes in fundus, cases with uncontrolled blood sugar and hypertension, lipid profile and cases with severe bleeding disorders were excluded from the study. Prior to initiation of the study, the eligible subjects were randomly assigned to different treatment groups according to the randomization schedule. The patients were divided in three groups; Group A included 7 patients treated with bevacizumab injection only. Group B included 7 patients treated with macular grid photocoagulation. Group C included 7 patients treated with combination of both. Bevacizumab was given intravitreally at a dose of 1.25mg in 0.05ml. In combination treatment group, grid laser treatment was given 3 weeks after bevacizumab. Bevacizumab was given under aseptic precautions. All the patients were advised standard medical treatment for their diabetes as indicated. All patients underwent ophthalmic examination including best corrected visual acuity, slit lamp examination, IOP (intraocular pressure), dilated fundus examination, slit lamp biomicroscopy, optical coherence tomography (OCT), fundus fluorescein angiography (FFA), blood sugar, HbA1c and lipid profile. All patients of three groups were reviewed at day-3, 1 week, 1 month and 2 months post procedure. Patients were reviewed until 2 months after treatment. Changes of visual acuity and central macular thickness were compared at each follow-up. The study protocol, patient information sheet, and informed consent form were reviewed and approved by ethics committee.

## Results

**Statistical analysis:** Differences between pre and post treatment statistics were assessed using paired t-test. Differences between the three groups were evaluated using an independent t-test. Out of 21 patients of clinically significant macular edema it was found that 20(95.24%) were males and 1(4.76%) was female. The mean age was 55.19 years. There was no statistically significant difference in macular thickness and best corrected visual acuity among the groups at baseline.

**Change of best corrected visual acuity:** Changes of visual acuity following intravitreal bevacizumab injection (group A), macular grid laser photocoagulation (group B) and combination treatment (group C) at each follow-up are depicted in Table 1 and Fig. 1. In intravitreal bevacizumab alone group, improvement in

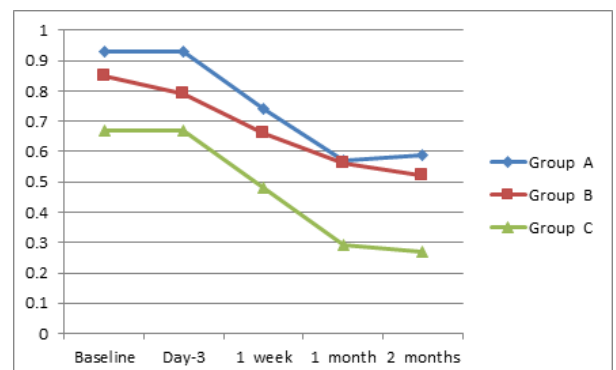
visual acuity was significant statistically at 1 month, which slightly regressed at final follow-up. There was no statistically significant visual improvement in macular laser group during follow-up. Vision improvement in combination group was significant statistically at 1 month and 2 months post procedure.

**Change of central macular thickness:** Changes of central macular thickness following intravitreal bevacizumab injection (group A), macular grid laser photocoagulation (group B) and combination treatment (group C) at each follow-up are illustrated in Table 2 and Fig. 2. There was statistically significant improvement in central macular thickness at 1 month in intravitreal bevacizumab alone group, followed by decline of improvement at 2 months. There was no statistically significant improvement in reduction of central macular thickness in macular laser alone group. Combination group demonstrated statistically significant improvement in central macular thickness at 1 month and 2 months post procedure.

Combination treatment group revealed significant improvement in central macular thickness and best corrected visual acuity when compared to the other two groups at final follow-up (Table 3 and Fig. 3). No complications were noted with any of these procedures.

**Table 1: Changes of visual acuity after each treatment**

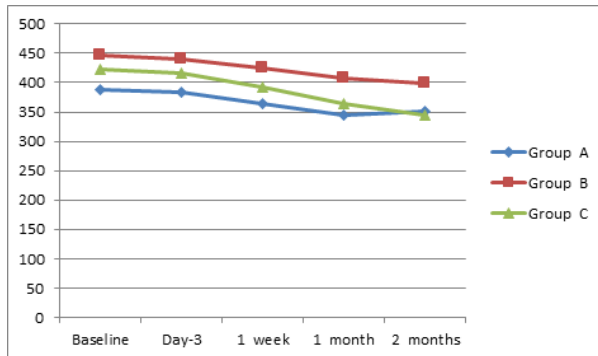
Follow-up	Treatment groups		
	Bevacizumab	Macular laser	Combination therapy
Baseline	0.93±0.38	0.85±0.51	0.67±0.29
Day-3	0.93±0.38	0.79±0.54	0.67±0.29
1 week	0.74±0.34	0.66±0.52	0.48±0.19
1 month	0.57±0.36	0.56±0.45	0.29±0.10
2 months	0.59±0.37	0.52±0.47	0.27±0.11



**Fig. 1: Comparison of visual acuity between intravitreal bevacizumab (Group A), macular grid laser (Group B) and combination of both (Group C)**

**Table 2: Changes of central macular thickness after each treatment**

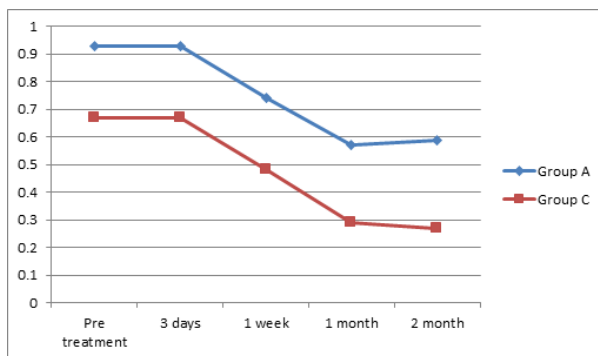
	Treatment groups		
	bevacizumab	Macular laser	Combination therapy
Baseline	387.14±64.76	446.57±131.59	422.29±50.32
Day-3	384.0±67.62	439.29±131.17	416.43±50.13
1 week	365.0±65.41	425.43±135.28	391.86±38.63
1 month	345.67±63.70	407.29±127.45	364.86±39.80
2 months	350.71±65.61	398.14±128.20	343.71±36.38



**Fig. 2: Comparison of central macular thickness between intravitreal bevacizumab (Group A), macular grid laser (Group B) & combination of both (Group C)**

**Table 3: Comparison of visual acuity between intravitreal bevacizumab (Group A) and intravitreal bevacizumab plus macular laser photocoagulation combination therapy (Group C)**

	Pre-treatment		3 Days		1 week		1 month		2 month	
	Group A	Group C	Group A	Group C	Group A	Group C	Group A	Group C	Group A	Group C
Mean	0.93	0.67	0.9	0.6	0.7	0.4	0.6	0.5	0.6	0.2
SD	0.38	0.29	0.3	0.2	0.3	0.1	0.3	0.1	0.3	0.1
t-value	1.4391		1.4391		1.7662		1.9877		2.1933	
p-value	0.1774 <sup>NS</sup>		0.1774 <sup>NS</sup>		0.1077 <sup>NS</sup>		0.0883 <sup>NS</sup>		0.0641 <sup>NS</sup>	



**Fig. 3: Comparison of visual acuity between intravitreal bevacizumab and combination of bevacizumab plus macular grid laser groups**

**Discussion**

Diabetic retinopathy has emerged as a catastrophic ocular disease worldwide, which need to be addressed in order to prevent the consequences of this disease. Early detection of diabetic retinopathy is essential to halt the progression and vision threatening complications associated with the disease. This obviates the need of proper screening for diabetic retinopathy and counselling to increase the awareness among the patients and health care providers regarding the various treatment modalities and prognosis of diabetic retinopathy. Several studies have documented the effectiveness of bevacizumab and laser treatment in alleviating the ocular complications of diabetic eye disease. Bevacizumab has been accepted with acclaim in recent years. It is recommended in the dose of 1.25mg intravitreally. It inhibits proangiogenic receptor signals by inhibiting the binding of VEGF to its receptors. Positive clinical response, easy availability and cost of this drug have made its usage more acceptable in developing countries like India. The half-life of bevacizumab in vitreous and plasma is 9.8 days and 17-21 days respectively. Diabetic retinopathy clinical research network<sup>(8)</sup> (DRCR net) study has demonstrated the effectiveness of bevacizumab in reducing diabetic macular edema. Grid laser was initially considered as the gold standard for treating DME cases. It converts hypoxic foci into anoxic resulting in diminution of vasoproliferative factor release. It consists of spot size of 50 to 200 µm for a duration of 0.05 to 0.5 sec. It is applied 500 µm away from the center of macula and disc margin to prevent the involvement of papillomacular bundle. Mild macular laser photocoagulation and subthreshold diode micropulse laser photocoagulation are gaining significant attention in recent years. These laser techniques have helped in reducing laser damage to the most sensitive retinal tissues. In our study twenty one patients with CSME were randomly allocated to receive intravitreal bevacizumab (group A), macular grid photocoagulation (group B), intravitreal bevacizumab and macular grid photocoagulation in combination (group C). All the three groups share similar demographic details. The three groups were compared on the basis of improvement in vision and central macular thickness. Our study showed that improvement in visual acuity and central macular thickness was significant at 1 month post bevacizumab and the effect started to wean off by 2 months. Macular grid laser group showed no statistically significant improvement of vision at final follow-up. Rajendram R, Fraser Bell S, Kaines A et al<sup>(9)</sup> conducted a similar study wherein repeated injections of bevacizumab and laser were given to patients with persistent DME and favored bevacizumab over laser. Unlike our study they have included patients with persistent diabetic macular edema and this study has been carried out for two years. Combination of intravitreal bevacizumab and macular

laser group of our study experienced significant improvement in vision at 1 month and it persisted at 2 months post procedure. There was significant reduction in central macular thickness in combination treatment group at final follow-up. A similar study conducted by Solaiman KA, Diab MM et al<sup>(10)</sup> have successfully demonstrated the efficacy of combination treatment with bevacizumab and laser versus bevacizumab and laser treatment alone in improving vision in patients with DME. Soo Jeong Lee, Ei Tae Kim and Yeon Sung Moon<sup>(11)</sup> have also evaluated the effectiveness of intravitreal bevacizumab injection and combination of laser photocoagulation and intravitreal bevacizumab in treatment of DME. Similar to our study they have also demonstrated the better visual outcome with combination treatment over intravitreal injection of bevacizumab alone at final follow-up. Unlike our study they reviewed the patients for 6 months post treatment. The results of both studies indicated the potency of combination treatment in maintaining visual acuity, which would decline with bevacizumab injection alone. Heier JS, Bressler NM, Avery RL, Bakri SJ<sup>(12)</sup> have evaluated the efficacy of Aflibercept, Bevacizumab, and Ranibizumab in the management of diabetic macular edema and demonstrated competence of these anti- VEGF agents in improving vision. Aflibercept offered more benefit in patients with worse baseline visual acuity over other two anti- VEGF drugs 1 year post treatment. Wells JA, Glassman AR, Ayala AR<sup>(13)</sup> have compared the effectiveness of Bevacizumab, Aflibercept, or Ranibizumab in the treatment of center-involving diabetic macular edema and documented visual improvement in all 3 anti- VEGF drug groups. Patients with better visual acuity at initial follow-up experienced similar visual outcomes. However Aflibercept outperformed Bevacizumab in eyes with worse baseline visual acuity after 2 years. Our study proved the beneficial role of combination treatment in treating diabetic macular edema. Even though repeated injections of bevacizumab are found to be effective, many people in India cannot afford it. Continuing use of laser along with bevacizumab could reduce treatment costs and could significantly increase access to treatment. The combination treatment is found to be advantageous in maintaining vision and reducing recurrences. Hence it should be recommended for better recovery of vision in patients with DME. There is an ample need of further investigation of additional treatment options and an integrative approach to combat this sight threatening disease.

## References

1. Dandona L, Dandona R, Naduvilath TJ, McCarty CA, Rao GN. Population based assessment of Diabetic retinopathy in an urban population in southern India. *Br J Ophthalmol* 1999;83:937-40.
2. Rema M, Premkumar S, Anitha B, Deepa R, Pradeepa R, Mohan V. Prevalence of diabetic retinopathy in urban India: The Chennai urban rural epidemiology study (CURES eye study, I. *Invest Ophthalmol vis sci* 2005;46:2328-33.
3. Narendran V, John RK, Raghuram A, Ravindran RD, Nirmalan PK, Thulasiraj RD. Diabetic retinopathy among self-reported diabetics in Southern India: A population based assessment. *Br J Ophthalmol* 2002;86:1014- 8.
4. Funatsu H, Noma H, Mimura T, Eguchi S, Hori S. Association of vitreous inflammatory factors with Diabetic macular edema. *Ophthalmology* 2009;116:73-9.
5. Mathews DR, Stratton IM, Aldington SJ, Holman RR, Kohner EM; UK Prospective Diabetes Study Group. Risks of progression of retinopathy and vision loss related to tight blood pressure control in type 2 diabetes mellitus: UKPDS 69. *Arch Ophthalmol*. 2004 Nov;122(11):1631-40.
6. The Diabetes Control and Complications Trial Research Group. The Effect of Intensive Treatment of Diabetes on the Development and Progression of Long-Term Complications in Insulin-Dependent Diabetes Mellitus. *N Engl J Med* 1993;329:977-986.
7. Barteselli G, Kozak I, El-Emam S, Chhablani J, Cortes MA, Freeman WR. 12- month results of the standardized combination therapy for diabetic macular edema: intravitreal bevacizumab and navigated retinal photocoagulation. *Br J Ophthalmol*. 2014 Aug; 98(8):1036-41.
8. Diabetic retinopathy clinical research network. A phase-II randomized clinical trial of intravitreal bevacizumab for diabetic macular edema. *ophthalmology* 2007 Oct;114(10):1860-1867.
9. Rajendram R, Fraser- Bell S, Kaines A, Michaelides M, Hamilton RD, Esposti SD, Peto T, Egan C. A 2- year prospective randomized controlled trial of intravitreal bevacizumab or laser therapy (BOLT) in the management of diabetic macular edema: 24- month data: report 3. *Arch Ophthalmol*. 2012 Aug;130(8):972-9.
10. Solaiman KA, Diab MM, Abo- Elenin M. Intravitreal bevacizumab and/ or macular photocoagulation as a primary treatment for diffuse diabetic macular edema. *Retina*. 2010 Nov- Dec;30(10):1638- 45.
11. Soo Jeong Lee, Ei Tae Kim and Yeon Sung Moon. Intravitreal Bevacizumab alone versus combined with Macular Photocoagulation in Diabetic Macular edema. *Korean J Ophthalmol*. Oct 2011;25(5):299-304.
12. Heier JS, Bressler NM, Avery RL, Bakri SJ. Comparison of Aflibercept, Bevacizumab, and Ranibizumab for Treatment of Diabetic Macular Edema: Extrapolation of Data to Clinical Practice. *JAMA Ophthalmol*. 2016 Jan;134(1):95-9.
13. Wells JA, Glassman AR, Ayala AR, Jampol LM, Bressler SB. Aflibercept, Bevacizumab, or Ranibizumab for Diabetic Macular Edema: Two- Year Results from a Comparative Effectiveness Randomized Clinical Trial. *Ophthalmology*. 2016 Jun;123(6):1351- 9.