

Effect of retinal laser photocoagulation on contrast sensitivity in diabetic retinopathy

Shairin Jahan¹, Abdul Waris^{2,*}, RR Sukul³, Rahul Gupta⁴

^{1,4}PG Student, ²Assistant Professor, ³Professor, Dept. of Ophthalmology, Jawaharlal Nehru Medical College, Aligarh

***Corresponding Author:**

Email: waris_eye@yahoo.co.in

Abstract

Aim: To study the effect of retinal laser photocoagulation on contrast sensitivity in diabetic retinopathy.

Method: Prospective interventional study of all the patients with diabetic retinopathy presenting at our Institute of Ophthalmology with indications of Retinal Photocoagulation. Contrast sensitivity was assessed prior to laser and then again after 1 week of 1st and 2nd sitting and after 6 weeks of 3rd sitting of panretinal photocoagulation. The Contrast Sensitivity was statistically compared and the data collected was analyzed for statistical significance using SPSS version 20 by Repeated ANOVA test.

Result: The contrast sensitivity improved in 24 eyes (68%), decreased in 2 eyes (6%) while it remained constant in 9 eyes (26%).

Conclusion: Retinal Laser Photocoagulation causes statistically significant improvement in contrast sensitivity after a period of 6 weeks post laser in patients of diabetic retinopathy.

Keywords: Contrast sensitivity, Diabetic retinopathy, Retinal laser photocoagulation

Introduction

The term "laser" originated as an acronym for "light amplification by stimulated emission of radiation". For many decades, laser photocoagulation has remained the mainstay of treatment for various retinal diseases. Photocoagulation coagulates the tissues of retina and choroid and in fact a scar is formed which is insensitive to light stimulation. Thus it causes loss or defect in visual functions which can be termed as a complication of photocoagulation.

Materials and Methods

Ours was a prospective interventional study consisting of 35 eyes of 27 patients with diabetic retinopathy who presented to retina clinic, Institute of Ophthalmology, Jawaharlal Nehru Medical College and Hospital, Aligarh Muslim University, Aligarh.

Inclusion Criteria: All patients with diabetic retinopathy with reasonably clear media presenting at Institute of Ophthalmology, Jawaharlal Nehru Medical College with indications of Retinal Photocoagulation.

Exclusion Criteria:

1. Patients who had undergone prior retinal photocoagulation.
2. Patients with media not clear.
3. Patients with other disorders/conditions of retina and/or optic nerve in which contrast sensitivity is already compromised.

The study was approved from the ethical committee of Jawaharlal Nehru Medical College and Hospital, Aligarh Muslim University, Aligarh and was according to the Declaration of Helsinki. Valid consent (informed consent) was taken from each of the patient after explaining them the procedure in detail before their inclusion in the study.

After taking the consent, patient's particulars; name, age, sex, address and occupation were recorded in the predesigned proforma.

Presenting complaints were elicited. History regarding duration of diabetes, other medical and surgical disorder and their treatment were recorded.

Complete clinical examination was done which included:

1. Visual acuity by LogMAR chart
2. Contrast sensitivity by Pelli – Robson chart
3. Fundus evaluation by Direct ophthalmoscopy, Indirect ophthalmoscopy and +78 D.

Technique of Laser Photocoagulation: All the selected patients underwent Panretinal photocoagulation. It was done using Double Frequency Nd:YAG laser by Carl Zeiss Meditec Laser machine (wavelength 532nm). In PRP laser photocoagulation was done in the Inferior, Superior and the Temporal quadrant in the 1st, 2nd and 3rd sitting respectively. 800-1600 burns were given in PRP. Location of PRP burns extended from 500 μ m nasal to the optic disc margin, 2DD (3000 μ m) temporal to, above and below the macular center, just within the vascular arcade and extending peripherally to or beyond the equator. Laser Photocoagulation of the macular area was carried out between any of the sittings as per requirement.

Follow up visits: The contrast sensitivity was assessed again after 1 week of 1st and 2nd sitting and after 6 weeks of 3rd sitting of panretinal photocoagulation. On each follow up visual acuity testing and fundus examination were also done.

Results

Amongst total 27 patients, 15 (56%) patients were male and 12 (44%) patients were female.

2 (7%) patients were in the age group of 41-50 years, 15 (56%) patients in the age group of 51-60 years and 10 (37%) patients in the age group of 61-70 years. None of the patients in the range of 1-40 years of age had Diabetic Retinopathy. The mean age of patients was 58.11 ± 4.96 years.

The Contrast Sensitivity was statistically compared in 35 eyes of 27 patients. The data collected was analyzed for statistical significance using SPSS version 20 by Repeated ANOVA test.

In these patients, the mean baseline contrast sensitivity was 0.502 ± 0.328 (CS 1). After 1 week of 1st and 2nd sitting of laser photocoagulation, mean contrast sensitivity was found to be 0.554 ± 0.325 (CS 2) and 0.591 ± 0.370 (CS 3) respectively. The mean final contrast sensitivity was 0.717 ± 0.375 (CS 4).

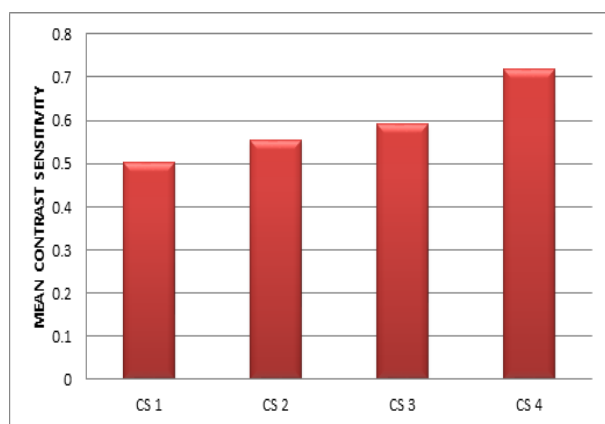


Fig. 1: Showing mean contrast sensitivity

Upon application of Statistical test, the p-value was <0.05 , show result to be statistically significant.

Out of total of 35 eyes, the contrast sensitivity improved in 24 eyes (68%), decreased in 2 eyes (6%) while it remained constant in 9 eyes (26%).

Discussion

In the last decade the use of lasers in ophthalmology has provided some of the most important advances in the treatment of disease. The long-term beneficial effects (especially panretinal photocoagulation in diabetes) of laser therapy are undoubted, but there is still some concern about the side effects of the treatment itself.⁽¹⁻³⁾

In our study, the mean final contrast sensitivity improved and it was found to be statistically significant (p-value <0.05). This can firstly be attributed to the resolution of vitreous and retinal hemorrhages in patients of diabetic retinopathy, central/branch retinal venous occlusion over the period of study, secondly resolution of macular edema following laser photocoagulation is another important factor. Thirdly, PRP being done in multiple sessions reduces the side effects of laser including exacerbation of macular edema which is one of the most important cause of

reduction in contrast sensitivity following laser photocoagulation. Fourthly, in our study all the patients received topical nepafenac (0.1%) three times a day for 1-2 weeks which further reduced the chances of exacerbation of macular edema following laser photocoagulation.

Our result is in accordance with the study conducted by Midena *et al.*,⁽⁴⁾ in 1992, Farahvash *et al.*,⁽⁵⁾ in 2008, Talwar *et al.*,⁽⁶⁾ in 2009 and Suchi *et al.*,⁽⁷⁾ They found that contrast sensitivity improves the most due to the resolution of macular edema following treatment.

On the contrary, Lovestam *et al.*,⁽⁸⁾ in 2000 reduction in contrast sensitivity after laser photocoagulation. They attributed this to the old age of the patients as patients included in their study were older and that old age per se is connected with a decrease in contrast sensitivity.⁽⁹⁾

Whereas studies conducted by Ghafour *et al.*,⁽¹⁰⁾ in 1984, Canning *et al.*,⁽¹¹⁾ in 1991, Khosla *et al.*,⁽¹²⁾ in 1994, Maia *et al.*,⁽¹³⁾ in 2007 and Khan *et al.*,⁽¹⁴⁾ in 2014 showed no statistically significant changes between pre and post treatment values of contrast sensitivity.

Conclusion

Retinal Laser Photocoagulation causes statistically significant improvement in contrast sensitivity after a period of 6 weeks post laser in patients of diabetic retinopathy. Further studies with much larger sample size need to be conducted to identify a difference in occasional events, such as complications after laser treatment and to compare the laser parameters that are associated with a change in visual function. Further studies need to be conducted taking into account the duration of diabetes, compliance, metabolic control and other confounding factors like presence of hypertension, hyperlipidemia, anemia, nephropathy etc. which can affect the diabetic retinopathy.

References

1. Glickman RD. Photosensitivity to the retina: mechanisms of damage. *Int J Toxicol*. Nov-Dec 2002;21(6):473-90.
2. Argon laser photocoagulation for macular edema branch vein occlusion. The Branch Vein Occlusion Study Group. *Am J Ophthalmol* 1984;98:271-82.
3. Laser photocoagulation of subfoveal neovascular lesions of age-related macular degeneration. Updated findings from two clinical trials.
4. Macular Photocoagulation Study Group. *Arch Ophthalmol* 1993;111:1200-9. Midena E, Segato T, Bottin G, Piermarocchi S, Fregon I. The effect on the macular function of laser photocoagulation for diabetic macular edema. *Graefes Arch Clin Exp Ophthalmol*. 1992;230(2):162-5.
5. Farahvash MS, Mahmoudi AH, Farahvash MM, Tabatabaee A, Riazi M, Mohammadzadeh S. The impact of macular laser photocoagulation on contrast sensitivity function in patients with clinically significant macular edema. *Arch Iran Med*. 2008 Mar;11(2):143-7.
6. Talwar D, Sharma N, Pai A, Azad RV, Kohli A, Virdi PS. Contrast sensitivity following focal laser

- photocoagulation in clinically significant macular edema. *Clin Experiment Ophthalmol.* 2001 Feb;29(1):17-21.
7. Shah SV, Jani HC, Saxena DA. Effect of retinal laser photocoagulation on contrast sensitivity and visual acuity in patients of diabetic retinopathy. *International Journal of Scientific and Research Publications* 2014;4(10).
 8. Lövestam-Adrian M, N Svendenius, Agardh E. Contrast sensitivity and visual recovery time in diabetic Patients treated with panretinal photocoagulation. *Acta Ophthalmol Scand.* 2000;78(6):672-6.
 9. Skalka HW. Effect of age on Arden grating acuity. *Br J Ophthalmol* 1980;64:21–23.
 10. Ghafour M, Foulds WS and Allan D. Short-term effect of slit-lamp illumination and argon laser light on visual function of diabetic and non-diabetic subjects *British Journal of Ophthalmology*, 1984,68,298-302.
 11. Canning C, Polkinghorne P, Ariffin A, Gregor Z. Panretinal laser photocoagulation for proliferative diabetic retinopathy: the effect of laser wavelength on macular function. *Br J Ophthalmol.* 1991;75(10):608-10.
 12. Khosla PK, Rao V, Tewari HK, Kumar A. Contrast sensitivity in diabetic retinopathy after panretinal photocoagulation. *Ophthalmic Surg.* 1994;2 (8):516-20.
 13. Maia OO Jr, Takahashi WY, Sampaio MW, Hokazono K, Misawa AK. Contrast sensitivity in diabetic retinopathy treated with argon laser photocoagulation. *Arq Bras Oftalmol.* 2007 Sep-Oct;70(5):763-6.
 14. Talwar D, Sharma N, Pai A, Azad RV, Kohli A, Viridi PS. Contrast sensitivity following focal laser photocoagulation in clinically significant macular edema. *Clin Experiment Ophthalmol.* 2001 Feb;29(1):17-21.