

## Penetrating ocular trauma and visual outcome clinical study

Mohammed Ather<sup>1,\*</sup>, Rahmatunissa<sup>2</sup>, Goli Sridhar<sup>3</sup>, T. Sai Shreya<sup>4</sup>, Irshad Ahmed Siddiqui<sup>5</sup>

<sup>1</sup>Professor & HOD, <sup>2,3</sup>Assistant Professor, <sup>4,5</sup>Junior Resident, Dept. of Ophthalmology, Gandhi Medical College, Hyderabad, Telangana

**\*Corresponding Author:**

Email: ather11258@gmail.com

### Abstract

**Aim:** To study the visual outcome in the cases of penetrating trauma after primary and secondary repair

**Materials and Methods:** This is a prospective interventional study conducted at Sarojini Devi eye hospital / Regional institute of Ophthalmology during January 2000 to December 2002. 909 cases of penetrating ocular trauma of all ages presented at Sarojini Devi eye hospital were included in the study. The cases who underwent ocular surgery prior to trauma were excluded from the study.

All the cases were admitted in hospital and examined by an experienced Ophthalmologist using Slit lamp, Direct and indirect Ophthalmoscope. X-ray Orbit, B scan was performed in all cases to evaluate the posterior segment and to rule out retained intra-ocular foreign body. Electro Physiological evaluation like VEP done in selected cases. Primary repair was undertaken immediately like suturing Corneal tear, Corneo sclera tear and Scleral tear. Secondary procedure like Cataract extraction, Vitrectomy, IOFB removal, Retinal detachment surgery was taken once eye became quite.

**Results:** Incidence of trauma in males is 8 times more than females. Visual outcome was good in patient who had single surgery. Only corneal tear had good visual prognosis than Corneo-scleral tear or Scleral tear. Patient who had to undergo more than one procedure got < 6/12 vision

**Conclusion:** Incidence of Ocular trauma was common from 4-40 years. Males are more prone for trauma. Single repair gives good results i.e. 6/12. Patients requiring more than one surgeries got <6/12 vision. Patients who presents with endophthalmitis and Retinal detachment had poor visual prognosis.

**Keywords:** Penetrating trauma, Corneal tear, Corneo-scleral tear, Scleral tear, Endophthalmitis, Retinal detachment.

### Introduction

Negrel and Thylefors reported that worldwide 1.6 million people are blind secondary to ocular injuries, 2.3 million with low visual acuity bilaterally and 19 million with unilateral blindness or low vision.<sup>(1)</sup>

Penetrating injuries known to carry a poor prognosis than blunt injuries. The prognosis for severely injured eyes has improved with the development of advance microsurgical technique and better understanding of reaction to trauma and judicious use of Systemic and topical steroid.<sup>(2)</sup>

### Aim

To study the visual outcome in the cases of penetrating trauma after primary and secondary repair.

### Materials and Methods

This is a prospective interventional study conducted at Sarojini Devi eye hospital/ Regional institute of Ophthalmology during January 2000 to December 2002. 909 cases of penetrating ocular trauma of all ages presented at Sarojini Devi eye hospital were included in the study. The cases who underwent ocular surgery prior to trauma were excluded from the study.

All the cases were admitted in hospital and examined by an experienced Ophthalmologist using Slit lamp, Direct and indirect Ophthalmoscope, 90 D fundus examination. Visual acuity was recorded using Snellens chart.

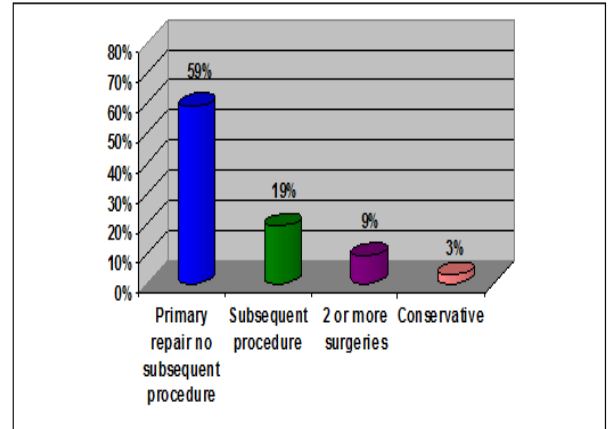
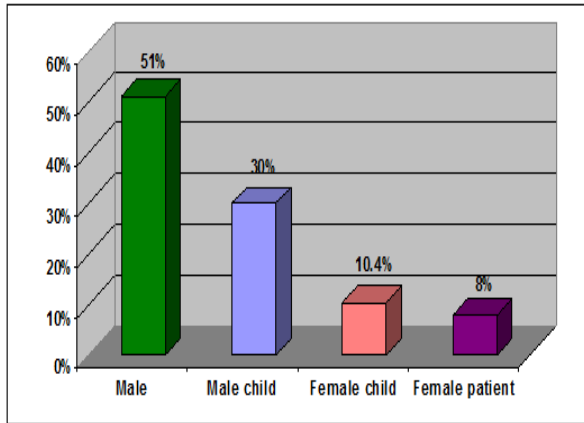
X-ray Orbit, B scan was performed in all cases to evaluate the posterior segment and to rule out retained intra-ocular foreign body. CT Scan was done to localise the foreign body. Electro Physiological evaluation like VEP done in selected cases.

Primary repair was undertaken immediately like suturing Corneal tear using 10'0 Nylon suture, Corneo sclera tear and Scleral tear was sutured using 6'0 prolene suture. Patient was given systemic antibiotics and steroids. Topical Antibiotic steroid combination eye drops like Ciprofloxacin and dexamethasone and cycloplegic eye drops like Cyclopentolate were prescribed. Patients who sustained injury with vegetable matter were put on Anti fungal eye drops like Natamycin or Fluconazole eye drops. All cases were followed up to 6 months to 2 years.

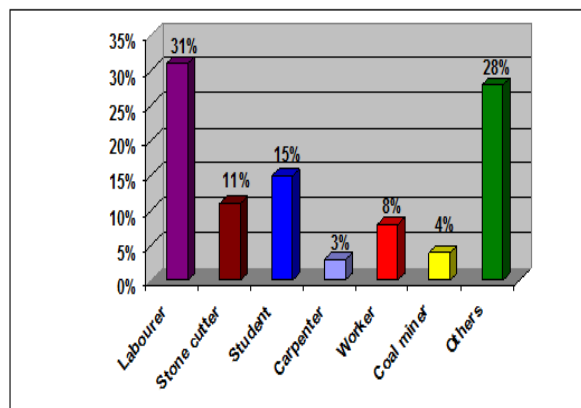
Secondary procedure like Cataract extraction, Vitrectomy for Vitreous hemorrhage and Endophthalmitis, IOFB removal, Retinal detachment surgery was taken once eye became quite.

### Results

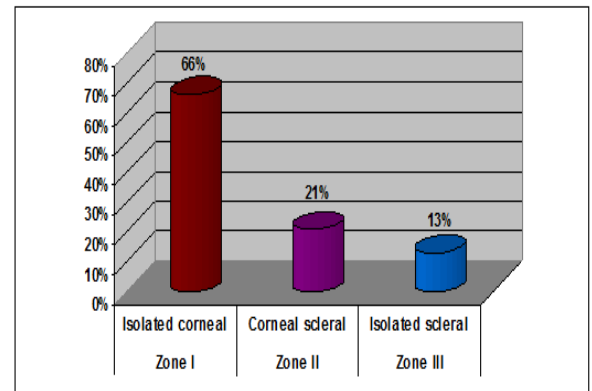
909 patient admitted in Sarojini Devi Eye Hospital with penetrating ocular trauma under corneal services among them 466 (51%) were males, 292 (30%) were male children, 76(8%) were females, 95(10.4%) are female children.



The injured patients according to their profession were as follows.



600(66%) had Zone I injury that is only corneal tear. 191(21%) had Zone II injury i.e. Corneo-Scleral tear. 118 (13%) had Zone III injury i.e. only Scleral tear.

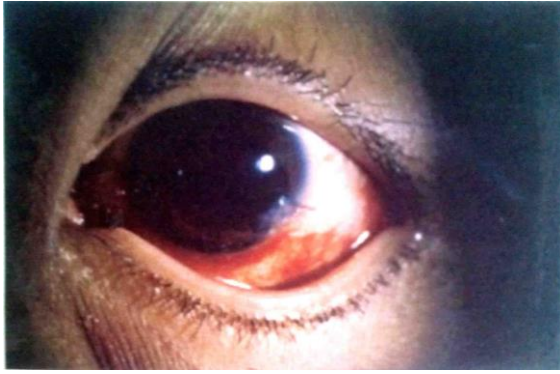

Out of 909 patients 536 (59%) required only primary repair. 173 (19%) had subsequent one more surgery mostly extraction of traumatic cataract with IOL implantation once the inflammation subsided. 82 (9%) had more than two surgeries, i.e., Primary wound repair, extraction of Cataract with implantation of IOL, Pars plana Vitrectomy for Vitreous hemorrhage or IOFB removal or Retinal detachment surgery. 27 (3%) had big sclera tear, with loss of globe content, Endophthalmitis at the presentation itself. These cases end up in Pthisis bulbi

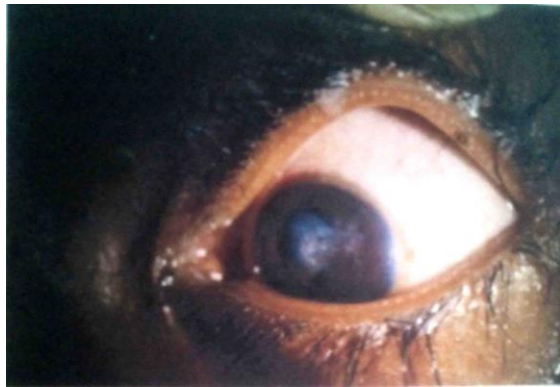418 (46%) patients had 6/12 vision after only primary corneal tear repair. The patients who had < 6/12 vision after primary repair, the reason for this is first group had corneal tear not involving optical zone and second group had tears encroaching optical zone. Best corrected visual acuity achieved by primary repair only is 6/60 in 90 (10%) of patients who had corneal tears involving optical zone.

364 (40%) patients who underwent secondary procedure like Cataract extraction with IOL implantation achieved 6/12 or better visual acuity.

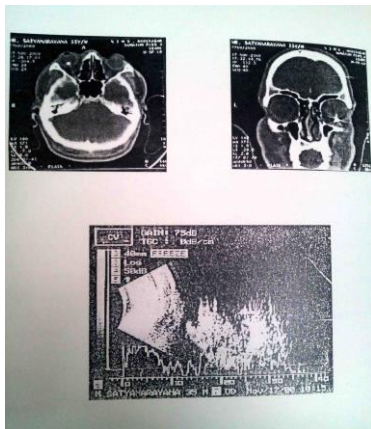
100 (11%) patients had more than two procedure, like Primary repair, Lens extraction with IOL implantation, Pars plana Vitrectomy for Vitreous hemorrhage, IOFB removal or Retinal detachment surgery had less than 6/60 best corrected visual acuity.



**Fig. 1: Corneo sclera tear sutured**



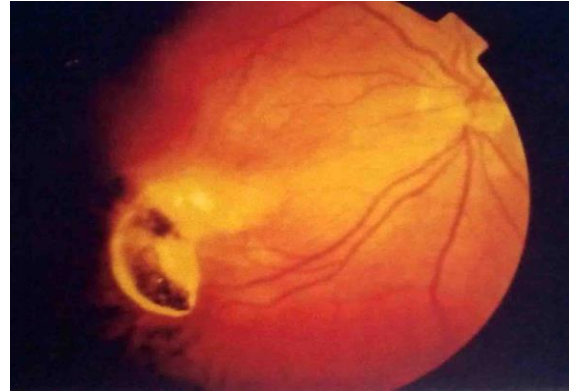
**Fig. 2: Corneal tear involving Optical zone sutured**



**Fig. 3: CT scan and B Scan showing FB in the Coats of eye**



**Fig. 4: B Scan showing FB on Retina**



**Fig. 5: Fundus picture showing FB on Retina**

### Discussion

In present study the sex incidence of Ocular trauma is 81% males and 19% females. Males are 5 times more prone for penetrating trauma than females. This matches with Sana Nadeem et al study which shows sex incidence as 4.9:1 male: female ratio of penetrating trauma<sup>(3)</sup> and Shubhanshu Gupta et al Male: female ratio is 77%: 23%.<sup>(5)</sup> Primary repair of Zone I (only Corneal tear) injury 46% of patients achieved vision of 6/12 or more. This matches with Sohail Zia et al study where they had shown improvement in 45% patients upto 6/12 or more with primary repair only.<sup>(4)</sup> The corneal tear repair and secondary Cataract extraction with IOL implantation done in 45% of the patients in Shubhanshu Gupta et al achieved 6/12 or better visual acuity<sup>(5)</sup> which again matches with present study. In present study 364 (40%) patients underwent primary repair and secondary cataract extraction and IOL implantation achieved 6/12 or better visual acuity. This also matches with Sohail Zia et al study<sup>(4)</sup> and Shubhanshu Gupta et al study.<sup>(5)</sup> 100 (11%) patients underwent more than three procedures like primary repair, Lens extraction with IOL implantation, Pars plana Vitrectomy for Vitreous hemorrhage, IOFB removal or Retinal detachment surgery achieved 6/60 or less vision. This matches with Shubhanshu Gupta et al study where they also achieved same results.<sup>(5)</sup>

### Conclusion

In conclusion the visual outcome was good in patient who had Zone I (only corneal tear) injury not involving optical zone. Even in Zone I injury if Optical zone is involved the visual outcome was poor. In zone II injury (Corneo Scleral tear) 11.5% had good visual outcome. Whereas in Zone III (Scleral tear only) injury visual outcome was poor. Best corrected visual acuity in this group was 6/60 or less. Visual outcome also depends upon length of wound, time lag between injury and repair, Associated infection at the time of injury, Posterior segment involvement like Vitreous hemorrhage, IOFB, Retinal detachment.

**Conflict of interest:** None

**Financial interest:** Nil

**References**

1. Myron Yanoff & Jay Dukers, Ophthalmology 3<sup>rd</sup> edition, Mosby Elsevier 2004.
2. Esmael B et al Ophthalmology 1995 Mar;102(3):393-400.
3. Sana Nadeem et al Pakistan Journal of Ophthalmology Vol. 29 No. 1 Jan-Mar 2013;34-39.
4. Sohail Zia et al Gomal Journal of Medical sciences Vol. 12 No. 2 April-June 2014;57-59.
5. Shubhanshu Gupta et al IJBAR 2015;6(08):589-593.