

## Comparison of three different techniques for fixation of conjunctival autograft in pterygium surgery

Sumita Karandikar<sup>1</sup>, Nita Shanbhag<sup>2</sup>, Nupur Bhatt<sup>3</sup>, Lanin Chen<sup>4\*</sup>

<sup>1</sup>Associate Professor, <sup>2</sup>Professor & HOD, <sup>3,4</sup>Junior Resident, Dept. of Ophthalmology, DY Patil Medical College, Navi Mumbai

**\*Corresponding Author:**

Email: lanin\_chen@hotmail.com

### Abstract

**Aim:** The aim of our study was to evaluate and compare three different surgical options for treatment of pterygium with conjunctival autograft (CAG) using sutures, tissue glue, and autologous in situ blood coagulum.

**Materials and Method:** A prospective randomised clinical study was carried out in 60 patients with progressive nasal pterygium. Patients were randomly grouped into three groups, Group I CAG with 8-0 vicryl sutures (n=20), Group II CAG with tissue glue (n=20), Group III CAG with autologous in situ blood coagulum (n=20). All patients were followed up on day one post-operative, 1 week, 1 month and 6 months post operatively. The surgical time, post-operative discomfort, graft stability, recurrence rate and complications were compared.

**Results:** The average surgical time was statistically more in Group I (p<0.05) being  $44.2 \pm 2.12$  minutes, compared to  $22.25 \pm 0.97$  minutes in Group II and  $24.85 \pm 1.76$  minutes in group III. Post-operative discomfort being maximum in Group I in the early post-operative period which was statistically significant (P<0.05) compared to Group II and Group III. Graft retraction rate was maximum in Group III (15%) compared to Group II (10%) and Group I and (5%). No graft losses were reported. Recurrence rate of (15 %) was seen in Group I, (10%) in Group II, (5%) in Group III at the end of 6 months, not statistically significant.

**Conclusion:** All three techniques are safe and effective in treating primary pterygiums. But tissue glue and autologous in situ blood coagulum techniques significantly reduce post-operative discomfort and surgical time.

**Keywords:** Autologous in situ blood coagulum, Conjunctival autograft, Pterygium, Tissue glue.

### Introduction

Pterygium as defined by Duke-Elder is a triangular shaped degenerative and hyperplastic process, occurring medially and laterally in the palpebral aperture, in which the bulbar conjunctiva encroaches onto the cornea.<sup>(1)</sup> The South Indian Andhra Pradesh Eye Disease Study has reported a pterygium prevalence of 11.7%.<sup>(2)</sup> Diminution of vision either because of induced astigmatism or encroachment upon the pupillary area, marked discomfort and irritation, cosmetically bothersome pterygium become indications for its surgical removal. However the high frequency of recurrence and aggressive nature of recurrent pterygia is a challenging clinical problem. Pterygium surgery today can be divided into four main groups: Bare sclera excision, excision with conjunctival closure/ transposition, excision with antimetabolic adjunctive therapy, ocular surface transplantation techniques.<sup>(3)</sup>

Conjunctival autografting after pterygium excision has been reported to be associated with lower recurrence rate (2% to 9%) and relatively less sight threatening complications.<sup>(4,5)</sup> In the autologous conjunctival autograft technique, after excision of the pterygium, autologous bulbar conjunctiva is fixated upon the exposed scleral bed either using sutures, tissue glue or autologous serum. As it would be beneficial to adapt to the best possible available technique, in this study we have made an attempt to compare the efficacy and complications of three techniques of conjunctival autograft using sutures, tissue glue and autologous in situ blood coagulum.

### Materials and Methods

A prospective hospital based interventional randomised study was carried out between June 2014 to May 2015 where 60 eyes of 60 patients with primary nasal pterygium were included in the study. On the basis of randomisation the patients were divided into three groups consisting of 20 patients each. Group I undergoing CAG with 8-0 vicryl sutures, Group II undergoing CAG with tissue glue and Group III CAG with autologous in situ blood coagulum. The study adhered to the tenets of the declaration of Helsinki for research in humans and informed written consent was obtained from all patients. A detailed pre-operative comprehensive ophthalmic examination was carried out for each patient.

**Inclusion Criteria:** Patients above 18 years of age

All patients with grade 1, 2 and 3 primary nasal pterygium were included in the study.

Grade 1 – encroaches less than 2mm onto the cornea.

Grade 2 – involves upto 4mm of the cornea

Grade 3 – encroaches onto more than 4mm of the cornea<sup>(6)</sup>

**Exclusion Criteria:** Recurrent pterygium, patients with atrophic pterygium, pre-existing glaucoma, previous ocular trauma, history of any blood coagulopathies and a positive serology for HIV, Hepatitis B, pseudopterygium and ocular surface disease like Sjogren syndrome were excluded from the study.

**Surgical technique:** All cases were operated under local anaesthesia (2% lignocaine with 0.75% bupivacaine) by a single operating surgeon (Dr. Sumita Karandikar). In all three groups the technique of Pterygium excision and procurement of graft was same. The head of pterygium was dissected of the underlying corneal epithelium using 15 no. surgical blade / crescent in a clean plane. Body of pterygium measuring at least 4 – 5 mm was carefully dissected from the underlying sclera and excised using Westcott scissors. Exposed cornea scrapped cleaned with a crescent to form a smooth even surface. Dimensions of the recipient site (bare sclera) measured using callipers in millimetres. Superior temporal bulbar conjunctiva of the same eye slightly greater than the recipient site (to counteract graft contracture) was marked. Careful dissection of the superotemporal donor conjunctiva was done leaving the underlying Tenon's behind. Autograft transferred to bare sclera such that the limbal end receives the limbal end of the autograft.

In Group I graft was secured with the help of 8 interrupted sutures using 8/0 vicryl. First the limbal edge was secured with the underlying sclera, then closing the remaining edges with the surrounding conjunctiva.

In Group II, the commercially available tissue glue was reconstituted as per instructions. This tissue glue was placed on to the recipient scleral bed as well as onto the graft. Graft was then flipped, smoothed out and pressed on the scleral bed for 60 seconds ensuring the limbal edges of the graft towards the recipient limbal edge and undermining the free edges of the graft underneath the surrounding conjunctiva.

In Group III, after excising the pterygium, haemostasis was allowed to occur naturally where ever possible, without use of cautery. Careful dissection of donor conjunctival graft was done fashioning a 0.5 mm oversized graft from the superior bulbar conjunctiva.

Limbal edge of the graft was carefully positioned at the host limbal tissue allowing natural graft apposition without tension. Scleral bed was viewed through the transparent conjunctiva ensuring excessive bleeding does not lift up the graft. Graft was held in position by application of gentle pressure over it for 10 minutes.

Eyes were padded for a period of 24 hours. Post-operatively all patients were given an antibiotic drop (moxifloxacin four times a day for two weeks), topical steroid (prednisolone 1% 4 times daily for 2 weeks and then tapered weekly) and carboxymethyl cellulose 0.5% eye drops 4 times a day for 6 weeks. The patients were followed up on day 1 post-operative, one week, one month and six months, were compared for following parameters: 1) Duration of surgery, 2) Post-operative

discomfort, 3) Graft stability, 4) Recurrence at the end of 6 months, 5) Complications.

Surgery time was noted from the first incision until the lid speculum was removed.

Post-operative discomfort included pain, watering, foreign body sensation and was graded as follows:

**Table 1: Post-operative discomfort**

Grade	Symptoms
Grade 0	Nil
Grade 1	Mild lacrimation or pain and irritation
Grade 2	severe lacrimation or pain, foreign body sensation, redness
Grade 3	Inability to open eyes.

Graft stability was assessed based on the following parameters:

**Table 2: Graft stability**

Graft Stability	Clinical Characteristics
Grade 0	All 4 sides of graft margin well apposed
Grade 1	Retraction on one side of graft bed junction
Grade 2	Retraction on two sides of the graft bed junction
Grade 3	Retraction on three sides of graft bed junction
Grade 4	Graft completely displaced from the bed

Recurrence was defined as the presence of fibrovascular tissue regrowth extending beyond the surgical limbus onto clear cornea as agreed by Sebban and Hirst.<sup>(7)</sup>

**Statistical analysis:** All data was evaluated using statistical software minitab 13. Mann-whitney U test and one way ANOVA was used for comparison amongst the three groups. P-values less than 0.05 were considered statistically significant.

## Results

**Pre-operative parameters:** Mean age of patients in Group I (Sutures) was 44.8 with standard deviation of 9.48, Group II (Tissue glue) was 47.9 with standard deviation of 9.03 and in Group III (Autologous in situ blood coagulum) was 49.4 with standard deviation of 8.85.

**Table 3: Age and gender distribution**

	Age		Gender Distribution	
	Mean	Standard Deviation	Male	Female
Group I (Sutures)	44.8	9.48	11	9
Group II (Tissue glue)	47.9	9.03	10	10
Group III (Autologous blood coagulum)	49.45	8.85	12	8

**Surgical time:** The average surgical time was  $44.2 \pm 2.12$  min in Group I (Sutures),  $22.25 \pm 0.97$  min in Group II (Tissue glue) and  $24.85 \pm 1.76$  min in Group III (Autologous in situ blood coagulum). We found a significant difference between Group I and Group II ( $P < 0.05$ ) and in Group I and Group III ( $p < 0.05$ ), however no significant difference was seen between group II and III ( $p > 0.05$ ) in terms of surgical time.

**Post-operative discomfort:** 80% (16/20) patients in (Group I) showed grade 1 and rest 20% (4/20) showed grade 2 post-operative discomfort on first post-operative day which decreased to 80% (16/20) grade 1 discomfort on one week follow up. 40% (8/20) and 30% (6/20) patients showed grade 1 post-operative discomfort in tissue glue and autologous in situ blood coagulum group respectively on day one which reduced on subsequent follow up.

We observed a statistically significant difference between Group I and Group III ( $P=0$ ), Group I and Group II ( $p=0$ ) in terms of post-operative discomfort.

However there was no statistical difference between Group II and Group III ( $P=0.75$ ) in terms of post-operative discomfort.

**Table 4: Post-operative discomfort**

	Day 1 (n=20)	One week (n=20)	One month (n=20)	6 months (n=20)
Group I	16/20	16/20	0/20	0/20
Group II	8/20	1/20	0/20	0/20
Group III	6/20	0/20	0/20	0/20

**Graft stability:** One case (5%) in Group I showed a medial edge retraction on one week follow up due to a loose suture giving away. Two cases (10%) in Group II showed grade 1 retraction on day one which healed on subsequent follow up by re epithelialisation. Three cases (15%) in Group III, two showed grade I retraction and one case showing grade 2 retraction (superior and medial edge retraction) needed secondary intervention to secure the graft with two 8/0 vicryl sutures. However no graft losses were reported. Graft stability was least in autologous serum group.

**Table 5: Graft stability at day one and one week**

Graft Retraction	Grade 1		Grade 2		Grade 3		Grade 4	
	Day 1	One Week	Day 1	One Week	Day 1	One Week	Day 1	One Week
Group I	0/20	1/20	0/20	0/20	0/20	0/20	0/20	0/20
Group II	2/20	1/20	0/20	0/20	0/20	0/20	0/20	0/20
Group III	2/20	1/20	1/20	0/20	0/20	0/20	0/20	0/20

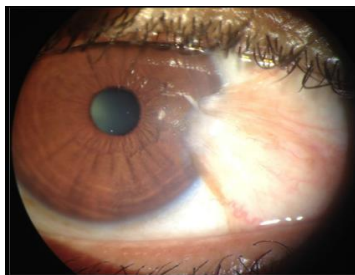
**Table 6: Recurrence Rate**

Group	Recurrence rate at 6 months	
	Count	Percent
Group I	3/20	15
Group II	2/20	10
Group III	1/20	5

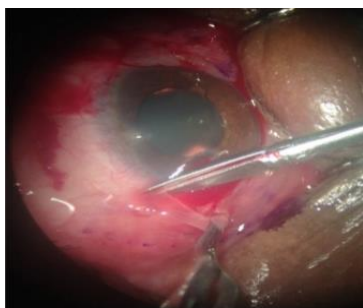
Recurrence rate of 15% (3/20) was seen in Group I, 10% (2/20) in Group II, 5% (1/20) in Group III. Not statistically significant.

**Complications:** We encountered one case of suture granuloma in the suture group on one week follow up

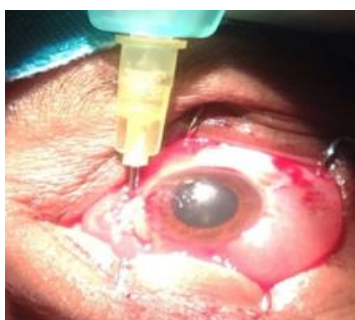and one case of subconjunctival haemorrhage under the graft was seen in the tissue glue group. Post operatively in all cases donor site healed well without any complication.



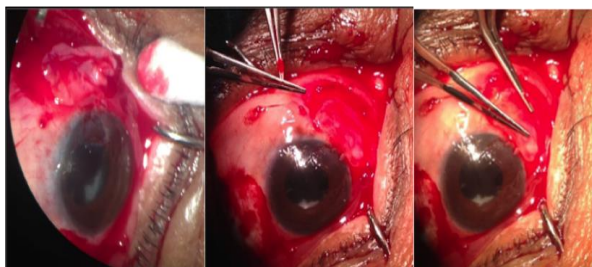
**Fig. 1: Pterygium**



**Fig. 2: CAG with sutures**



**Fig. 3: CAG with tissue glue**



**Fig. 4: CAG with autologous in situ blood coagulum**

## Discussion

The “ideal” pterygium surgery is still an ongoing debate. To prevent recurrence of pterygium many surgical techniques have been developed such as beta-irradiation, mitomycin C, human amniotic membrane grafting, conjunctival autograft. Conjunctival autografting has been proved to be the safest and effective method.<sup>(8-10)</sup>

Conjunctival autograft transplantation, as a treatment for pterygium was first described by Kenyon and associates in 1985.<sup>(4)</sup> This technique started with suturing of autologous graft. Over the years, tissue glue

and autologous in situ blood coagulum emerged as alternatives to sutures for securing the conjunctival graft.

Most of the studies have compared suture with tissue glue technique. We found only few comparable studies where all three techniques were compared like our study.

**Surgical time:** Suturing of the autograft necessitates surgical experience and technical skill, further more increasing the patient discomfort and surgical time.<sup>(11)</sup> Vichare et al in their study of 60 patients comparing sutures to fibrin glue reported an average surgical time of  $50.93 \pm 4.96$  minutes with suture group and  $34.43 \pm 4.94$  minutes with fibrin glue group<sup>(12)</sup> supporting the findings in our study. Our observations were comparable to the findings seen by Uy et al, Bahar et al, Srinivasan et al in their studies comparing similar parameters.<sup>(13-15)</sup> Sati et al in their study showed that the surgical time taken in suture group was more than tissue glue ( $p < 0.001$ ) and autologous blood coagulum ( $p < 0.001$ ). Also tissue glue cases taking significantly more time compared to autologous blood coagulum ( $p < 0.001$ ).<sup>(16)</sup> Our study showed a similar result where the suture group took maximum surgical time among all three with statistically significant difference between them ( $p < 0.5$ ). However, average surgical time was more in autologous serum group when compared to tissue glue only but the difference was not statistically significant.

**Post-operative discomfort:** Koranyi et al. in their study of comparing 8-0 vicryl suture to fibrin glue found that patient discomfort was less in the fibrin group, which showed similar results as our study ( $p < 0.05$ ). The upregulated inflammatory process during suture degradation may add to the significantly more post-operative pain in the suture group, they also reported that the flip over manoeuvre while using tissue glue leaves a thin membrane of glue over the corneal epithelial, thus covering the exposed corneal nerve endings, contributing to a decrease in post-operative pain.<sup>(17)</sup>

**Graft stability:** Milind Surayanshi in their study reported a (13%) retraction in the fibrin group and (13%) in the suture group.<sup>(18)</sup> Vichare et al in their study showed a (16%) retraction rate with tissue glue compared to (10%) with sutures.<sup>(12)</sup> The authors cited that the higher rate of graft retraction in the non-suture group can be due to movement of the graft, due to lid movement causing displacement of the graft and tissue glue is vulnerable to mechanical forces hence the importance of post-operative care must be explained to the patients in detail. De wit el proposed that the apposition of the lids to the bulbar conjunctiva provides a natural biological dressing and a good wound healing environment. Thus allowing the use of free conjunctival autografts without sutures or tissue glue. In their study of sutureless and glue free conjunctival autograft they found no transplant dislocations.<sup>(19)</sup> Mitra et al in their study of 19 patients

undergoing autologous blood graft fixation reported no graft losses at the end of 6 months, with two cases of medial edge graft retraction.<sup>(20)</sup> Singh Pk et al found greater graft displacement and graft retraction in patients with autologous blood (10%) than in those undergoing grafting with the glue. But not statistically significant ( $p=0.3185$ )<sup>(21)</sup> which was similar to results found in our study. In a study on 60 eyes which included 56% grade 2 pterygia, Dasgupta et al reported partially displaced graft in 2% patients with technique of autologous blood coagulum.<sup>(22)</sup>

**Recurrence rate:** Oswald had suggested that immediate adherence of the graft and lack of post operative inflammation in glue technique may inhibit fibroblast ingrowth and reduce the recurrence. A study by them reported the recurrence rate of 5.3% for fibrin glue versus 13.5% for sutures.<sup>(23)</sup> Alok Sati et al in their study of 90 eyes comparing the efficacy of three surgical methods of conjunctival autograft fixation in the treatment of pterygium using sutures, tissue glue and autologous blood found a similar recurrence rate amongst the three groups ( $p=0.585$ ).<sup>(16)</sup> In our study comparing the same techniques under similar parameters found a recurrence rate of 15%, 10%, 5% in Groups I, II, III respectively without a significant difference ( $p>0.05$ ).

### Complications

**Problem with sutures:** The presence of sutures may lead to subsequent complications such as pyogenic granuloma formation. Others such as symblepharon formation, forniceal contracture, ocular motility restriction.<sup>(11)</sup> We encountered a case of suture granuloma in the suture group on one week follow up, sutures and granulomatous tissue was removed on the 10<sup>th</sup> post-operative day. No granuloma recurrences were noted on further follow up. Bora Yuksel et al reported suture granulomas in 7 patients in their study of the 29 patients in suture group where they used 8-0 virgin silk.<sup>(24)</sup> Bahar et al observed a case of corneal dellen in the suture group in their study and treated it with lubrication.<sup>(15)</sup>

**Problem with the tissue glue:** The main issue in using commercial fibrin glue despite viral inactivation techniques, is the transmission of infectious agents such as parvovirus and prions.<sup>(25)</sup> Furthermore, anaphylactic reaction has been reported after the use of (TISSEEL) fibrin sealant which was due to bovine protein aprotinin.<sup>(23)</sup> We did not encounter any such problem with tissue glue use in our study. One case of subconjunctival haemorrhage under the graft was encountered in our study with fibrin glue which resolved in two weeks on its own. Uy et al also reported a subconjunctival haemorrhage in the tissue glue group which resolved on its own in three weeks.<sup>(13)</sup> Kulthe et al reported one case of cyst formation in their study of 77 eyes with autologous blood technique.<sup>(26)</sup>

### Limitations of the study

The study population and follow up time were relatively small in our study. Study group had all three grades of pterygium which could have affected the surgical outcome. No blinding technique was used in the analysis of postoperative discomfort, though it was done by doctors other than operating surgeon.

### Conclusion

All three techniques have equal recurrence rates. But there is reduced surgical time, less post-operative discomfort and suture related complications with tissue glue and autologous in situ blood coagulum. Greater chances of graft retraction in the early post-operative period are of concern with these two techniques owing to their vulnerable nature to mechanical forces. Care must be taken to harvest slightly larger grafts and undermining them under the recipient conjunctival pockets with adequate explanation of post-operative care while using these techniques. For larger pterygia, tissue glue is a better option to ensure greater graft stability, smaller pterygia are most suitable and cost effective for autologous in situ blood coagulum.

### References

1. Duke-Elder S, St Louis . *Textbook of ophthalmology*. Mosby; 1954.
2. Marmamula S, Khanna RC, Gullapalli RN (2013). Population based assessment of prevalence and risk factors for pterygium in south Indian state of Andhra Pradesh: the Andhra Pradesh Eye Disease Study (APEDS). *Invest Ophthalmol Vis Sci* 2013;54(8):5359-66.
3. Hirst LW. The treatment of pterygium. *Surv Ophthalmol*. 2003;48(2):145-80.
4. Kenyon KR, Wagoner MD, Hettlinger ME. Conjunctival autograft transplantation for advanced and recurrent pterygium. *Ophthalmology*. 1985;92(11):1461-70.
5. Allan BD, Short P, Crawford GJ. Pterygium excision with conjunctival autografting: an effective and safe technique. *Br J Ophthalmol*. 1993;77:698-701.
6. Jack J Kanski, *Clinical ophthalmology*; Asytematic approach; Elsevier Saunders: 7<sup>th</sup> edition.
7. Sebban A, Hirst LW. Pterygium recurrence rate at the Princess Alexander Hospital, Aust N Z J Ophthalmol 1991;19:203-6.
8. Luanratanakorn P, Ratanapakorn T, Suwan-apichon O, Chuck RS. Randomised controlled study of conjunctival autograft versus amniotic membrane graft in pterygium excision. *The British Journal of Ophthalmology*. 2006;90(12):1476-1480.
9. Hayasaka S, Noda S, Yamamoto Y. et al Postoperative instillation of low-dose mitomycin C in the treatment of primary pterygium. *Am J Ophthalmol* 1988;106:715-718.
10. Akarsu C, Taner P, Ergin A. 5-Fluorouracil as chemoadjuvant for primary pterygium surgery: preliminary report. *Cornea* 2003;22(6):522-526.
11. Ozdamar Y<sup>1</sup>, Mutevelli S, Han U, et al. A comparative study of tissue glue and vicryl suture for closing limbal-conjunctival autografts and histologic evaluation after pterygium excision. *Cornea*. 2008;27(5):552-558.
12. Nitin Vichare, Lt Col, Tarun Choudhary, Surg Cdr, and Priyanka Arora. A comparison between fibrin sealant and sutures for attaching conjunctival autograft

- after pterygium excision. *Med J Armed Forces India.* 2013;69(2):151–155.
13. Uy HS, Reyes JMG, Flores JDG, Lim-Bon-Siong R. Comparison of fibrin glue and sutures for attaching conjunctival autografts after pterygium excision. *Ophthalmology.* 2005;112(4):667–679.
  14. Srinivasan S, Dollin M, McAllum P, Berger Y, Rootman DS et al. Fibrin glue versus sutures for attaching the conjunctival autograft in pterygium surgery: a prospective observer masked clinical trial. *Br J Ophthalmol.* 2009;93(2):215–218.
  15. Bahar I, Weinberger D, Gatton DG, Avisar R. Pterygium surgery fibrin glue versus vicryl sutures for conjunctival closure. *Cornea.* 2006;25(10):1168–1172.
  16. Alok Sati, Sandeep Shankar, Ashok Jha et al. Comparison of efficacy of three surgical methods of conjunctival autograft fixation in the treatment of pterygium. *Int Ophthalmol.* 2014;34:1233-1239.
  17. Koranyi G, Seregard S, Kopp ED. Cut and paste: a no suture, small incision approach to pterygium surgery. *Br J Ophthalmol.* 2004;88(7):911–914.
  18. Milind Suryawanshi, Rohini Suryawanshi. Pterygium Surgery: Free Conjunctival Graft with Fibrin Glue versus Sliding Conjunctival Graft with Sutures: A Comparative Study. *Sch. J. App. Med. Sci.,* 2015;3(1D):276-280.
  19. Wit D, Athanasiadis I, Sharma A, Moore J. Sutureless and glue free conjunctival autograft in pterygium surgery: a case series. *Eye* 2010;24:1474-77.
  20. Mitra S et al. Auto blood as tissue adhesive for conjunctival autograft fixation in pterygium surgery. Poster presented at the Annual Meeting of the American Academy of Ophthalmology; Oct. 22 and 23, 2011; Orlando, Fla.
  21. Singh PK, Singh S, Vyas C, Singh M. Conjunctival autografting without fibrin glue or sutures for pterygium surgery. *Cornea.* 2013;32:104-7.
  22. Dasgupta S, Vats V, Mittal SK. Pterygium excision with suture free, glue free conjunctival autograft (SFGF-CAG): Experience of tertiary care hospital of the Northern India. *J Clin Ophthalmol Res* 2016;4:143-8.
  23. B.M. Oswald, LM July, C. Gury, M. Disdet, V. Leclue. Fatal intra operative anaphylaxis related to aprotinin after local application of fibrin glue. *Anaesthesiology,* Vol. 99, 2003 pp. 762–763.
  24. Bora Yüksel, Sultan Kaya nsal, Sevgi Onat. Comparison of fibrin glue and suture technique in pterygium surgery performed with limbal autograft. *International Journal of Ophthalmology.* 2011;11(2):205-209.
  25. A. Foroutan, F. Beigzadeh, M.J. Ghaempanah, P. Eshghi et al. Efficacy of autologous fibrin glue for primary pterygium surgery with conjunctival autograft. *Iranian J. ophthalmol.,* Vol. 23, 2011, pp 39-47.
  26. Kulthe SB, Bhosale AP, Patil PU. Is the surgical technique of a sutureless and glue free conjunctivolimbal autograft after pterygium excision complication free?. *Med J DY Patil Univ.* 2015;8:308-12.