

Prospective clinical study on visual outcome following uveitis

Raja Rengaraj^{1,*}, Thailnayaki Vellaichamy²

¹Associate Professor, ²Assistant Professor, Dept. of Ophthalmology, Thanjavur Medical College, Tamil Nadu

***Corresponding Author:**

Email: rajarengaraj1973@gmail.com

Abstract

Introduction: Uveitis is one of the most common form of intraocular inflammation causing vision loss either directly or via complications such as cataract, glaucoma, macular edema and others.

Aims and objectives:

1. To evaluate the etiology, clinical features, systemic associations and Severity of uveitis.
2. To analyse the visual outcome following uveitis.

Materials and Methods: This is a prospective study which includes 80 patients with anterior uveitis of various etiologies presented to our department at Thanjavur medical college from July 2014 – September 2015. They were subjected to detailed clinical examination and relevant investigations. A proforma was drawn up and following details were recorded for each patient: age and sex, history related to trauma, surgery and specific systemic associations of uveitis, clinical examination of signs and symptoms of uveitis including general systemic examination. They were treated and reviewed according to the severity of uveitis and followed up for a period of three months. According to improvement / worsening of the disease activity they were further managed.

Observation and Results: The ratio of uveitis in male to female is 1.66:1 with 96.25% unilateral and 3.75% bilateral presentation. With regard to etiology 17.5% had idiopathic, 8.75% infective, 47.50% traumatic, 5% lens induced and 21.25% postoperative uveitis. Vision loss accounted in 7.5% due to cataract, 6.25% due to macular edema and 10% due to glaucoma. Visual outcome improved in 91.25% of these patients. Blindness due to anterior uveitis is 1.25%.

Conclusion: Uveitis continues to be the major cause of ocular morbidity. But patients get good final visual outcome with detailed clinical examination and initiation of proper management.

Cases presented earlier even with severe uveitis had favourable response to treatment and good prognosis in visual outcome than those presented late with uveitic sequelae and with co-morbid risk factors irrespective of etiology.

Keywords: Anterior uveitis, Idiopathic, Traumatic uveitis, Visual outcome

Introduction

Uveitis is one of the most common form of intraocular inflammation. The variation in the spectrum of the disease is due to complex geographic, ecological, racial and socio economic differences. It causes vision loss either directly or via complications such as cataract, glaucoma, macular edema and others.

Anterior uveitis is common among all types of uveitis (57.4%) with an incidence of 17 cases per 100,000 population. Acute anterior uveitis cause painful red eye with mild vision loss but still contributes significantly to overall burden. The precise cause of anterior uveitis is obscure and correct diagnosis and management is quite challenging. The morbidity associated is moderately high.

Acute, unilateral, non-infectious and non-granulomatous forms of anterior uveitis occur more frequently. Idiopathic anterior uveitis is common in all age groups. Mean age of presentation is 38 years. It is common in males (62.5%) compared to females (37.5%).

Aims and Objectives

1. To evaluate the etiology, clinical features, systemic associations and Severity of uveitis.
2. To analyse the visual outcome following uveitis.

Inclusion criteria: Patients diagnosed with anterior uveitis

Exclusion criteria:

Recurrent Uveitis

Patients with associated ocular co-morbidities affecting vision

Materials and Methods

This is a prospective study which includes 80 patients with anterior uveitis of various etiologies presented to our department at Thanjavur medical college from July 2014 – September 2015. They were subjected to detailed clinical examination and relevant investigations.

A proforma was drawn up and following details were recorded for each patient: age and sex, history related to trauma, surgery and specific systemic associations of uveitis, clinical examination of signs and symptoms of uveitis including general systemic examination. Ocular examination in this study included: A thorough examination with diffuse illumination, Visual acuity by snellens chart, Slit lamp examination, Intraocular pressure with applanation tonometry, Gonioscopy, Direct and indirect ophthalmoscopy, B-scan ultrasonography, PCR of aqueous fluid.

Patients were examined by other specialties like general medicine, ENT, Dental, Dermatology, Obstetrics and gynecology for specific systemic examination.

Patients with mild uveitis at presentation were treated as out-patients and those with severe uveitis were hospitalized for evaluation and appropriate management. They were reviewed according to the severity of uveitis and followed up for a period of 3 months. According to the improvement/worsening of the disease activity they were further managed.

Results

- In this study of 80 patients, the preponderance of male patient was noted with male: female ratio of 1.66:1.
- Unilateral eye involvement (96.25%) was more commoner than bilateral involvement and commonest in the age group of 11-20 years (35%).
- Non-infectious etiology (trauma 47.50%) predominates the causes.
- Visual acuity improved in 91.25% and worsened in 1.25%.
- Blindness due to anterior uveitis was 1.25%.

Table 1: Age wise distribution

Age in years	No. of cases	Percentage (%)
1 to 10	2	2.50
11 to 20	28	35.00
21 to 30	8	10.00
31 to 40	13	16.25
40 to 50	8	10.00
>50	21	26.25

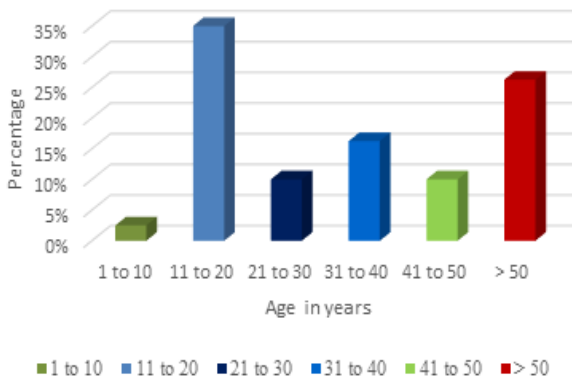


Fig. 1: Age distribution

Table 2: Sex distribution

Sex	No. of cases	Percentage (%)
Male	50	62.50
Female	30	37.50

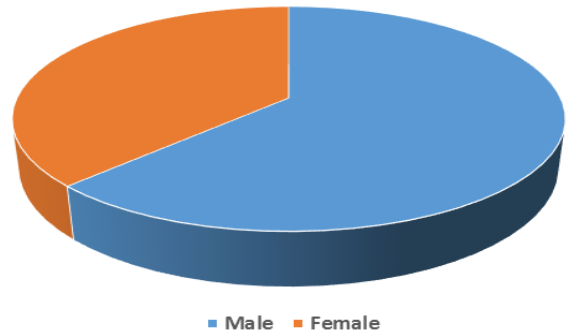


Fig. 2: Sex distribution

Table 3: Eye involvement – laterality

Eye involved	No. of cases	Percentage %
Unilateral	77	96.25
Bilateral	3	3.75

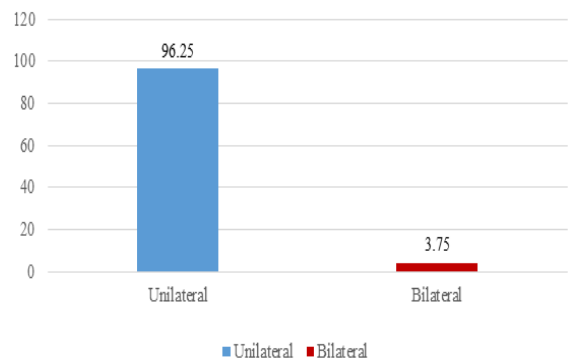


Fig. 3: Eye involved – laterality

Table 4: Classification based on etiology

Etiology	No. of cases	Percentage %
Trauma	38	47.50
Lens induced	4	5.00
Infections	7	8.75
Idiopathic	14	17.50
Postoperative uveitis	17	21.25

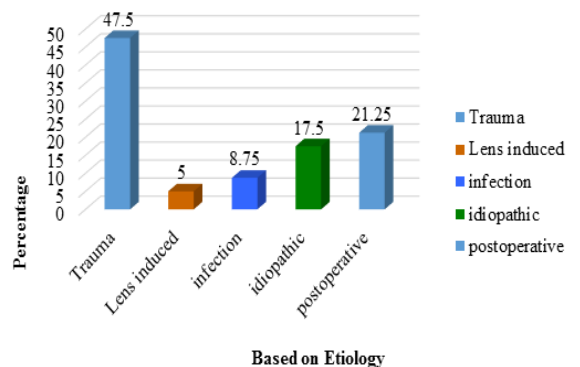


Fig. 4: Classification based on etiology

Table 5: Complications of uveitis

Complications	No. of cases	Percentage %
Cataract	6	7.50
Glaucoma	8	10.00
Macular edema	5	6.25
Post-operative flare up	9	11.25

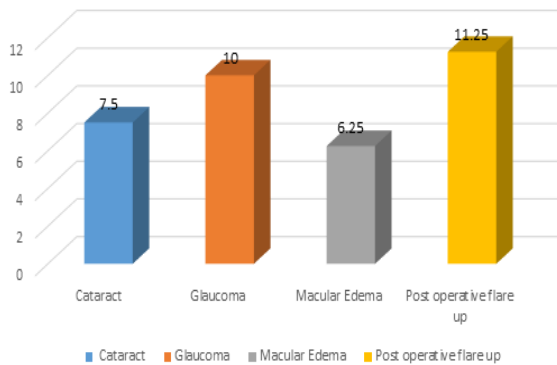


Fig. 5: Complications of uveitis

Table 6: Visual outcome following management

Visual outcome	No. of cases	Percentage %
Improved	73	91.25
Static	6	7.50
Worsened	1	1.25

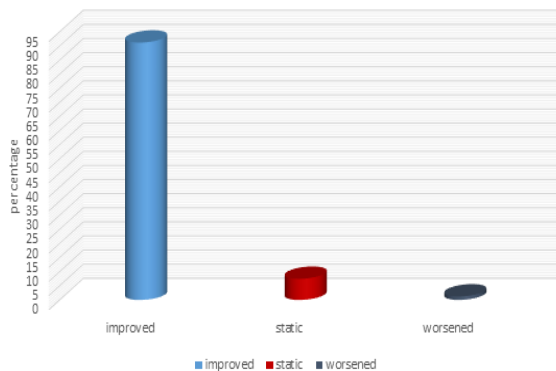


Fig. 6: Visual outcome following management

Discussion

This prospective study of 80 patients with anterior uveitis was done to analyse the final visual outcome following proper treatment.

In the earlier studies conducted in South India the ratio of uveitis in male to female was 1.5:1. In our study the ratio is found to be 1.66:1.

In a study conducted by Rathinam et al about global variation in pattern and changes in epidemiology of uveitis (2007),⁽¹⁾ uveitis is 85.3% unilateral and 14.7% bilateral. In our study 96.25% had unilateral and 3.75% had bilateral presentation of uveitis.

Regarding the study conducted by Rathinam et al(2007),⁽¹⁾ 60 – 80% of the patients were in the age group between 30 and 60 years, 5–16% belong to age group less than 16years and 6–21.8% were more than 60 years. In our study 52.50% were in the age group between 30 and 60 years, 22.50% belong to the age group less than 16 years and 26.50% were more than 60 years.

In a study conducted by Rathinam et al about global variation in pattern and changes in epidemiology of uveitis (2007)⁽¹⁾ with regard to etiology, in 44.6% uveitis is idiopathic, 27.3% had infectious uveitis, 3.9% had traumatic and 10.6% had lens induced uveitis. In our study, 17.50% is idiopathic, 8.75% had infective uveitis, 47.50% had traumatic, 5% lens induced uveitis and 21.25% had post-operative uveitis.

In a data collected from 12 countries by Hormoz et al (1960–2009), the pre-valance of idiopathic uveitis is 17.4% in 1960 and more recent data reported to be 52%. In almost all these reports non-infectious causes predominated (45 – 94.8%) than infectious causes which are common in developing countries. In our study non-infectious causes (73.75%) predominated infectious causes of uveitis.

In a study by OM Durrani⁽⁸⁾ regarding severity, duration and vision loss in uveitis, vision loss in uveitis accounted 17.7% due to cataract and 26.8% due to macular edema. In our study 7.50% had cataract, 6.25% had macular edema and 10% had glaucoma.

In studies conducted earlier, anterior uveitis had good visual prognosis showing improvement in 80% and in our study visual outcome improved in 91.25% of the patients.

Blindness due to anterior uveitis reported in literature is 4% and in our study blindness due to anterior uveitis is 1.25%.

Conclusion

To conclude the study, recognition of ocular diagnostic clues is essential in making clinical diagnosis of specific entities as well as in guiding investigations.

Corticosteroids have been the cornerstone in the treatment of uveitis. Steroids are used aggressively in a step ladder algorithm for resolution of inflammation through various routes and a gradual taper is essential to achieve a level of remission. Other treatment modalities included cycloplegics, NSAIDS, immunomodulators, systemic therapy with close monitoring of side effects.

Cases presented earlier even with severe uveitis had favorable response to treatment and good prognosis in visual outcome than those presented late with uveitic sequelae and with co-morbid risk factors irrespective of etiology.

Uveitis of unknown etiology still accounts as a cause of anterior uveitis with significant number of cases contributing to it.

Though the proportion of blindness due to anterior uveitis is decreasing because of emerging treatment

options, some patients experience vision loss at some point during their clinical course. Visual morbidity following anterior uveitis can be prevented by prompt diagnosis and judicious management, achieving gratifying results in visual outcome.

References

1. Rathinam SR, Namperumalsamy P. Global variation and pattern changes in epidemiology of Uveitis. *Indian J Ophthalmol* 2007;55:173-83.
2. Nussenblatt RB. The natural history of uveitis. *Int Ophthalmol* 1990;14(5-6).
3. Rathinam SR, Cunningham ET Jr. Infectious causes of uveitis in the developing world. *Int Ophthalmol Clin* 2000;40(2),137-52.
4. De Boer, Wulffraat N, Rothova A. Visual loss in uveitis of childhood. *Br J Ophthalmol* 2003;87(7):879-84.
5. Hooper PL, Rao NA, Smith RE, Cataract extraction in Uveitis patients. *Surv Ophthalmol* 1990;35:120-144.
6. Mapstone R, Woodrow JC. HLA - B 27 and acute anterior uveitis. *Br J Ophthalmol* 1975,59;270-275.
7. Okhravi N, Lightman SL, Towler HM. Assessment of visual outcome after cataract.
8. Durrani OM, Tehrani NN, Marr JJ, Moradi P, Stavrou P, Murray PI: Degree, duration and causes of visual loss in uveitis. *Br J Ophthalmol* 2004,88;1159-1162.