

PARTIAL THICKNESS SCLERAL MICRO-PATCH GRAFT, AUTOCONJUNCTIVAL GRAFT AND FIBRIN GLUE IN MANAGEMENT OF SURGICALLY INDUCED NECROTIZING SCLERITIS

Tarun Arora^{1,*}, Supriya Arora², Vijay Sharma³

^{1,3}Rajendra Prasad Centre for ophthalmic sciences, All India institute of medical sciences

²Guru Nanak Eye Centre, Maulana Azad Medical College

***Corresponding Author:**

E-mail: tarunmamc04@gmail.com

ABSTRACT

A 45-year-old male patient presented with necrotizing scleritis after 2 weeks of having undergone pterygium surgery with bare sclera technique. Examination revealed a scleral thinning measuring 3 x 3 mm with anterior chamber inflammation. Lamellar scleral graft was dissected from the donor sclera and trephined to the approximate size of the scleral melt. Edges of the host scleral melt were freshened and fibrin tissue glue was used to attach the lamellar graft at the site of defect. Conjunctival autograft was simultaneously harvested from superior quadrant and attached over the bare sclera with the help of fibrin glue. Postoperatively the patient was prescribed high dose oral steroids along with topical antibiotics, steroids and lubricants. The patient improved symptomatically and showed good graft apposition.

Keywords: Autoconjunctival graft, Scleral patch graft, Necrotizing Scleritis.

INTRODUCTION

Surgically induced necrotising scleritis (SINS), is a rare complication of ocular surgery. Lyne et al¹ described a series of patients without history of scleritis who developed scleral inflammation around a surgical wound. The aetiology of SINS has not been established. However it is known to occur after cataract extraction, strabismus surgery, trabeculectomy and surgery for retinal detachment². SINS have also been associated with multiple surgical procedures, co-existent systemic collagen vascular disease, and usage of general anesthesia, local ischemia and excessive cautery. Various treatment modalities have been advocated including nonsteroidal anti-inflammatory agents (NSAIDs), high doses of systemic steroids, pulsed intravenous steroids, cytotoxic agents and surgery.

CASE REPORT

A 45-year-old male patient presented to our emergency services with redness and pain in left eye since 2 weeks. The patient had undergone a pterygium surgery with bare sclera technique 2 weeks back. The patient had been on topical 0.3% gatifloxacin and topical lubricants in the immediate postoperative period. Examination revealed

presence of necrotizing scleritis in the nasal sclera with scleral thinning measuring 3 x 3 mm (**Figure 1**). Surrounding conjunctiva was highly inflamed. Anterior chamber revealed presence of 2+ cells. Visual acuity was 20/20 in both eyes. Patient was taken for surgery under peribulbar anesthesia. Donor sclera was harvested from the available enucleated eye bank eyeball, soaked in antibiotic (0.3% gatifloxacin and gentamycin 40 mg/mL) and again cleaned with Betadine (5% povidone-iodine ophthalmic solution, Alcon). After sterile cleaning and draping, the area of scleral thinning was well-defined and exposed. The amount of scleral tissue to be replaced was 3 x 3mm as measured with calipers. Donor sclera was first trephined using a 3mm trephine. Lamellar scleral graft (50% thickness approximately) was then dissected from the donor sclera(**Figure 2**). Host bed was prepared by resecting the surrounding inflamed conjunctiva. Thinned out scleral bed was dried and margins freshened. Fibrin tissue glue (Tisseel, Baxter AG, Vienna) was premixed in the applicator provided and then applied over the scleral defect. Lamellar scleral graft was placed in the area of defect and edges apposed. Subsequently a 6 x 6 mm conjunctival autograft was prepared from the superior quadrant and placed over the patch graft (**Figure 3**). Fibrin tissue glue

(Tisseel, Baxter AG, Vienna) was premixed in the applicator provided and applied underneath the conjunctival graft. Subsequently the edges of the conjunctiva were apposed. The patient was postoperatively given high dose oral steroids

along with topical antibiotics, steroids and lubricants. The patient symptomatically improved and showed good graft apposition. Pain and redness subsequently disappeared and patient maintained a visual acuity of 20/20 at 2 months of follow up. **(Figure 4)**

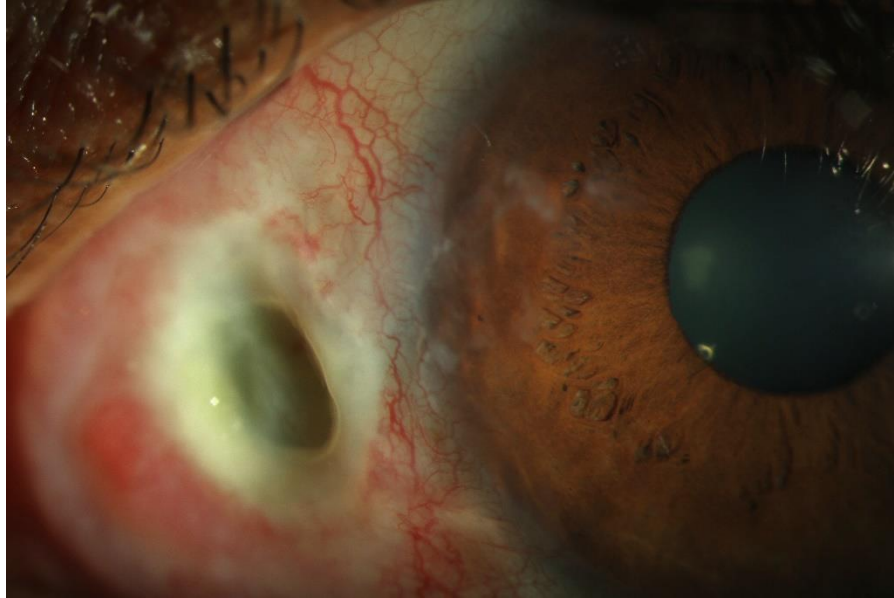


Figure 1: preoperative clinical photograph showing necrotizing scleritis with melt.

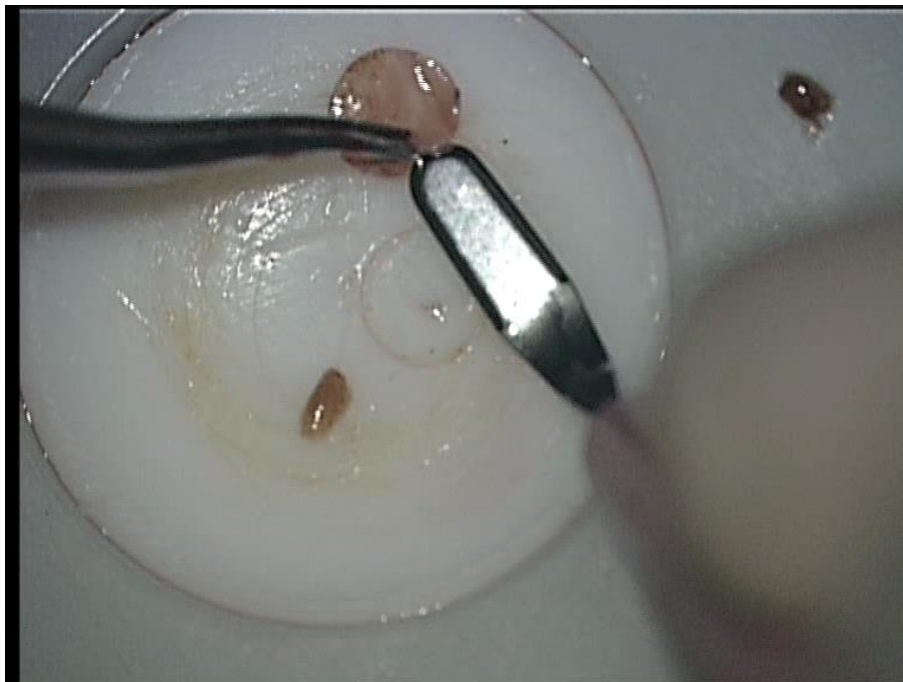


Figure 2: preparation of lamellar micro scleral patch graft

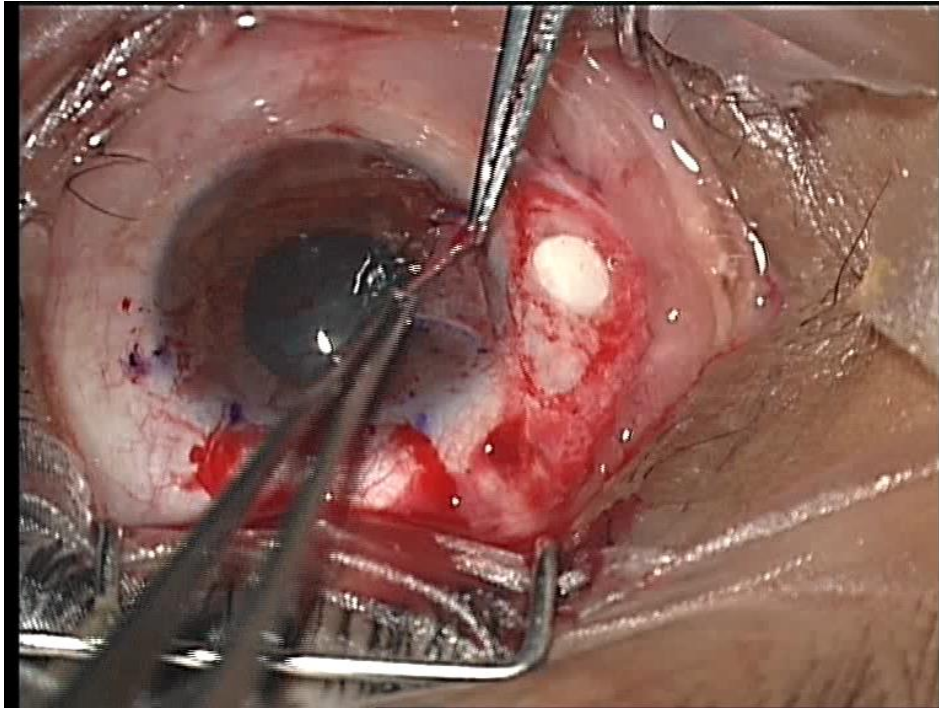


Figure 3: placement of autoconjunctival graft over lamellar scleral patch graft with fibrin glue as adhesive

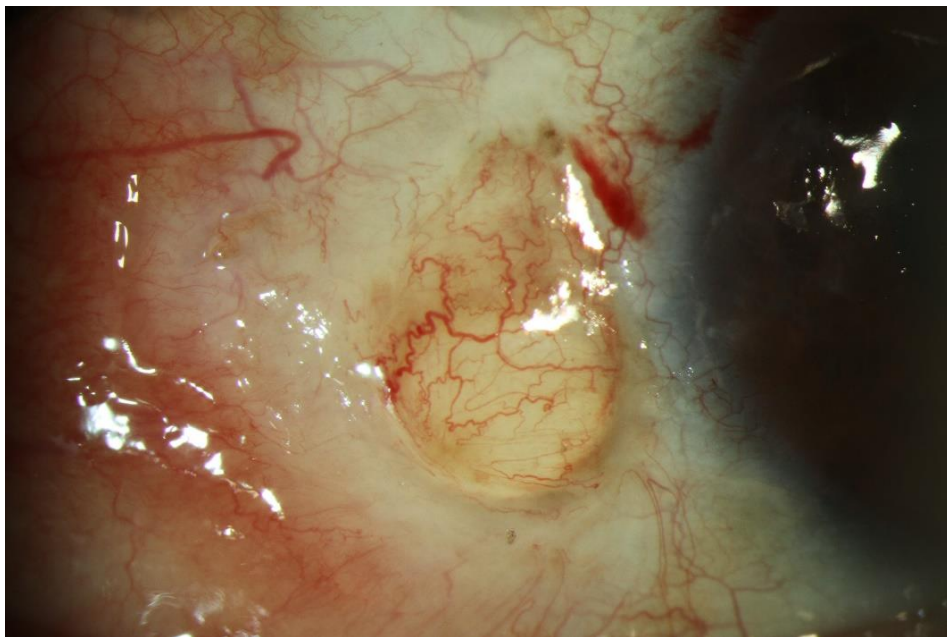


Figure 4: clinical photograph at post op 2 months with sclera patch graft and autoconjunctival tissue well attached

DISCUSSION

Excessive intraoperative cautery to the scleral bed is the leading cause of necrotizing scleritis. Overenthusiastic use of antimetabolites can also lead to scleral complications. Necrotizing scleritis has also been reported after conjunctival autograft.

Although, our patient did not have any systemic predisposition or local risk factor for scleral thinning, such as excess cautery, MMC use or irradiation however the bare sclera technique was performed primarily.

Sanghwan et al³ used full-thickness sclera in cases of scleral defect and sutured

it in place. They covered the graft with a conjunctival flap or amniotic membrane. They believed it to be an effective and simple measure for preserving globe integrity. Casas et al⁴ reported that combination of tenonplasty and amniotic membrane transplantation with or without lamellar corneal patch grafting, by using sutures or fibrin glue, to be a feasible alternative for treating scleral ischemia and/or melt. King et al⁵ described the use of a scleral micro-patch graft and fibrin glue to treat scleral

flap defects following trabeculectomy. They believed that their technique allows a more focused application of a small scleral patch grafts to leaking scleral defects and allows more focused and titrated treatment.

Our case demonstrated that combination of lamellar micro scleral patch graft and autoconjunctival graft with fibrin glue has excellent outcome in case of scleral defect and can be performed in similar situations.

REFERENCES:

1. Lyne AJ, Lloyd-Jones D. Necrotizing scleritis after ocular surgery. *Trans Ophthalmol Soc U.K* 99:146-149, 1979.
2. O'Donoghue E, Lightman S, Tuft S et al. surgically induced necrotizing sclerokeratitis (SINS): Precipitating factors and response to treatment. *Br J Ophthalmol.* 76:17-21, 1992.
3. Sangwan VS, Jain V, Gupta P. Structural and functional outcome of scleral patch graft. *Eye (Lond).* 2007;21(7):930-5.
4. Casas VE, Kheirkhah A, Blanco G, Tseng SC. Surgical approach for scleral ischemia and melt. *Cornea.* 2008;27(2):196-201.
5. King AJ, Rotchford AP. The use of a scleral micro-patch graft and fibrin glue to treat scleral flap defects following trabeculectomy. *Br J Ophthalmol.* 2009;93(9):1269-70.