

OCULO-CUTANEOUS MANIFESTATIONS OF NEUROFIBROMATOSIS TYPE – I: A CASE REPORT

Rajendra P Maurya^{1,*}, Ishan yadav², Virendra P. Singh³,
Mahendra K. Singh⁴, Mohan Kumar⁵

¹Assistant Professor, ²Senior Resident, ^{3,4}Professor, Department of Ophthalmology, ⁴Professor,
Department of Pathology, Institute of Medical Sciences, Banaras Hindu University,
Varanasi-221005 UP, India

***Corresponding Author:**

E-mail: editor.ijceo@gmail.com

ABSTRACT

Background: Neurofibromatosis (NF) is one of the most common genetic disorders with variable expression. It is characterized by neuroectodermal tumors arising within multiple organs.

Case Report: We report an interesting case of 14 year old girl who presented with swelling and mild mechanical ptosis of right eye upper lid which was associated with multiple cutaneous abnormalities and fibromatosis of external genitalia. Complete excision of lid mass was done and histopathological examination revealed neurofibromatosis type I.

Conclusions: The clinical manifestations, diagnosis, treatment and complications of neurofibromatosis are discussed.

Key Words: Café-au-lait spot, Lich's nodule, Neurofibromatosis type-I, von Recklinghausens's disease.

INTRODUCTION

Neurofibromatosis type 1 (NF1) or von Recklinghausens's disease is transmitted by autosomal dominant inheritance, affecting 1/ 4,000 to 1/ 3,000 individuals^{1,2}. Its penetrance is almost complete by 5 years of age. Briefly, NF1 exposes a characteristically cutaneous phenotype including benign neurofibromas, which are mixed tumors composed of all cell types found in the peripheral nerves, hyperpigmented macules, termed café-au-lait macules, axillary/inguinal freckling and Lisch's nodules (pigmented hamartomas of the iris)^{3,4}. NF2 on the other hand is mainly restricted to tumors of the central and peripheral nervous system, which rarely accompanied by cutaneous disorders. We intend to report an interesting case of a 14 year old female patient of NF 1 with ocular and cutaneous manifestations.

CASE REPORT

We here report a case of 14 year old girl who presented to our outpatient department with a mass around right eye upper lid leading to mild mechanical ptosis [Figure 1]. Patients also complained of multiple yellowish brown patches of

variable sizes scattered all over the body [figure 2]. She also complained of few nodules around back and around external genitalia [figure 3]. Detailed ocular examination of patient revealed a visual acuity of 6/9 in right eye with a soft, non-tender swelling involving right eye upper lid and giving a typical 'S' shaped contour to right upper lid. On palpation it had a worm like consistency with overlying skin slightly hyperpigmented. On CT scan the mass appeared isodense with the extra ocular muscles without any evidence of bony erosion [figure 4]. On slit lamp examination there was prominent corneal nerves bilaterally with multiple hypopigmented nodules present on surface of iris. Rest of ocular examination showed no abnormality. On systemic examination we found multiple plaque like lesions scattered all over body with largest plaque present over back covering whole lower back and gluteal region. Axillary freckling was also present bilaterally. There was one large nodule present just over the genitalia measuring about 2 x 2 cms. Histopathological examination of the nodule and lid mass revealed neurofibroma [figure 5], immunohistochemistry giving positive staining with S-100 protein. After applying the criterion laid down by consensus

conference of National Institute of Health in Bethesda⁵ for diagnosis of NF 1 we found 4 criteria's to be present in our patient. 1. 6 or more **Café' - au - lait** macules of more than 1.5 cm 2.Freckling in axillary region 3.

Presence of at least 2 neurofibromas
4.atleast 2 Lich's nodules on iris .A diagnosis of NF 1 was confirmed in our patient.

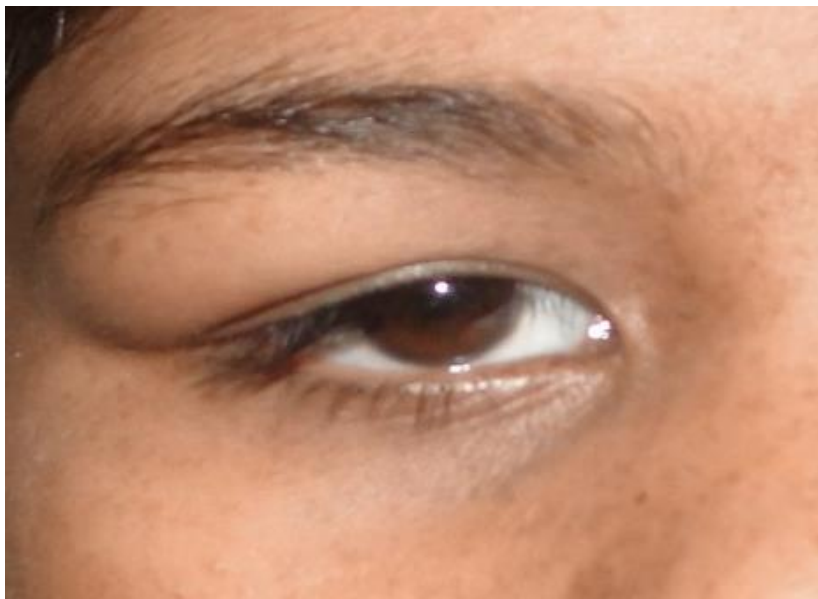

Figure 1: Clinical photograph showing mass around right upper eye lid leading to mild mechanical ptosis

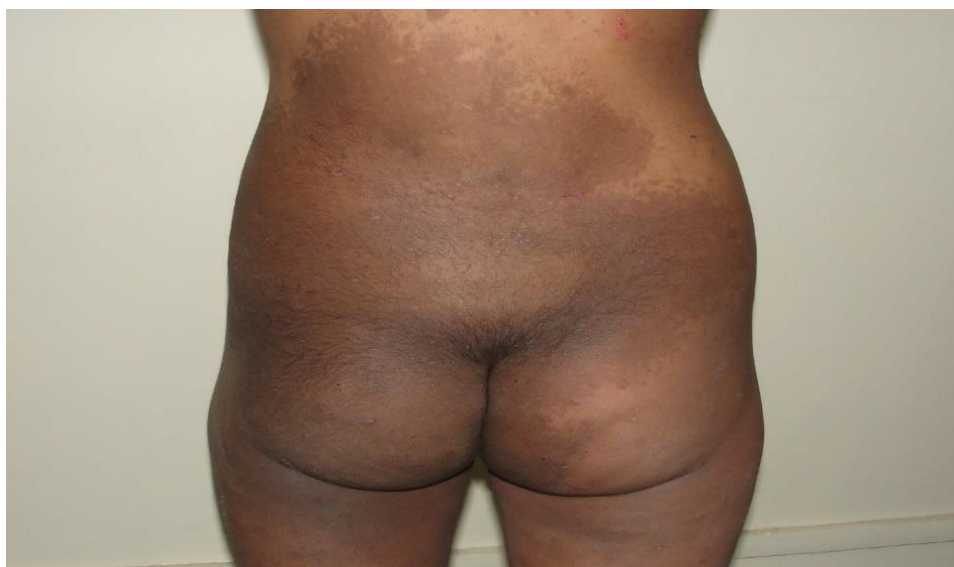

Figure 2: Clinical photograph showing multiple diffuse hyperpigmented macules.

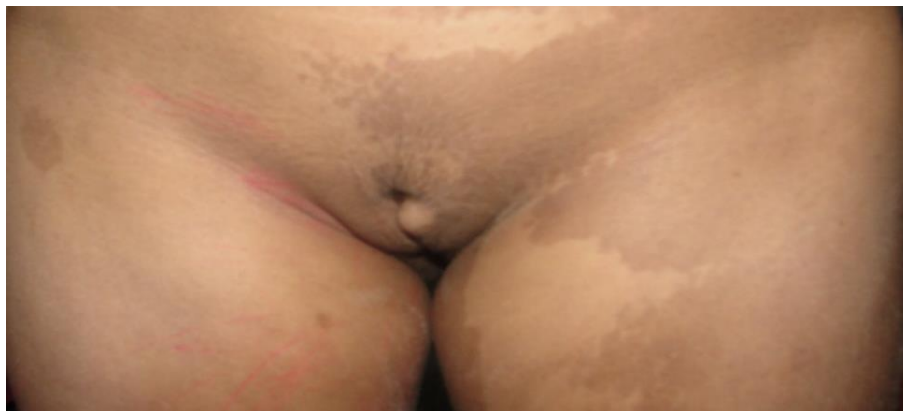

Figure 3: Clinical photograph showing hyperpigmented macule and neurofibroma of external genitalia.

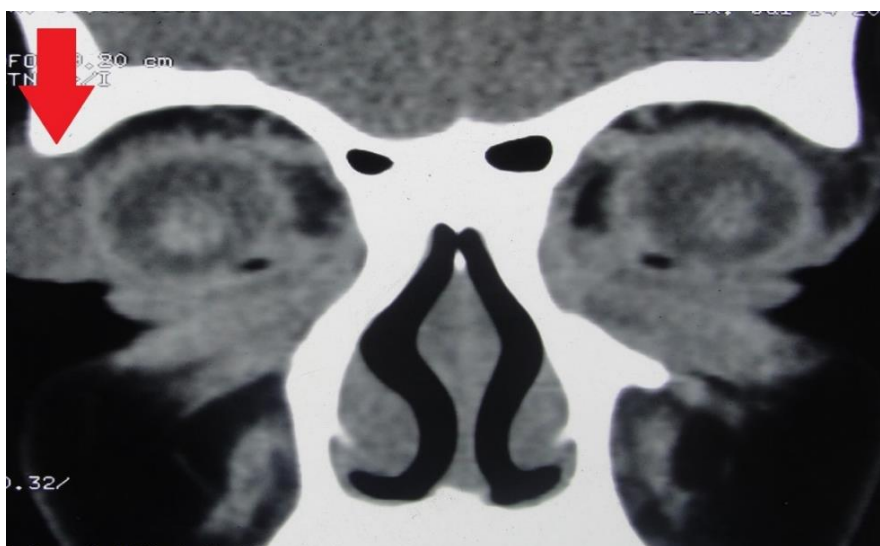


Figure 4. CT scan (coronal view) showing soft tissue mass, isodense with extra ocular muscle without any bony erosions.

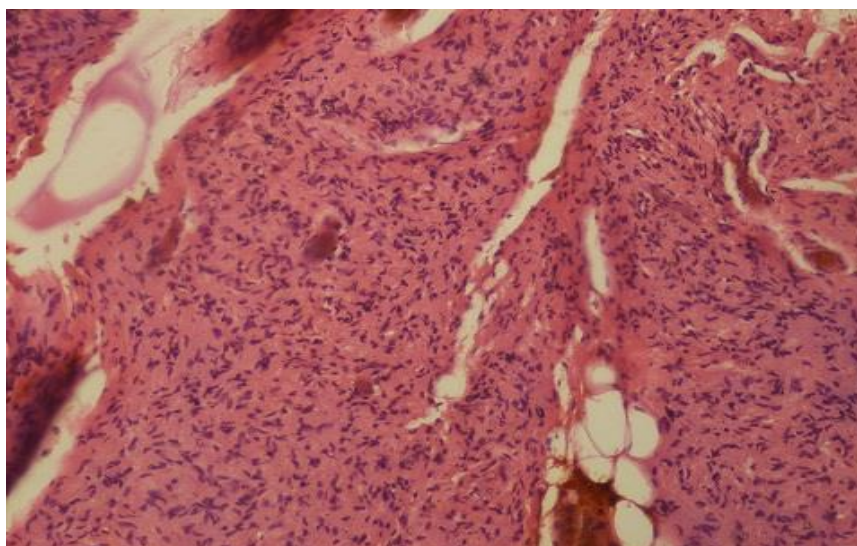


Figure 5. Microphotograph (H and E 40 x) showing neural cells having wavy nuclei.

DISCUSSION

NF 1 is the most common phakomatosis, occurring in 1 of 5000^{1,2}. Skin tumors and “cafe-au-lait” macules are the features of type 1 neurofibromatosis. With the increasing knowledge of neurofibromatosis, more attention is paid to the ocular manifestations of this disease. Through manifestations of neurofibromatosis have been observed for a long time before being described by Robert William Smith in 1849⁶. The classic description is by a German pathologist, Friedrich Daniel von Recklinghausen, who accurately described the diverse findings as a single entity in 1882; thus the condition is often referred to as von Recklinghausen’s disease⁷. There is no single commonly accepted classification. According to the most widely accepted classification, there are four recognized forms of neurofibromatosis:

- von Recklinghausen’s neurofibromatosis or neurofibromatosis type 1 [NF-1] or peripheral neurofibromatosis
- Bilateral acoustic neurofibromatosis or neurofibromatosis type 2 [NF-2] or central neurofibromatosis
- Segmental neurofibromatosis
- Cutaneous neurofibromatosis

The NF 1 gene responsible for the disease is located on the long arm of chromosome 17 at 17q11.2. It is a large (350 kb, 60 exons) tumor suppressor gene that codes for a cytoplasmic protein: neurofibromin. The neurofibromatosis comprise of at least two separate genetic disorders (NF-1 and NF-2) characterized by the formation of tumours surrounding nerves and a variety of other pathological features⁸. The most common type (NF-1) accounting for 90% of cases, is characterized by multiple cafe-au-lait spots and the occurrence of neurofibromas along peripheral nerves. Cutaneous neurofibromas are soft, flesh- or lilac-pink-coloured tumours, sessile or dome-shaped, sometimes pedunculated, and most numerous on the trunk and limbs. Other clinical features include Lisch’s nodules (melanocytic pigmented iris hamartomas) and oral lesions. Possible complications in childhood include the development of an

optic glioma, endocrine disturbances and involvement of the lower urinary tract. The children may also present with learning disabilities^{3,4,9}.

DIAGNOSTIC CRITERIA: According to the National Institute of Health Consensus Development Conference⁵, at least two of the following criteria must be present to make the diagnosis of NF-1:

1. Five or more cafe-au-lait spots larger than 5 mm in diameter in prepubertal patients; six or more cafe-au-lait spots larger than 15 mm in diameter in postpubertal patients
2. Two or more neurofibromas of any type, or one plexiform neurofibroma
3. Axillary or inguinal freckling
4. Optic glioma
5. Two or more Lisch’s nodules
6. A distinctive osseous lesion (pseudoarthrosis of the tibia or sphenoid wing dysplasia)
7. A first-degree relative diagnosed with NF-1 in accordance with the above criteria

Plexiform neurofibromas of the orbit tend to originate from the orbital branches of the trigeminal nerve. They often affect the upper eyelid, causing a characteristic sinusoidal deformity of the lid margin. The tumor is soft and feels like a “bag of worms”; the resultant displacement of the globe or ptosis can result in amblyopia in children^{3,4}. Plexiform neurofibromas of the orbit are associated with congenital absence of the sphenoid or enlargement of the sella turcica. Peripheral neurofibromas are benign tumors consisting predominately of Schwann’s cells and fibroblasts with endothelial, perineural, and mast cells¹⁰. There is evidence that they have a single-cell origin despite multiple cell types within the tumors¹¹. Plexiform neurofibromas occur in about one third of NF-1 cases, most commonly on the trunk and less often on the limbs, head and neck. They are benign and rarely symptomatic, but they can cause significant cosmetic and visual problems if the orbit is involved. Café-au-lait spots are composed of epidermal melanocytes with giant pigment granules (macromelanosomes) within the cytoplasm and are of neural crest origin. They are not pathognomonic of neurofibromatosis,

having been reported in association with several other conditions and in patients not affected by the condition. Hamartomas of the iris (melanocytic nevi) can be seen and are called Lisch's nodules. They are variable in size and have a smooth, dome-shaped configuration. One study found these nodules in 92% of the affected population over the age of 6 years; this may mean that their absence prior to that age does not rule out their later occurrence. Lisch's nodules may also be seen in the trabecular meshwork¹². In a more recent study, the incidence of Lisch's nodules in patients with neurofibromatosis beyond the second decade of life, was 100%.¹³ Lisch's nodules, which can be indicative of Neurofibromatosis 1 when multiple, are rarely seen in Neurofibromatosis 2.¹⁴ Although clinical findings are primarily Neuro-cutaneous in nature, any organ system can be involved. The diagnosis requires six or more cafe-au-lait spots, each larger than 1.5 cm in diameter. Axillary freckling is also highly suggestive of the diagnosis.^{15, 16} Areas of hypopigmentation

or hyperpigmentation can also be seen. Orbital neurofibroma may be three subtypes like plexiform, diffuse and localized. Localized orbital neurofibroma are relatively rare and chances of their recurrence are remote. Authors previously reported recurrence in solitary orbital neurofibroma¹⁷.

CONCLUSION

Patient described in this report is very typical case of NF 1, which presents with a considerable interest because of high generalization of skin lesions and neurofibroma of lid and genitalia. Detailed history and careful clinical examination with a high index of suspicion is very essential to diagnose these cases as all the investigations are only supportive to the initial clinical diagnosis. Management of these cases involves surgical and palliative aspect aiming to cosmetically improve the quality of life and to reduce the associated disabilities.

REFERENCES:

1. Crowe FW, Schull WJ, Neel JV: A clinical, pathological, and genetic study of multiple neurofibromatosis. Springfield, IL, Charles C Thomas, 1956
2. Huson SM, Harper PS, Compston D: Von Recklinghausen neurofibromatosis: a clinical and population study in South-East Wales. *Brain* 111:1355, 1988
3. Smith B, English FP: Classical eyelid border sign of neurofibromatosis. *Br J Ophthalmol* 54:134, 1970
4. Slater C, Hayes M, Saxe N et al: Macromelanosomes in the early diagnosis of neurofibromatosis. *Am J Dermatopathol* 8:284, 1986
5. National Institutes of Health Consensus Development Conference Neurofibromatosis. *Arch Neurol* Chicago 45: 575, 1988
6. Kobrin JL, Blodi FC, Weingeist TA: Ocular and orbital manifestations of neurofibromatosis. *Surv Ophthalmol* 24:45, 1979
7. Von Recklinghausen FD: Ueber die multiple neurofibrome der Haut und ihre Beziehung zu den multiplen Neuomen. Berlin, Hirschwald, 1882
8. Savar A, Cestari DM. Neurofibromatosis type I: genetics and clinical manifestations. *Surv Ophthalmol* 23, 45-51 (2008)
9. Lewis RA, Riccardi VM: von Recklinghausen neurofibromatosis: Incidence of iris hamartomata. *Ophthalmology* 88:348, 1981
10. Riccardi VM, Eichner JE: Neurofibromatosis: phenotype, Natural History and Pathogenesis. Baltimore, Johns Hopkins University Press, 1986
11. Skuse GR, Kosciulek BA, Rowley PT: The neurofibroma in von Recklinghausen neurofibromatosis has a unicellular origin. *Am J Hum Genet* 49:600, 1991
12. Yanoff M, Fine BS: Ocular Pathology, 2nd ed. Philadelphia, Harper & Row, 1982
13. Lubs ME, Bauer MS, Formas ME, Djokic B: Lisch nodules in neurofibromatosis type 1. *N Engl J Med* 324:1264, 1991
14. Lubs ME, Bauer MS, Formas ME, Djokic B: Lisch nodules in neurofibromatosis type 1. *N Engl J Med* 324:1264, 1991
15. Crowe FW: Axillary freckling as a diagnostic aid in neurofibromatosis. *Ann Intern Med* 61:1142, 1964
16. Smith DW: Recognizable Patterns of Human Malformation. Philadelphia, WB Saunders, 1982
17. Maurya RP, Bhushan P, Singh VP, Singh MK, Kumar M: Recurrent solitary orbital neurofibroma : A rare presentation. *World J Surg Med Radiat Oncol* 2012;1:37-41.