

QUANTITATIVE AND QUALITATIVE ASSESSMENT OF DIABETIC RETINOPATHY AFTER LASER TREATMENT

Anukul Dixit^{1,*}, Ishan Yadav², Rajendra P Maurya³, M. K. Singh⁴, S. K. Singh⁵

¹Ex- Resident, ²Senior Resident, ³Assistant professor, ⁴Professor, Dept. of Ophthalmology, ⁵Professor, Dept. of Endocrinology, Institute of Medical Sciences, BHU, Varanasi

***Corresponding Author:**

E-mail: dixit.anukul@gmail.com

ABSTRACT

Aim: To investigate the visual and tomographic changes in patients undergoing pan retinal photocoagulation (PRP) for proliferative diabetic retinopathy (PDR) with or without clinically significant macular edema (CSME).

Methods: This was a prospective, interventional clinical trial including 78 eyes of 78 patients suffering from diabetic retinopathy (DR). All patients were divided into three groups based on the severity of diabetic retinopathy and presence of clinically significant macular edema (CSME). Laser was administered as per the ETDRS standards. Visual acuity (VA), Central macular thickness (CMT), HbA1c and other parameters recorded pre and post laser.

Results: Mean BCVA decreases from 0.24 to 0.33 at one month ($p < 0.001$) and improved to 0.27 ($p > 0.05$) after 4 months in group 1. In group 2 mean BCVA improved from 0.57 to 0.44 at one month ($p < 0.001$) and further improved to 0.39 at four months ($p < 0.001$). In group 3 it deteriorated from 0.63 to 0.67 ($p > 0.05$) but improved to 0.61 at four months ($p > 0.05$). Mean CMT in group one increased from 235μ to 277μ ($p < 0.001$) but decreased to 253μ ($p > 0.05$). From group 2 mean CMT decreased from 379μ to 325μ at one month ($p < 0.001$) and further decreased to 318μ at four months ($p < 0.001$). In group 3 also mean CMT increased from 374μ to 382μ at one month ($p > 0.05$) and then decreased to 373μ ($p > 0.05$).

Conclusion: Laser photocoagulation still remains the gold standard treatment modality in cases of proliferative diabetic retinopathy (PDR) and in treatment of CSME.

Keywords: Pan retinal photocoagulation, proliferative diabetic retinopathy, clinically significant macular edema, Central macular thickness.

INTRODUCTION

According to the latest World Health Organization (WHO) report, India has 31.7 million diabetic subjects, which is expected to increase to 79.4 million by 2030¹. It is estimated that Diabetic Retinopathy (DR) develops in more than 75% of diabetic patients within 15 to 20 years of diagnosis of diabetes¹⁻³. In last two decades since the completion of ETDRS, there have been drastic changes in both diagnosis and treatment for diabetic retinopathy patients. Traditional methods of evaluating macular thickening, including slit-lamp examination and stereo fundus photography, are relatively insensitive to small changes in retinal thickness. Optical coherence tomography (OCT) has emerged as a very sensitive tool for imaging macular edema both quantitatively and qualitatively^{5,6}.

Aim of this study was to investigate the visual and tomographic changes in patients undergoing PRP for PDR with or

without clinically significant macular edema (CSME).

MATERIAL AND METHODS

This prospective study was conducted at Department of Ophthalmology, Sir Sunderlal Hospital, Institute of Medical Sciences from June 2011 to August 2013. A total number of 120 patients were screened and examined out of which 78 eyes of 78 patients were selected for the study. Inclusion criteria were high risk PDR cases with or without CSME and non-proliferative diabetic retinopathy (NPDR) with CSME. Patients with corneal opacity, cataract, uveitis, glaucoma, aphakia, and poor visual acuity due to any other cause were excluded from the study.

All patients were divided into three groups: Group (I) PDR with High risk without CSME: requiring Pan retinal photocoagulation; Group (II) NPDR/PDR without High risk, with CSME: requiring

Grid laser; Group (III) PDR with High risk with CSME: requiring Grid laser followed by PRP. All these patients underwent detailed history and physical examination. Data regarding patient's age, gender, duration of diabetes mellitus, age at onset of diabetes mellitus, presence or absence of hypertension, use of insulin or oral hypoglycaemic agents, presence of other systemic diabetic complications and other general illnesses were collected.

All patients underwent examination for measurement of Blood pressure, glycated haemoglobin (HbA_{1c}), fasting and post

prandial blood sugar level. Ocular examination included assessment of best corrected visual acuity (BCVA) using a Snellen Visual Acuity chart which was converted to logarithm of minimum angle or resolution (LogMAR) unit, slit-lamp biomicroscopy, applanation tonometry, indirect ophthalmoscopy. Fundus fluorescein angiography (FF450) and OCT (Cirrus HD OCT) were carried out for all patients before and after PRP [Figure 1]. OCT and BCVA was done before and one month, and four months after PRP.

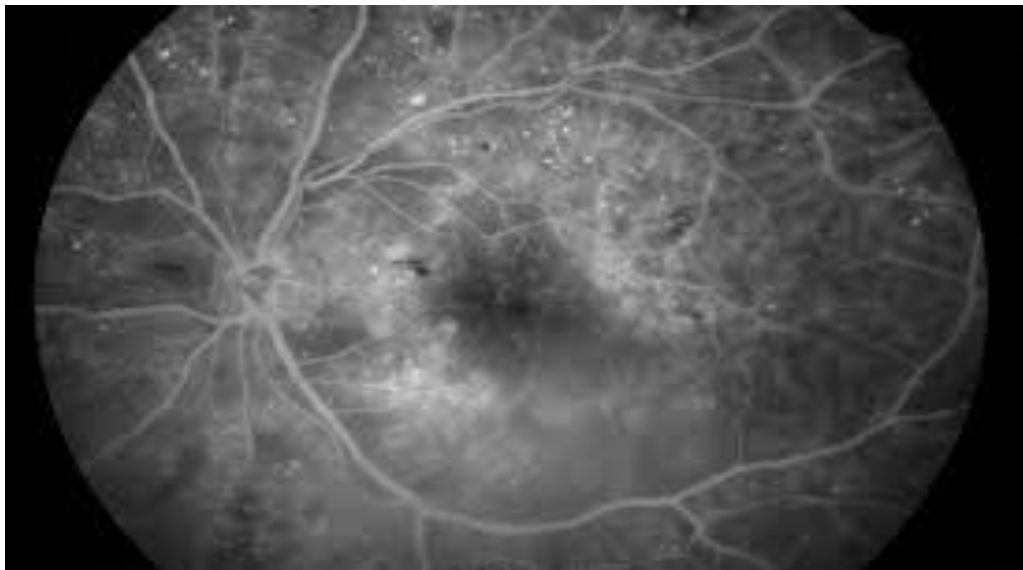


Fig. 1: FFA showing capillary leakage and multiple micro aneurysms around posterior pole.

For quantitative estimation of central macular thickness, a macular cube scan was done using Cirrus HD OCT. A HD 5-line raster scan was done to study the morphological characteristics of macular edema and macular edema was divided into diffuse thickening (DT), cystoid macular edema (CME), and sub retinal fluid (SRF).

All patients underwent PRP and grid photocoagulation using green laser and PRP and Grid laser lenses under topical anaesthesia (0.5% proparacaine), according to the ETDRS recommendations. PRP was done with standard parameters at a one-week interval between each sitting. In group III patients PRP was done after one week of Grid laser.

The data were analyzed using SPSS version 16.0. One way ANOVA test was used

to compare pre and post visual acuity and central foveal thickness while Pearson coefficient test was used to find correlation between HbA_{1c} and post laser visual acuity and central foveal thickness. P-value <0.5 was considered as statistically significant.

RESULT

Mean age group of patients was 54yrs in group 1, in group 2 it was 54yrs and in group 3 it was 53yrs. Mean duration of diabetes was 11 yrs in all the groups. Among 78 patients selected for the study 44 (56%) patients had PDR, out of which 21 also had CSME. There were 55 (70%) patients with CSME with 21 of them having PDR. There were 21 patients in group I, 34 patients in group II and group III had 21 patients. Among group I, seventeen patients had no maculopathy while among group II and III

patients all had some maculopathy on OCT. Patients with DT and sub retinal fluid (SRF) or Cystoid macular edema (CME) were classified as SRF and CME respectively[

Figure 2 and Figure 3]. Diffuse thickening (DT) was present in 34 (43%) patients, CME in 18 patients and SRF in 8 patients. 17 patients had normal macula.[Figure 4]

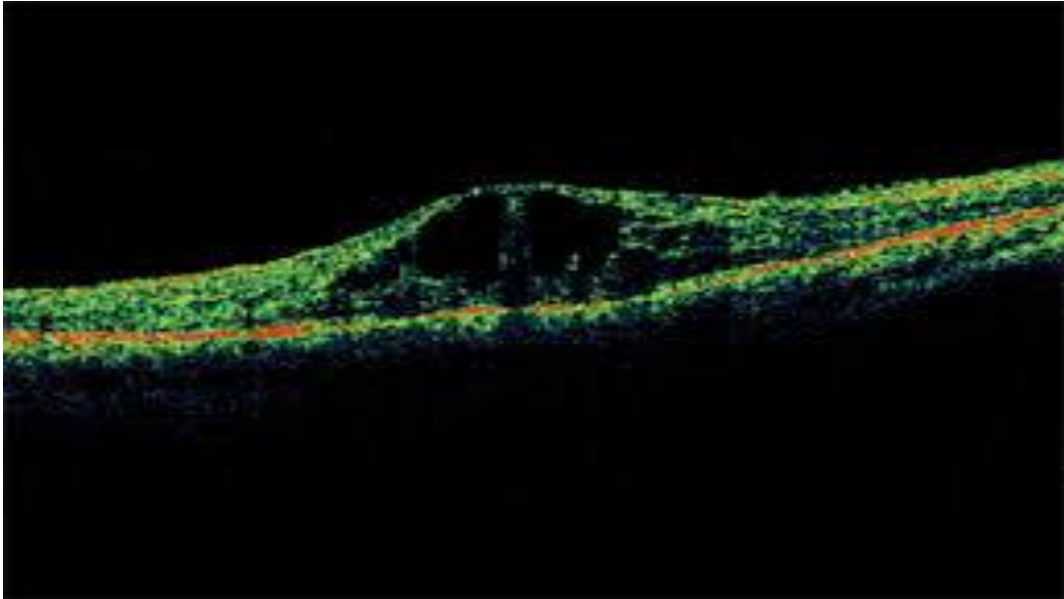


Fig. 2: OCT showing diabetic cystoid macular edema

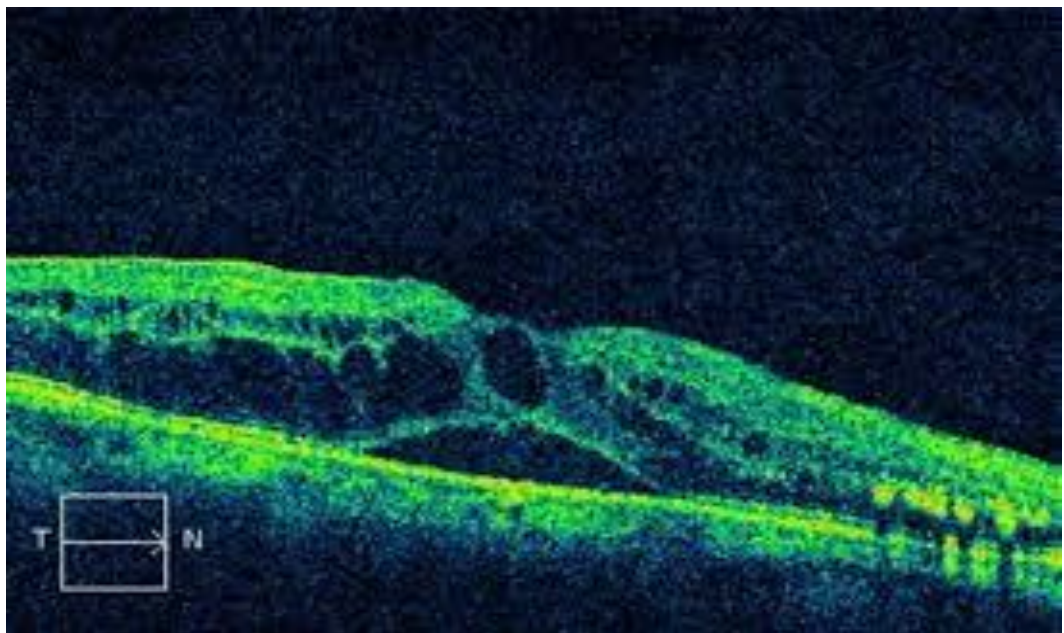
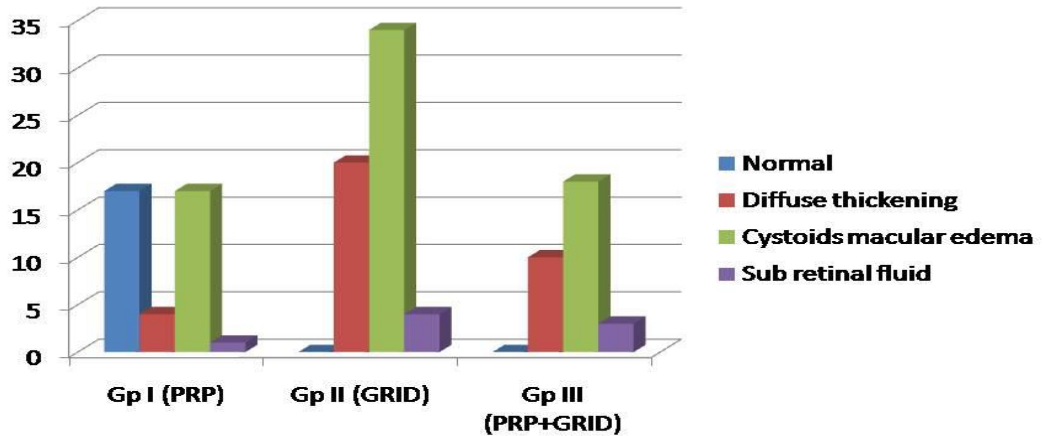


Fig. 3: OCT showing diabetic macular edema with sub retinal fluid.

Type of maculopathy

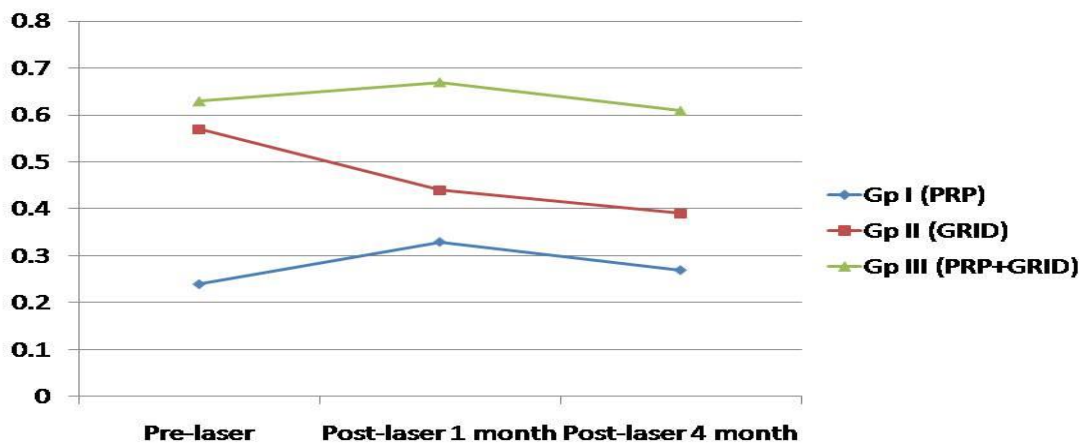


Graph: 1

Among group 1 patients, there was improvement in BCVA in 1 patient, stable in 16, while 6 had worsened vision. Group 2 showed improvement in 30 patients with 3 stable and 1 worsening. From group 3, five patients improved while 13 had stable vision. Mean BCVA decreases from 0.24 to 0.33 at one month ($p < 0.001$) and improved

to 0.27 ($p > 0.05$) after 4 months in group 1. In group 2 mean BCVA improved from 0.57 to 0.44 at one month ($p < 0.001$) and further improved to 0.39 at four months ($p < 0.001$). In group 3 it deteriorated from 0.63 to 0.67 ($p > 0.05$) but improved to 0.61 at four months ($p > 0.05$). [Figure]

Mean BCVA Pre and Post laser

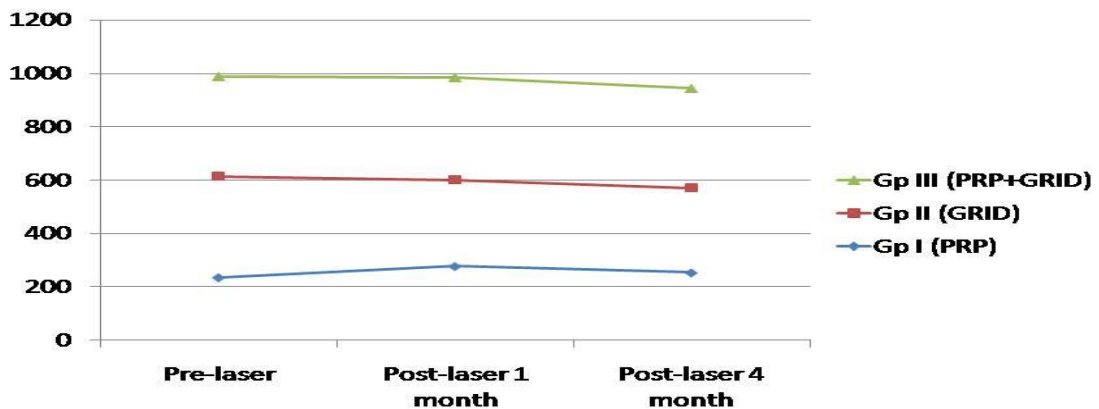


Graph: 2

CMT in group 1 increased in 17 cases while decreased in only 6. In group 2 it decreased in all 34 cases while in group 3 16 showed increase and 5 decrease in CMT. Mean CMT in group one increased from 235μ to 277μ ($p<0.001$) but decreased to 253μ ($p>0.05$). From group 2 mean CMT

decreased from 379μ to 325μ at one month ($p<0.001$) and further decreased to 318μ at four months ($p<0.001$). In group 3 also mean CMT increased from 374μ to 382μ at one month ($p>0.05$) and then decreased to 373μ ($p>0.05$). [Figure 6]

Mean CMT Pre and Post-laser



Graph: 3

DISCUSSION

The mean age of patients in our study was 53 years. Macula was normal in 17 (80%) cases of group 1 while 4 had DT. In group 2, DT was present in 20 (59%) cases, CME in 9 (26%), and SRF in 4 (12%) cases. Group 3 had DT in 10 cases, eight with CME and three with SRF. *ManojSoman et al.* (2012) found mainly normal (54 of 76 eyes, 71.7%) macula on OCT^{1,2}. The most common abnormality seen was spongy edema in 14 eyes, (18.4%), followed by epiretinal membrane in four eyes (5.3%), and cystoid macular edema, subretinal fluid. Among patients with diffuse thickening (DT), there was improvement or stabilization of BCVA in 29 patients while worsening in only 2 patients. In cases with Cystoid Macular Edema (CME) there was improvement/stabilization in 13 patients and worsening in 2 patients, while in

Subretinal Fluid (SRF) cases 4 had improvement/stabilization while 3 had worsening. In context to CMT also DT showed better response with decrease in edema in 21 cases and increase in 10 cases. With CME there was increase and decrease in 7 patients each. In SRF cases there was decrease in 4 patients and increase in 2 patients.

Mean BCVA in group 1 was 0.24 ± 0.22 ranging from 0 to 0.48 before laser. It improved to 0.33 ± 0.28 (p -value <0.001) ranging 0.18 to 0.78 at one month and 0.27 ± 0.30 (p -value >0.05) ranging 0.18 to 0.78. These findings are similar to the results of *Lee SB et al.* (2010)⁴. *Mohan Rema et al.* (2005) and *Richard S Kaiser et al* (2000) found improvement in visual acuity after one year follow up of PRP patients^{7,8}. [Figure 7]

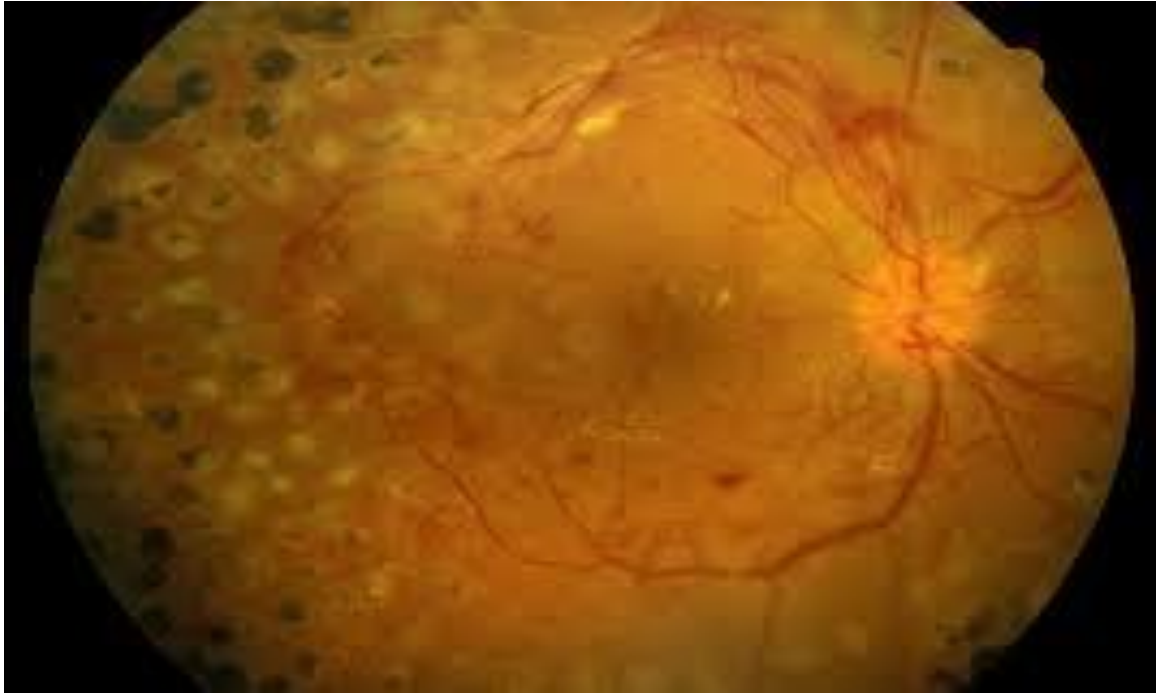

Fig. 4: Showing laser spots after PRP.

In group 2, mean BCVA at presentation was 0.57 ± 0.30 ranging 0.30 to 1.00 which improved to 0.44 ± 0.30 (p-value < 0.001) ranging 0.18 to 0.78 at one month and 0.39 ± 0.28 (p-value < 0.001) ranging 0.18 to 0.78 at four months post laser.

Mean BCVA decreased from 0.63 ± 0.26 ranging 0.48 to 1.00 at pre-laser to 0.67 ± 0.30 (p-value > 0.05) ranging 0.48 to 1.00 at one month and 0.61 ± 0.34 (p-value > 0.05) ranging 0.30 to 1.00 at four months of laser in group 3. In *Manoj Soman et al.* (2012) study mean preoperative vision was 0.15 ± 0.12 log units, which worsened significantly to 0.31 ± 0.20 log units ($P = 0.001$) at one week, to 0.29 ± 0.23 log units at one month ($P = 0.0001$), and although worsened at 3 months to 0.25 ± 0.37 log units, this was not statistically significant ($P = 0.06$)^{1,2}.

Group 1 had a mean CMT of $235 \pm 54 \mu$ ranging 202 to 289μ at presentation. This increased to $277 \pm 96 \mu$ (p-value < 0.001) ranging 223 to 423μ at one month and $253 \pm 86 \mu$ (p-value < 0.05) ranging 201 to 402μ at four months of PRP. *Otacillo de Olivera Maia Junior et al.* (2008) and *Shimura M et al* 2003 also found similar results and reported significant decrease in visual acuity

after PRP, and a greater mean of macular thickness measurements on OCT^{9,10}. *M M K Muqit et al* reported that conventional argon laser panretinal photocoagulation may increase the retinal nerve fibre layer thickness in the short term, presumably related to laser-induced axonal injury¹¹.

Perwez Khan et al. reported our study concluded that panretinal photocoagulation leads to decreased visual acuity and contrast sensitivity¹².

In the group 2, mean CMT was $379 \pm 90 \mu$ ranging 307 to 514, this decreased to $325 \pm 90 \mu$ (p-value < 0.001) which ranged 240 to 459μ at one month and $318 \pm 88 \mu$ (p-value < 0.001) ranging 235 to 447μ a four months of grid laser. Mean CMT at presentation in group 3 was $374 \pm 90 \mu$ ranging 317 to 509μ , which increased to $382 \pm 102 \mu$ ranging 298 to 510μ (p-value > 0.05) at one month and $373 \pm 102 \mu$ (p-value > 0.05) ranging 291 to 512μ at four months. In *Manoj Soman et al.* (2012) study mean preoperative central foveal thickness was $222.05 \pm 59.11 \mu$, increasing to $266.84 \pm 84.67 \mu$ at one week, to $264.05 \pm 102.56 \mu$ at one month, and to $256 \pm 101.38 \mu$ at 3 months' follow-up after PRP.

In group 1 there was improvement in 1 case, stable in 16 cases and worsening of

BCVA in 6 cases. Among those 6 cases 4 developed macular edema while 2 developed epiretinal membrane. Among group 2 patients, there was improvement in 30 cases, 3 cases stabilized while 1 worsened due to development of macular ischemia. In group 3 patients, 5 had improved BCVA, 13 stable while 3 had worsened due to development of epiretinal membrane. Shrestha S. et al. (2007) reported 52.50% visual acuity improvement, 35% static and 12.5% deterioration in best corrected visual acuity after laser treatment in diabetic retinopathy, Kaushal et al (2002) reported In a routine care environment laser treatment of diabetic retinopathy can maintain very good vision^{13,14}. Jonathan G F Dowler (1996) reported that A modest improvement (one line on the Snellen visual acuity chart) was seen in 40% of treated and 20% of untreated eyes¹⁵. To summarize we can state that for clinically significant macular edema the Early Treatment of Diabetic Retinopathy Study could show that immediate focal laser photocoagulation reduces the risk of moderate visual loss by at least 50% which is in correspondence to other researches¹⁶⁻²⁰. But laser photocoagulation can also lead to moderate visual loss, some diminished visual field, reduced color vision, and reduced contrast sensitivity in few cases²¹⁻²³.

Limitation of this study was small number of data and need for longer follow up of subjects. However, other studies with more cases and long follow-up should substantiate the evidence of morphological and functional changes, found in these patients with DR and CSME after PRP and grid laser.

CONCLUSION

Diabetic retinopathy is a major challenge in ophthalmology with increasing incidence due to changes in life style and life expectancy. With discovery of better medical treatment for diabetic retinopathy like intravitreal steroids and particularly antiVEGFs there is growing shift of treatment from laser treatment to medical treatments. But still there are limitations with these treatments, specially, in proliferative changes where laser photocoagulation remains the only treatment option. In cases of CSME retinal photocoagulation remains the gold standard.

CONFLICT OF INTEREST: NONE

REFERENCE:

1. Soman M, Ganekal S, Nair U, Nair K. Effect of panretinal photocoagulation on macular morphology and thickness in eyes with proliferative diabetic retinopathy without clinically significant macular edema. *ClinOphthalmol.* 2012;6:2013-7.
2. Ga Eun Cho, Hee Yun Cho, Yun Taek Kim Change in subfoveal choroidal thickness after argon laser panretinal photocoagulation. *Int J Ophthalmol.* 2013; 6(4): 505-509.
3. L.P. Aiello, T.W. Gardner, G.L. King, G. Blankenship, J.D. Cavallerano, F.L.I.I.I. Ferris, R. Klein, Diabetic retinopathy. Technical review. *Diabetes Care* 21, 143-156 (1998)
4. B.E. Klein, R. Klein, K.E. Lee, Components of the metabolic syndrome and risk of cardiovascular disease and diabetes in beaver dam. *Diabetes Care* 25(10), 1790-1794 (2002)
5. Lee SB, Yun YJ, Kim SH, Kim JY. Changes in macular thickness after panretinal photocoagulation in patients with severe diabetic retinopathy and no macular edema. *Retina.* 2010 May;30(5):756-60.
6. S. Yamamoto, T. Yamamoto, M. Hayashi, S. Takeuchi, Morphological and functional analyses of diabetic macular edema by optical coherence tomography and multifocal electroretinograms. *Graefes Arch. Clin. Exp. Ophthalmol.* 239(2), 96-101 (2001)
7. Rema M, Sujatha P, Pradeepa R. Visual outcomes of pan-retinal photocoagulation in diabetic retinopathy at one-year follow-up and associated risk factors. *Indian J Ophthalmol.* 2005 Jun;53(2):93-9.
8. Richard S Kaiser, Maureen G Maguire, Juan E Grunwald, Douglas Lieb, MBinoy Jani, One-year outcomes of panretinal photocoagulation in proliferative diabetic retinopathy. *Am J Ophthalmol.* February 2000 Volume 129, Issue 2, Pages 178-185
9. Maia OO Jr, Takahashi WY, Nakashima Y. Visual acuity and macular thickness in diabetic retinopathy treated with panphotocoagulation. *Arq Bras Oftalmol.* 2008 May-Jun;71(3):394-9
10. Shimura M, Yasuda K, Nakazawa T, Kano T, Ohta S, Tamai M. Quantifying alterations of macular thickness before and after panretinal photocoagulation in patients with severe diabetic retinopathy and good vision. *Ophthalmology.* 2003 Dec;110(12):2386-94.
11. M M K Muqit, L Wakely, P E Stanga, D B Henson, F D Ghanchi. Effects of conventional argon panretinal laser photocoagulation on retinal nerve fibre layer and driving visual fields in diabetic retinopathy. *Eye* (2010) 24, 1136-1142.

12. Dr. Perwez Khan, Dr. Satya Prakash Tiwari, Dr. Saumya Pande. Effect of Panretinal Photocoagulation on Visual Field and Macular Function in Diabetic Retinopathy. *Sch. J. App. Med. Sci.*, 2014; 2(5F):1946-1950.
13. Shrestha S, Karki DB, Byanju R, Malla OK, Shrestha SM, Pradhananga CL. Visual outcome of laser treatment in diabetic retinopathy. *Kathmandu Univ Med J (KUMJ)*. 2007 Jan-Mar;5(1):72-80.
14. K. Kaushal, J.P. New, D. McDowell, L.B. Young, R. Taylor, R.J. Young. Visual outcome after laser treatment for diabetic retinopathy. *Practical Diabetes Int* 2002; 19(1); 6-9.
15. Jonathan G F Dowler. Laser management of diabetic retinopathy. *J R Soc Med*. 2003 Jun; 96(6): 277-279.
16. Neubauer AS, Ulbig MW. Laser treatment in diabetic retinopathy. *Ophthalmologica*. 2007;221(2):95-102.
17. Praidou A, Androudi S, Brazitikos P, Karakiulakis G, Papakonstantinou E, Tsinopoulos I, Dimitrakos S. Diabetic retinopathy treated with laser photocoagulation and the indirect effect on glycaemic control. *J Diabetes Res*. 2014;2014:158251.
18. Cho GE1, Cho HY, Kim YT . Change in subfoveal choroidal thickness after argon laser panretinal photocoagulation. *Int J Ophthalmol*. 2013 Aug 18;6(4):505-9.
19. Shimura M, Yasuda K, Nakazawa T, Tamai M. Visual dysfunction after panretinal photocoagulation in patients with severe diabetic retinopathy and good vision. *Am J Ophthalmol*. 2005 Jul;140(1):8-15.
20. Sher A, Jones BW, Huie P, Paulus YM, Lavinsky D, Leung LS, Nomoto H, Beier C, Marc RE, Palanker D. Restoration of retinal structure and function after selective photocoagulation. *J Neurosci*. 2013 Apr 17;33(16):6800-8.
21. Browning DJ. Visual dysfunction after panretinal photocoagulation in patients with severe diabetic retinopathy and good vision. *Am J Ophthalmol*. 2005 Jul;140(1):127-8.
22. Fong DS, Girach A, Boney A. Visual side effects of successful scatter laser photocoagulation surgery for proliferative diabetic retinopathy: a literature review. *Retina*. 2007 Sep;27(7):816-24.
23. Ferris F. Early photocoagulation in patients with either type I or type II diabetes. *Trans Am Ophthalmol Soc*. 1996;94:505-37.