

Factors influencing healing of fungal keratitis under treatment: A clinical study

Ramyash Singh Yadav^{1,*}, Brij Mohan Rao², Praveen Kumar³, Akash Srivastva⁴

^{1,2}Associate Professor, ⁴Junior Resident, Dept. of Ophthalmology, BRD Medical College, Gorakhpur, ³Chief Eye Surgeon, Ahsan Eye Hospital, Amroha, Uttar Pradesh

***Corresponding Author:**

Email: ramyashyadav93.ry@gmail.com

Abstract

Purpose: To study the local and general factors influencing healing of fungal keratitis.

To evaluate the effects of various antimycotic treatment regimens of fungal keratitis.

Method: The patients were taken up from those attending the out-patient department of ophthalmology of Nehru hospital attached to B.R.D Medical College Gorakhpur from June 2006 to October 2007. All cases of corneal ulcer with clinical features of fungal keratitis and cases of corneal ulcer with positive 10% potassium hydroxide mount^{1,2} were selected, detailed history taken and examination done under (a) general examination, (b) systemic examination and detailed ocular examination along with blood investigations and 10% potassium hydroxide mount^{1,2} preparation.

Treatment evaluation and follow up was done regularly for the period of one month, progression and treatment response noted and parameters were recorded. The ulcer was taken:

Healed: If the epithelial defect had healed with negative fluorescein staining and there was no progressive stromal infiltration.

Delayed healing: If the size of ulcer decreased but not fully healed and still require further active treatment and

Failed: If the size of ulcer remained same or increased or ulcer got perforated requiring active surgical intervention.

Result: 47 pts were included in study, 5 patients did not turn up. 18 patients (42.86%) leave the study with successful healing of corneal ulcer, 9 patients (21.43%) required further treatment due to delayed healing response and treatment failure occurred in 15 patients (35.71%) requiring active surgical treatment in form of conjunctival hooding, Amniotic membrane graft, evisceration etc.

Conclusion: From the observation of this study it can be concluded that fungal keratitis is a suppurative, ulcerative disease of cornea, with a poor visual outcome even with the best efforts due to inability of highly sensitive and specific tools. Disease is more common in patients with reduced immunity, trauma with vegetative matter, low socio-economic status and injudicious use of steroids. There is also big lack of specific and effective fungicidal drugs. All available anti-fungal drugs are very slow acting and prevent the growth of fungus only, without killing it.

At present the most effective drug is topical 5% Natamycin, which is also fungi-static and slow acting.

Keywords: Fungal keratitis, Healed corneal ulcer, Poor visual outcome, Natamycine

Access this article online

Website:

www.innovativepublication.com

DOI:

10.5958/2395-1451.2016.00059.7

Introduction

Cornea is the front window through which we can see the beautiful world, fungal keratitis³ is a serious suppurative disease⁴, which may result in damage the clear cornea. Fungal keratitis heals well if treated early and aggressively after diagnosis. Diagnosis of fungal keratitis remain a challenge to ophthalmologist due to variety of presentation of patients. If a prompt, aggressive and early treatment is not started, disease turn indolent resulting in sloughing of cornea, serious loss of vision with possible perforation and finally total loss of eye. Even after early and aggressive treatment of disease, it respond very slowly to treatment, thus prolonging the course of the disease. As the patients are usually poor and daily worker⁵, their earning stops, leading to the stoppage of treatment also.

Fungi are classified by mycologists into various sub-groups depending on their complex taxonomic features but they can be simply classified into filamentous fungi, Yeasts and a dimorphic group which having both filamentous and yeast phase.

Filamentous Fungi are multicellular organisms that produce distinctive long branching hyphae that form a tangled mass (mycelium). The hyphae may be septate (divided by cross walls into definite cells, each containing one or more nuclei) or non-septate (long tubes containing protoplasm with numerous nuclei scattered throughout).

Yeast consist primarily Candida species. These are unicellular oval structures that reproduce by budding and resemble hyphae known as pseudohyphae. Pseudohyphal form is probably the most invasive and virulent stage.⁶

Method and Patient Selection

The patients were taken up from those attending the out-patient department of ophthalmology of Nehru Hospital attached to B.R.D Medical College Gorakhpur from June 2006 to October 2007. All cases of corneal ulcer with clinical features of fungal keratitis

and cases of ulcer with positive 10% potassium hydroxide mount^{1,2} were selected. Detailed history taken and examination done under heads of:

- a. **General examination:** pulse, blood pressure, height, weight and body surface area.
- b. **Systemic examination:** central nervous system, cardiovascular system, gastro intestinal system and locomotory system.
- c. **Detailed ocular examination:**
 1. **Lids:** edema, redness, ectropion, entropion, trichiasis, tylosis, and lagophthalmos.
 2. **Palpebral fissure:** normal/narrow/wide.
 3. **Conjunctiva:** congestion, chemosis, lusture, scar, growth, pigmentation, degenerative condition and foreign body.
 4. **Cornea:** surface, transparency, texture, sensation, vascularisation, opacity, pigmentation, endothelium.
 5. **Details of corneal ulcer:** location, size, shape, depth, edge, base, presence of slough, immune ring, satellite lesions.
 6. **Anterior chamber:** Depth and contents(hypopion).
 7. **Lacrimal sac:** by regurgitation test and syringing.
 8. **Visual acuity:** by snellen's chart.
 9. **OP:** by digital tonometry.

d. **Investigations**

1. Haemoglobin, total leucocyte count, differential leucocyte count, erythrocyte sedimentation rate.
2. Blood sugar level-random and post prandial.
3. Total serum proteins and albumin globulin ratio.
4. Conjunctival smear- gram's staining.
5. Corneal smear for gram's staining and 10% potassium hydroxide^{1,2} mount.

- e. **Treatment, Evaluation and Follow Up:** After diagnosis and informed consent about study patients were treated with 5% Natamycin, 0.3% fluconazole or itraconazole^{10,11,12} eye drops on hourly basis between 7AM till patient went to sleep at night. Patients having very large corneal ulcer (>49 mm sq) also given oral fluconazole¹⁰ 150mg or terbinafine 250 mg once a day. Atropine sulphate eye ointment was prescribed twice daily.

Along with this symptomatic and supportive treatment in form of anti-inflammatory drugs to relieve pain, vitamin C, vitamin A and protein supplementation to improve the general health and immune system of the patients.

Patients were examined regularly on slit lamp, ulcer was scraped to remove the necrotic material for one month; progression and treatment response noted and parameters were recorded. The ulcer was taken as:

1. **Healed-**if the epithelial defect had healed with negative fluorescein staining¹³ and there was no progressive stromal infiltration.

2. **Delayed healing-**if the size of ulcer had decreased but not fully healed and still require further active treatment.
3. **Failed-treatment** was considered failed if the size of the ulcer remained same or increased or ulcer got perforated requiring active surgical intervention.

Observation

The present study included 47 patients of 10% potassium hydroxide mount positive fungal corneal ulcers but five patients did not turn up for follow up. Thus the observations of the present study are based on findings of 42 patients of fungal corneal ulcer, who underwent evaluation and anti-fungal treatment. The detailed observations are tabulated below:

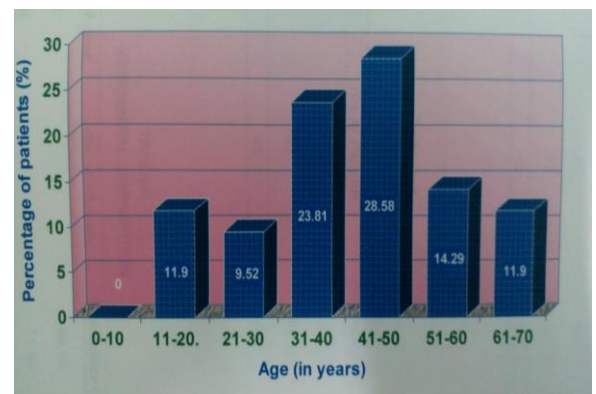


Fig. 1: Age distribution

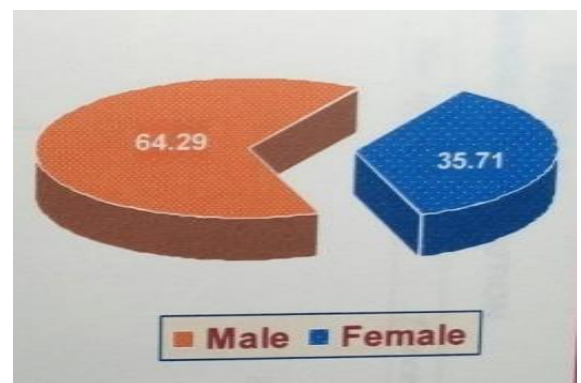


Fig. 2: Sex distribution

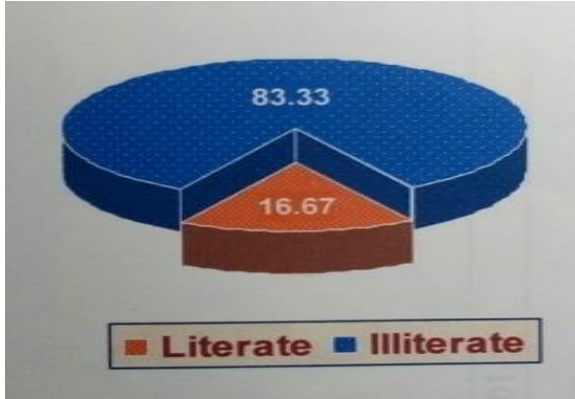


Fig. 3: Literacy distribution

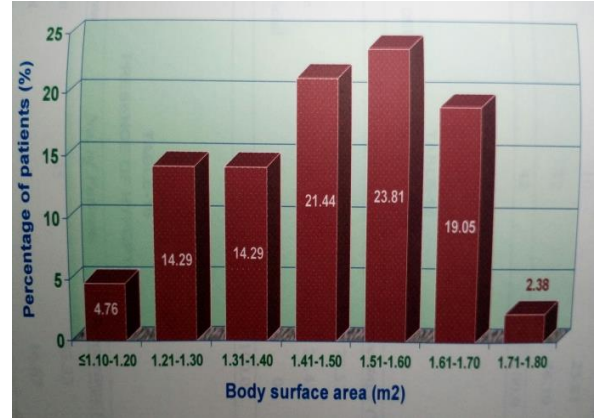


Fig. 6: Body surface area of the patients




Fig. 4: Residential distribution

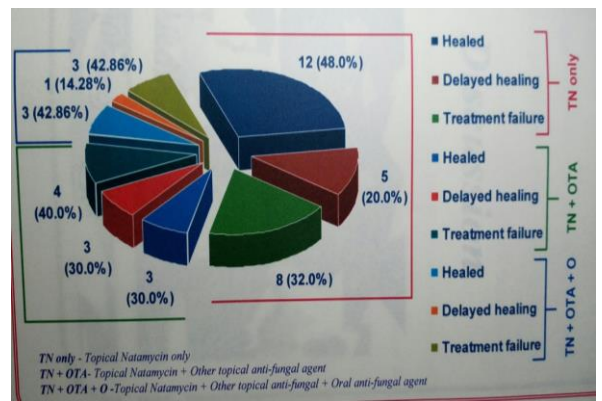


Fig. 7: Treatment given & response

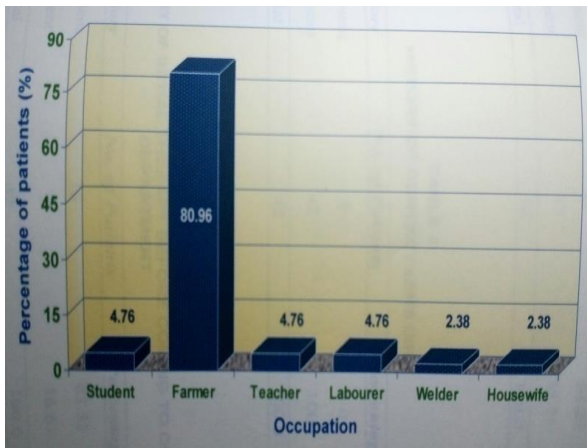


Fig. 5: Occupational distribution

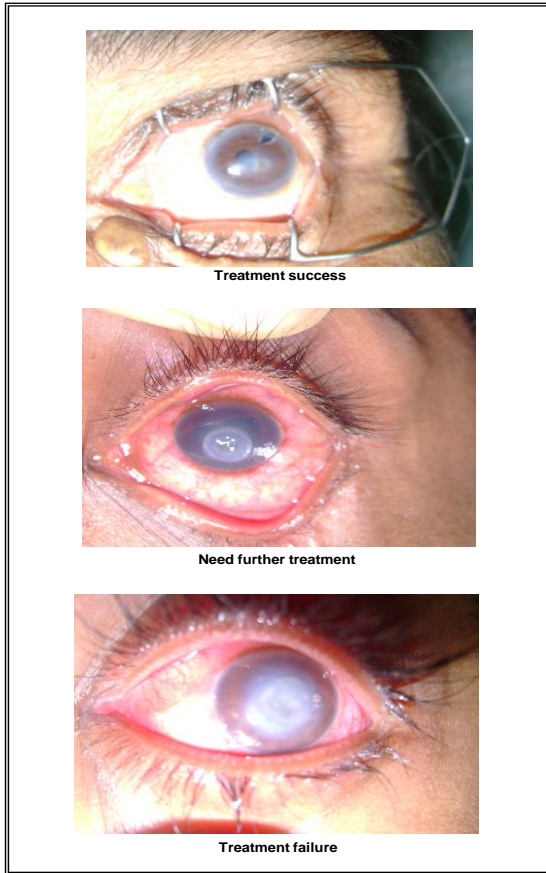


Table 1: Treatment success, treatment failure and delayed healing in subgroups of patients

S. No.	Characteristic	No. of Patients	Healed(18)	Delayed Healing (9)	Treatment Failure (15)	Degree of freedom	Chi square test	probability	
1.	Age (Yrs.)	≤ 40	19	9 (47.36%)	05 (26.32%)	5 (26.32%)	-	-	-
		> 40	23	9 (39.15%)	04 (17.38%)	10 (43.47%)	-	-	-
2.	Sex	Male	27	12 (44.44%)	6 (22.22%)	9 (33.34%)	-	-	-
		Female	15	6 (40.0%)	3 (20.0%)	6 (40.0%)	-	-	-
3.	Duration of Symptoms (days)	≤ 7	15	7 (46.66%)	4 (26.67%)	4 (26.67%)	2	0.913	0.634
		> 7	27	11 (40.76)	5 (18.52%)	11 (40.74%)	-	-	-
4.	Literacy of patient	Literate	7	6 (85.71%)	0 (0%)	1 (14.29%)	2	5.14	0.076
		Illiterate	35	15 (42.86%)	15 (42.86%)	5 (14.28%)	-	-	-
5.	Occupation	Farmers	34	12 (35.29%)	10 (29.42%)	12 (35.29%)	2	2.32	0.314
		Others	8	5 (62.50%)	2 (25.0%)	1 (12.50%)	-	-	-
6.	Living Area	Rural	37	15 (40.54%)	8 (21.62%)	14 (37.84%)	2	0.787	0.675
		Urban	5	3 (60.0%)	1 (20.0%)	1 (20.0%)	-	-	-
7.	Height (cm.)	≤ 150	11	5 (45.45%)	1 (09.10%)	5 (45.45%)	2	1.48	0.478
		> 150	31	13 (41.94%)	8 (25.80%)	10 (32.26%)	-	-	-
8.	Weight (Kgs.)	≤ 50	21	06 (28.57%)	02 (09.53%)	13 (61.90%)	2	12.8	0.002
		> 50	21	12 (57.14%)	07 (33.33%)	02 (09.53%)	-	-	-
9.	Body surface area (m ²)	≤150	23	06 (26.09%)	03 (13.04%)	14 (60.87%)	2	14.00	0.001
		>150	19	12 (63.16%)	06 (31.58%)	01 (05.26%)	-	-	-
10.	H/O trauma with vegetative matter	Present	27	8 (29.63%)	8 (29.63%)	11 (40.74%)	2	5.99	0.50
		Absent	15	10 (66.66%)	1 (06.68%)	4 (26.66%)	-	-	-
11.	H/O Contact lens use	Present	0	0 (0%)	0 (0%)	0 (0%)	-	-	-
		Absent	42	18 (42.86%)	9 (21.43%)	15 (35.71%)	-	-	-
12.	H/O initial therapy	Present	35	13 (37.14%)	7 (20.0%)	15 (42.86%)	2	4.80	0.091
		Absent	7	05 (71.43%)	2 (28.57%)	0 (0%)	-	-	-
13.	H/O initial therapy with corticosteroid	Present	9	01 (11.11%)	2 (22.22%)	6 (66.67%)	2	5.77	0.056
		Absent	33	17 (51.52%)	7 (21.21%)	9 (27.27%)	-	-	-
14.	Ulcer Size (mm ²)	≤ 10	6	06 (100.0%)	0 (0%)	0 (0%)	2	9.33	0.009
		> 10	36	12 (33.33%)	9 (25.0%)	15 (41.67%)	-	-	-
15.	Depth of Infiltration of Cornea	Superficial	0	0 (0%)	0 (0%)	0 (0%)	2	3.46	0.177
		Middle	9	06 (66.67%)	2 (22.22%)	01 (11.11%)	-	-	-
		Deep	33	12 (36.37%)	7 (21.21%)	14 (42.42%)	-	-	-
16.	Hypopion (mm)	≤ 2	32	17 (53.13%)	5 (15.63%)	10 (31.24%)	2	6.17	0.046
		> 2	10	1 (10.0%)	4 (40.0%)	5 (50.0%)	-	-	-

17.	Haemoglobin (gm %)	≤ 10	14	4 (28.57%)	7 (50.0%)	3 (21.43%)	2	10.2	0.006
		> 10	28	14 (50.0%)	2 (07.14%)	12 (42.86%)			
18.	Random Blood Sugar (mg %)	≤ 200	41	18 (43.90%)	9 (21.95%)	14 (35.15%)	2	1.84	0.398
		> 200	1	0 (0%)	0 (0)	1 (100.0%)			
19.	Total Serum Protein (gm %)	≤ 7	28	7 (25.0%)	6 (21.43%)	15 (53.57%)	2	13.8	0.001
		> 7	14	11 (78.57%)	3 (21.43%)	0 (0%)			
20.	Treatment Given	A.TN only	25	12 (48.0%)	5 (20.0%)	8 (32.0%)	4	1.32	0.858
		B.TN + OTA	10	3 (30.0%)	3 (30.0%)	4 (40.0%)			
		C. TN + OTA + O	7	3 (42.86%)	1 (14.28%)	3 (42.86%)			

Abbreviation used

- TN only* - Topical Natamycin only
- TN + OTA* - Topical Natamycin + Other topical anti-fungal agent
- TN + OTA + O* - Topical Natamycin + Other topical anti-fungal + Oral anti-fungal agent

Note: 42 patients were divided into three groups depending on the treatment received.

Out of the 42 patients 27 were male and 15 were female, 7(16.67%) patients were literate and 35(83.33%) were illiterate patients, 35(88.10%) patients came from rural area and 5(11.90%) came from urban area. Commonest occupation was agriculture (80.96%) followed by labour, teacher, student each 4.75%, welding (2.38%) and housewife (2.38%).

Most of the patients 27 (64.29%) came to us after one week of onset of symptoms and 15(35.71%) came earlier within one week of symptomatic duration.

27(64.29%) patients given the trauma with vegetative matter before the onset of symptoms but rest did not. No patient was using contact lens^{8,9}.

35(83.33%) patient taken initial treatment from local doctor, quack, medical store or on their own before coming to us. Rest 7(16.67%) did not taken any medication before coming to us.

9(21.43%)patients taken corticosteroids for the treatment of corneal ulcer. Corneal perforation was the final outcome in all of them10(23.81%) patients presented to us with smaller ulcer (<10mm sq) and rest 32(76.19%) were with a larger (>10mm sq) ulcer. Bigger the ulcer size poor is the healing. Most of the patients 33(78.57%)came to us with deep corneal infiltration. Hypopion was present in 35(83.33%) patients and absent in 7(16.67%) only who shown good healing.

The haemoglobin level of 28(66.67%) patients was >10gm% and in rest 14(33.33%) haemoglobin level was <10gm%. Random blood sugar of only 1(2.38%) patient (known diabetic) was >200mg%, remaining 41(97.62%)random blood sugar was <200mg%. The total serum protein level of 28(66.67%) patients was <7gm% and it was >7gm% in 14 patients.

In our study 18 (42.86%) patients leave the study with successful healing of corneal ulcer, 9 (21.43%) required further treatment due to delayed healing response and treatment failure 15(35.71%) requiring active surgical treatment in form of conjunctival hooding, amniotic membrane graft, penetrating keratoplasty⁷ etc.

Conclusion

- a. Our study clearly indicate that:
- b. Fungal keratitis is more common in emaciated, poor, adult males, working in fields and living in poor environmental conditions. Healing remained the outcome of those patients who were healthy, literate, and came earlier to us after injury with a small ulcer without hypopion.
- c. Patients with systemic disease like anemia, hypoproteinemia, diabetes and any evidence of chronic infections remained the culprit of delayed healing or primary treatment failure.
- d. Anti-fungal treatment response was poor in patients who had taken initial therapy from local doctor, quacks, or on their own.
- e. Anti-fungal treatment response was worst in patients who had taken primary therapy in form of topical or systemic steroids.
- f. Patients having body surface area >150 M sq have shown good response to anti-fungal treatment and patients also responded well who were having hemoglobin > 10gm% and total serum protein >7gm%.
- g. Even a healed fungal corneal ulcer is a poor outcome of disease because we are not able to give useful vision to the patients due to dense corneal opacity formation.
- h. 5% Topical Natamycin remained treatment to make ulcer heal.

10. Br. J. Ophthalmol. 79:601-605 Johns KJ and DM O'Day. 1988 Pharmacologic management of Keratomycosis. *Surv. Ophthalmol*,33:178-188.
11. Prajna NV, John RK, Niramalan PK, et al, A randomized clinical trial comparing 2% econazole and 5% natamycin for the treatment of fungal keratitis. *Br J Ophthalmol* 2003;87:1235-7.
12. Prajna NV, John RK, Niramalan PK, et al, A randomized clinical trial comparing 2% econazole and 5% natamycin for the treatment of fungal keratitis. *Cornea* 2004;23:793-6.
13. Jennifer L. Wipperman, MD, and John N. Dorsch, MD, University of Kansas School of Medicine, Wichita, Kansas Evaluation and Management of Corneal Abrasions *Am Fam Physician*. 2013 Jan 15;87(2):114-120.

References

1. Arffa RC, Avni I, Ishbashi Y, et al: Calcofluor and ink-potassium hydroxide preparations for identifying fungi. *Am J Ophthalmol* 100:719,1985.
2. M J Bharathi, R Ramakrishnan, R Meenakshi, S Mittal, C Shivakumar, and M Srinivasan Microbiological diagnosis of infective keratitis: comparative evaluation of direct microscopy and culture results *Br J Ophthalmol*. 2006 Oct;90(10):1271-1276.
3. Poole TR, Hunter DL, Maliwa EM, Ramsay AR, Aetiology of microbial keratitis in northern Tanzania [letter]. *Br J Ophthalmol* 2002;86:941-2.
4. Hagan M, Wright E, Newman M, et al. Causes of suppurative keratitis in Ghana. *Br J Ophthalmol* 1995;79:1024-8.
5. Thomas PA1, Kaliyamurthy J. *Clin Microbiol Infect*. Mycotic keratitis: epidemiology, diagnosis and management. 2013 Mar;19(3):210-20. doi: 10.1111/1469-0691.12126. Epub 2013 Feb 9.
6. Manning M, Mitchell TG: Morphogenesis of *Candida albicans* and cytoplasmic proteins associated with differences in morphology, strain, or temperature, *J Bacteriol* 144:258,1980.
7. Kaufman HE, Wood RM Treatment of fungal keratitis by penetrating keratoplasty: *Am J Ophthalmol* 59:993,1965.
8. Wilhelmus KR, NM Robinson and RA Font. 1988 Fungal keratitis in contact lens wearers. *Am J Ophthalmol*.106:708-714.
9. Gray, T. B., R.T. Cursons., J.F. Sherwan, and P.R.Rose.1995. *Acanthamoeba* bacterial and fungal contamination of contact lens storage cases.