

A clinical study of corneal complications of manual small incision cataract surgery

Anitha S. Maiya^{1,*}, Akshatha M. Dharmesh², R. Jayaram³

¹Associate Professor, ²Senior Resident, ³Professor, Dept. of Ophthalmology, Adichunchanagiri Institute of Medical Sciences, B.G. Nagara, Mandya, Karnataka

***Corresponding Author:**

Email: dranithasmaiya@gmail.com

Abstract

Aims and objectives: To study: (i) the various postoperative corneal complications of manual small incision cataract surgery, (ii) the preoperative and intraoperative risk factors contributing to such complications, and (iii) the final visual outcome in the patients with corneal complications.

Design: It is a prospective, hospital based observational study.

Materials and methods: We studied 60 eyes of 60 consecutive patients with visually significant cataract who underwent manual small incision cataract surgery with implantation of posterior chamber intraocular lens. The postoperative corneal complications and best corrected visual acuity of these patients were studied on postoperative day 1, 7, 15, 30 and 45. The preoperative risk factors if any and intraoperative complications were noted.

Results: 60 eyes of 60 consecutive patients who underwent manual small incision cataract surgery were studied. Corneal complications were seen in 7 patients (11.67%); of these striate keratopathy was seen in 5 patients (8.3%), 1 patient (1.67%) had a Descemet's membrane detachment and 1 patient (1.67%) had microcystic corneal edema. Corneal complications were seen in patients with preoperative risk factors and in patients with intraoperative difficulties during surgery. At the end of 6 weeks postop, 95% of the patients achieved a best corrected visual acuity of 6/9 or better.

Conclusions: Corneal complications after Manual small incision cataract surgery should be anticipated in patients with preoperative risk factors and prolonged and difficult surgeries. With timely and appropriate treatment, most of the corneal complications resolve by the 2nd postoperative week. Careful preoperative planning and meticulous surgery can prevent most of these complications.

Keywords: Descemet's membrane detachment, Manual small incision cataract surgery, Microcystic corneal edema, Striate keratopathy.

Access this article online

Website:

www.innovativepublication.com

DOI:

10.5958/2395-1451.2016.00057.3

Introduction

There are 12.5 million blind people in India and it is estimated that 50-80% of this blindness is due to cataract.^[1,2] The prevalence of visually significant cataracts and the cataract surgical rates have rapidly increased over the past years.^[3] Cataract surgery is the most commonly performed and the most successful surgical procedure in patients above the age of 65 years.^[4]

Majority of the patients with visually significant cataract are economically backward and cannot afford modern and expensive techniques of cataract surgery like Phacoemulsification. Manual Small Incision Cataract Surgery (MSICS) has gained the distinction of being a safe and effective type of cataract surgery and thus an inexpensive alternative to phacoemulsification.^[5]

Since cornea is the major contributor to the refractive status of the eye, any corneal complication of

cataract surgery can have a deleterious effect on the postoperative visual outcome of the patient. A study by Hwang et al^[6] has reported epithelial disruption, corneal melt, infections, sterile ulceration, mechanical or toxic injury to the corneal endothelium, vitreous touch, Descemet's membrane detachment and epithelial/fibrous down growth as some of the postoperative corneal complications of cataract surgery.

As newer and improved techniques and modifications of cataract surgery evolve, the postoperative corneal complications continue to become less common. Damage to the corneal endothelium during surgery is the major cause of corneal complications. Thus, preservation of corneal endothelium continues to be a major goal for the operating surgeon.

This study has been undertaken to highlight the various corneal complications that can occur following MSICS, the preoperative risk factors and intraoperative complications that may contribute to these complications and to study the final visual outcome in the patients who have developed the corneal complications.

Materials and Methods

This prospective observational study was conducted in the Department of Ophthalmology, AIMS B.G. Nagara. We included 60 eyes of 60 consecutive

patients who underwent MSICS by a single surgeon (ASM) between November 2013- August 2014. This study included all patients with clinically significant cataract who were operated by the surgeon during the study period. This study was approved by the Institutional Ethical Committee and written informed consent was obtained from all the study participants.

Exclusion criteria: (i) Patients not willing to participate in the study/ adhere to the study protocol (ii) Patients with congenital cataract, traumatic cataract, active/ old uveitis and glaucoma (iii) Patients with pre-existing corneal diseases like corneal scars, corneal degenerations or preoperative corneal edema.

All patients underwent a comprehensive preoperative evaluation of the anterior and posterior segments including intraocular pressure measurements. A preoperative biometry was done to assess the power of the intraocular lens to be implanted. All patients received preoperative antibiotic prophylaxis started from one day prior to surgery (Systemic- T. Ciprofloxacin 500mg B.D for 5 days; Topically- Moxifloxacin 0.5% eye drops 1 drop every hourly). The eye to be operated was prepped with Povidone Iodine 5% on the day of the surgery and the pupil was dilated with eye drops containing Tropicamide (0.8%) and Phenylephrine (5%). Any preoperative risk factors (e.g. poorly dilating pupil, pseudoexfoliation syndrome etc.) and grade of cataract was recorded in every patient.

MSICS with posterior chamber intraocular lens implantation was performed by following the standard surgical protocol. All the surgeries were performed under peribulbar anaesthesia. Under aseptic precautions, the eye to be operated was painted and draped and eyelids were separated by a speculum and a superior rectus bridle suture was applied. A fornix based conjunctival flap was raised and hemostasis achieved using bipolar cautery. A 6.5mm sclerocorneal tunnel was made in the superior quadrant 2mm above the superior limbus. A sideport incision was made at 8 o'clock position and anterior chamber entry from the main incision was made using a 2.8mm keratome blade and enlarged on either sides. A central circular capsulorrhexis of 6mm diameter was done followed by a gentle hydrodissection. The nucleus was prolapsed into the anterior chamber and delivered out using a wire vectis. After a complete cortical clean-up, a single-piece Poly Methyl Methacrylate intraocular lens was implanted into the capsular bag. During each of the intraocular steps adequate viscoelastic substance (2% HPMC) was used to protect the corneal endothelium and maintain the anterior chamber. At the end of the surgery, anterior chamber was formed with balanced salt solution/air and a subconjunctival injection of Gentamicin with Dexamethasone was given in the inferior quadrant and the eye covered with a sterile eye pad.

The duration of the surgery, any intraoperative difficulties and complications were noted down.

On the first postoperative day, visual acuity and slitlamp evaluation was done in all patients and any corneal complications were recorded. All patients received a standard regimen of topical antibiotics-steroid containing eye drops used every hourly for the first 7 days and then every 2nd hourly for the next 7 days and then gradually tapered over the next 4 weeks. Patients who developed corneal complications in addition received cycloplegics (Homatropine), hyperosmotic agent (5% sodium chloride eye drops 6th hourly; 6% ointment at HS) and antiglaucoma medications if the intraocular pressure was found to be increased. These medications were stopped on clinical resolution of corneal edema.

The patients were reviewed on day 1, 7, 15, 30 and 45 and during each visit the best corrected visual acuity was recorded and a slit lamp evaluation was done to note the corneal status, postoperative inflammation, intraocular lens position and status of the posterior segment.

Results

This study included 60 eyes of 60 consecutive patients who underwent MSICS with intraocular lens implantation by a single surgeon in the Department of Ophthalmology, Adichunchangiri Institute of Medical Sciences, B.G. Nagara. The following observations were made:

Table 1: Demographic characteristics of the patients

	Number of patients	Percentage (%)
1. Age wise distribution of patients		
40-49 years	4	6.67
50-59 years	17	28.33
60-69 years	21	35
70-79 years	18	30
2. Sex distribution of patients		
Male	28	46.67
Female	32	53.33
3. Laterality of the operated eyes		
Right eye	35	58.33
Left eye	25	41.67
4. Preoperative best corrected visual acuity		
>= 6/60	14	23.33
5/50-1/60	30	50
Hand movements-perception of light	16	26.67
5. Type of cataract		
Nuclear cataract grade I-II	4	6.67
Nuclear cataract grade III-IV	12	20
Mature cataract	12	20
Hyper mature cataract	6	10
Posterior subcapsular	9	15

cataract		
Cortical cataract	17	28.33

Majority of the patients belonged to the 60-69 years age group and the sex ratio and laterality of the operated eye was comparable.

Table 2: Corneal complications encountered in the study

Corneal complications	Number of patients				
	POD 1	POD 7	POD 15	POD 30	POD 45
Striate keratopathy with <10 DMF (mild grade)	3	1	–	–	–
Striate keratopathy with >10 DMF (severe grade)	2	2	1	–	–
Descemet's membrane detachment	1	–	–	–	–
Microcystic corneal edema	1	–	–	–	–
Corneal decompensation	–	–	–	–	–
No complications	53	57	59	60	60

(POD= Postoperative day; DMF= Descemet's membrane folds)

The most common corneal complication encountered in the study was striate keratopathy of a mild grade which was seen in 3 patients (5%) which resolved with treatment by the 10th postoperative day in all the 3 patients. A severe grade of striate keratopathy was seen in 2 patients (3.33%). This resolved by the 2nd postoperative week in one patient and by 3 weeks in the second patient. One patient (1.67%) developed microcystic corneal edema which was secondary to increased intraocular pressure, which resolved with institution of anti-glaucoma therapy by the 2nd postoperative day. None of our patients developed corneal decompensation.

Table 3. Postoperative best corrected visual acuity (by Snellen's chart) in our patients

BCVA	Number of eyes				
	POD 1	POD 7	POD 15	POD 30	POD 45
<6/60	2	1	-	-	-
6/60-6/24	6	5	1	-	-
6/18-6/12	29	20	10	5	3
6/9-6/6	23	34	49	55	57
Total	60	60	60	60	60

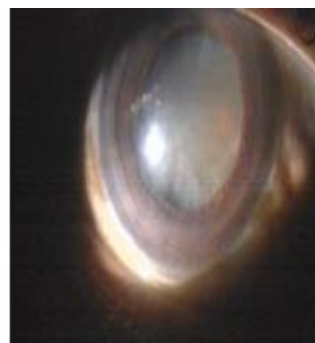


Fig. 1: Showing cases with shallow anterior chamber & intumescent cataracts

On the 1st postoperative day, majority of the patients (29; 48.33%) had BCVA of 6/18-6/12. By the 45th postoperative day, 95% of the patients had attained a visual acuity of >6/9.

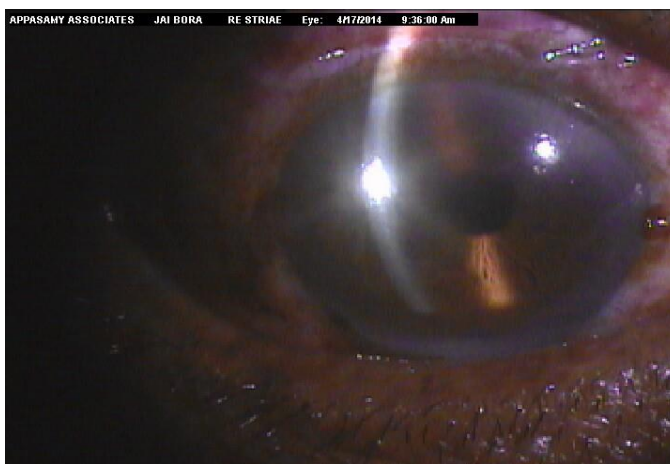Discussion

Age related cataracts constitute a major cause of visual disability among the elderly population in our country. MSICS has gained widespread popularity as a safe and cost-effective method of cataract surgery. A randomized control study in Pune has found MSICS to be as effective and more economical than phacoemulsification^[7].

Corneal complications were seen in only 7 patients (11.67%; total of 60 patients) and majority of these resolved by 2 weeks postop.

Table 5: Comparison of the corneal complications found in our study with other studies

Corneal complications	Rengaraj V et al ^[7]	Sudhakar J et al ^[8]	Present study
Striate keratopathy	13%	7.3%	11.67%

**Fig. 2: Showing mild striate keratopathy on postoperative day 1**

It was found that corneal complications developed in patients who had preoperative risk factors and intraoperative events as elaborated in Table 6.

Table 6: Preoperative risk factors, intraoperative complications and intraoperative risk factors and their association in patients who developed corneal complications

Risk factors	No. of eyes	Corneal complications among the patients with the risk factors	
		Present	Absent
Preoperative risk factors			
1. Pseudoexfoliation syndrome	4	2	2
2. Poorly dilating pupil	4	1	3
3. Intumescent mature cataract	3	2	1
4. Hard nucleus	4	2	2
Intraoperative complications			
1. Premature entry during tunnelling	1	0	1
2. Posterior capsular rupture	1	1	0
3. Descemet's membrane detachment	1	1	0
4. No complications	57	5	52
Intraoperative risk factors			
1. Increased manoeuvring in the anterior chamber for nucleus management	4	4	0
2. Use of blunt instruments for incision creation	1	1	0
3. Prolonged duration of surgery	2	2	0

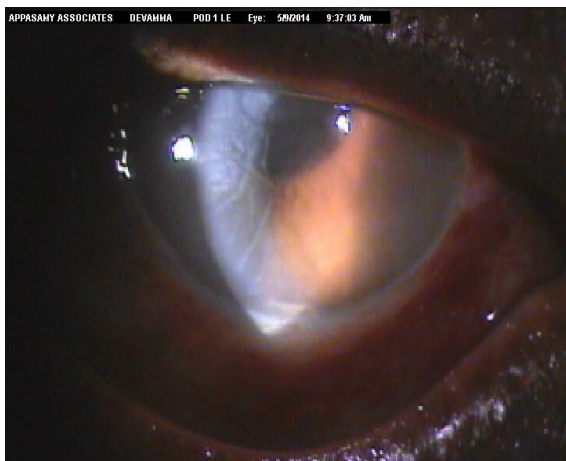


Fig. 3: Showing severe striate keratopathy on postoperative day 1

Kanski mentioned that corneal edema following cataract surgery is usually transient and often caused by intraoperative trauma to the endothelium by contact with instruments, lens matter or the intraocular lens. A complicated and prolonged surgery and postoperative intraocular pressure spike may also contribute to this.^[9]

Taking adequate precautions intraoperatively like use of plenty of viscoelastic substance to protect the corneal endothelium, meticulous surgery, decreasing the duration of surgery and use of good quality instruments can help in preventing most of the postoperative corneal complications especially in patients with pre-existing risk factors.

If we look at the final visual outcome of our patients, 95% had achieved excellent best corrected visual acuity of > 6/9 and 5% had best corrected visual acuity between 6/18-6/12. Thus the inference drawn was that timely and appropriate management of the corneal complications yields good postoperative visual outcomes.

The main drawbacks of our study are: (i) small sample size (ii) due to non-availability of corneal pachymeter and specular microscopy in our hospital, an objective evidence of the corneal endothelial status in the preoperative and postoperative periods could not be ascertained.

Summary

MSICS is a cost effective and safe technique of cataract surgery which is commonly performed in rural hospitals where the patients cannot afford phacoemulsification. Corneal complications should be anticipated in patients with preoperative risk factors like pseudoexfoliation syndrome, hard cataracts and poorly dilating pupil where the operating surgeon may encounter several intraoperative difficulties and complications. Careful preoperative planning and meticulous surgery paying careful attention to the cornea can prevent most of the serious corneal complications. Timely and appropriate management of

the postoperative corneal complications helps the surgeon to achieve good postoperative visual outcomes.

References

1. Dandona L, Dandona R, Naduvilath T, McCarty CA, Nanda A, Srinivas m et al. Is the current eye-care policy focus almost exclusively on cataract adequate to deal with blindness in India? *The Lancet*. 1998;74:341-343.
2. Jose R. National Programme for control of blindness. *Indian J Community Health*. 1997;3:5-9.
3. Minassian D, Mehra V. 3.8 million blinded by cataract each year: Projections from the first epidemiological study of incidence of cataract blindness in India, *Br J Ophthalmol*. 1990;74:341-343.
4. Jaffe NS, Jaffe MS, Jaffe FG. Decision to operate. 6th ed. Chapter 1. In: *Cataract surgery and its complications*, Jaffe, Norman S ed: Mosby 1997.
5. Gogate PM, Kulkarni SR, Krishnaiah S, Deshpande RD, Joshi SA, Palimar A. Safety and efficacy of phacoemulsification compared with manual small incision cataract surgery by a randomized controlled trial: six-week results. *Ophthalmology*.2005;112(5):869-874.
6. Hwang DG, Smith RE. corneal complications of cataract surgery. *Refract Corneal Surg*. 1991;7(1):77-80.
7. Venkatesh R, Das M, Prashanth S, Muralikrishnan R. Manual small incision cataract surgery in eyes with white cataracts. *Indian J Ophthalmol*.2005;53:173-176.
8. Sudhakar J, Ravindra R.D. Analysis of complications in 1000 cases of posterior chamber intraocular lens implantation. *Indian J Ophthalmol*. 1989;37(2):78-79.
9. Kanski JJ. Management of age related cataract. In: *Kanski Clinical Ophthalmology*. 6th ed., Elsevier, 2007. 360.