

Comparing the effectiveness and safety of sub-tenon's anaesthesia and peribulbar anaesthesia in anterior segment surgery

Sumeet Deshpande^{1,*}, Sunita S Deshpande², Rajashree Reddy³, Vishwanath Reddy⁴

¹Assistant Professor, ²Senior Resident, ³Associate Professor, ⁴Professor & HOD, Dept. of Ophthalmology, Mahadevappa Rampure Medical College, Kalaburgi

***Corresponding Author:**

Email: resdoc555@gmail.com

Abstract

Introduction: Proper anaesthetic management is an integral part of any successful eye surgery. Patient comfort during the operative procedure is the single most important factor. The search for surgical adjuncts to achieve anaesthesia and akinesia has produced many advances, easing the ordeal of surgery for both the patient and the surgeon.

Methods: 500 patients undergoing anterior segment surgery after obtaining consent were included in the study. Out of which, 250 were administered peribulbar while 250 were given sub-Tenon's anaesthesia randomly. Pain during administration of anaesthesia, during surgery and 4 h after surgery was graded on a visual analogue pain scale and compared for both the techniques. Sub-conjunctival haemorrhage, chemosis, akinesia after administration of anaesthesia and positive pressure during surgery were also compared. Patients were followed up for 6 weeks postoperatively.

Results: The sub-Tenon's anaesthesia procedure was painless for 25.2% of the patients; The peribulbar anaesthesia procedure was painless for 8.91% of the patients. The anaesthetic block was very efficient with both the techniques. Pain during anaesthetic administration was lower for sub-Tenon's anaesthesia (63, 25.2%). Chemosis, sub conjunctival haemorrhage was more common with sub-Tenon's anaesthesia. Akinesia was better with peribulbar anaesthesia

Conclusion: The volume of anaesthetic injected is more with peribulbar anaesthesia when compared to sub-Tenon's anaesthesia. Pain during anaesthetic administration is lower with sub-Tenon's anaesthesia compared with the peribulbar technique. Chemosis and subconjunctival haemorrhage are more frequent with sub-Tenons anaesthesia.

Keywords: Cataract, Complications, Pain, Peribulbar, Sub-tenon's anaesthesia

Access this article online

Website:

www.innovativepublication.com

DOI:

10.5958/2395-1451.2016.00044.5

This study was done to compare the effectiveness and safety of sub-Tenon's anaesthesia and peribulbar anaesthesia in anterior segment surgery.

Materials & Methods

The present study was carried out at Mahadevappa Rampure Medical College, Kalaburgi from October 2013 to September 2015. Institutional ethics committee approval was sought.

All the patients undergoing anterior segment surgery were asked to participate in the study. The first 500 patients who agreed were randomized to either peribulbar anaesthesia or subtenon's anaesthesia after obtaining consent from the included in the study. Out of the 500 patients, 250 were administered peribulbar while 250 were given sub-Tenon's anaesthesia randomly. There was no grouping of patients in regard to age, sex or race. Visual acuity was recorded. Type of cataract was assessed. Intraocular tension and blood pressure were noted. Sac syringing for patency of lacrimal system was done. Blood and urine sugar were estimated. Keratometry and axial scan measurements were carried out (to calculate the intraocular lens power) on patients posted for cataract surgery.

Exclusion criteria:

1. Age < 30 or > 90 years,
2. Age < 30 or > 90 years,
3. sensitivity to Xylocaine,
4. history of convulsion, epilepsy,

Introduction

Proper anaesthetic management is an integral part of any successful eye surgery. Patient comfort during the operative procedure is the single most important factor. The search for surgical adjuncts to achieve anaesthesia and akinesia has produced many advances, easing the ordeal of surgery for both the patient and the surgeon.

Peribulbar or retrobulbar anaesthesia, which providing excellent analgesia and akinesia have been associated with rare but numerous ocular complications including diplopia, orbital haemorrhage, globe perforation, central retinal vein or artery occlusion, brain stem anaesthesia, optic nerve trauma and ptosis.¹⁻⁵

Sub-Tenon's anaesthesia avoids sharp needles being passed into the orbit but chemosis, subconjunctival haemorrhage and poor akinesia are frequent. Ideally an anaesthetic technique must be completely safe, simple, easy and cause maximum benefit with minimum anaesthetic agent.

5. inability to give informed consent,
6. previous intraocular injury, inflammation or surgery,
7. Age < 30 or > 90 years,
8. sensitivity to Xylocaine,
9. history of convulsion, epilepsy,
10. inability to give informed consent,
11. previous intraocular injury, inflammation or surgery,
12. pupil <5 mm in diameter,
13. Age < 30 or > 90 years,
14. sensitivity to Xylocaine,
15. history of convulsion, epilepsy,
16. inability to give informed consent,
17. previous intraocular injury, inflammation or surgery,
18. pupil <5 mm in diameter,
19. inability to understand the visual analogue pain scale. Age < 30 or > 90 years,
20. sensitivity to Xylocaine,
21. history of convulsion, epilepsy,
22. inability to give informed consent,
23. previous intraocular injury, inflammation or surgery,
24. pupil <5 mm in diameter

Patients with diabetes were asked to skip their morning dose of medications while those having hypertension were asked to take their medications. Patients on anticoagulants were asked to stop the medication two days before surgery. Patients who had diabetes and/or hypertension were to produce fitness certificate, certified by the physician. Drug history was recorded.

Anaesthetist help was taken in cases which required to be operated under the provision of pulse oximeter, respiratory support and cardiopulmonary resuscitation.

Routine premedication consisted of tablet ciprofloxacin 500 mg one tablet at night and one tablet 2 hrs before surgery. Cyclopentolate 0.5% and phenylephrine 10% eye drops were used to dilate the pupil. Diclofenac eye drops were used pre operatively to prevent intraoperative miosis. Patients who were to be operated for trabeculectomy received 1-2g/kg of Mannitol intravenously half an hour before surgery, oral acetazolamide 250 mg two hours before surgery, topical timolol acetate 0.5% and pilocarpine 2% eye drops depending on the preoperative tension.

Materials

- Eye speculum
- Westcott's scissors
- Toothed forceps or Colibri 5ml disposable syringe
- Sub-Tenon's cannula (22 gauge, blunt, curved, 26mm in length)
- Injection 2% lignocaine with 1:200,000 adrenaline
- 1500 IU of hyaluronidase Injection 0.5% bupivacaine 10% povidone iodine Cotton swabs

- Eye pads
- Eye towels

Anaesthesia mixture: 4ml of 2% lignocaine with 1:200,000 adrenaline with 30 IU of hyaluronidase +1 ml of 0.5% bupivacaine. The volume used for peribulbar anaesthesia was 4 to 10 ml and sub-Tenon's anaesthesia 2 to 3.5 ml of the above anaesthesia mixture respectively.

Anaesthesia technique:

Peribulbar anaesthesia: The operating eye is painted with 10% povidone iodine. After draping the eye, patient is asked to maintain primary position. Anaesthetic mixture is injected using a 24 gauge needle (the hub of the needle indenting the skin, aspiration is done to check if the needle is in any vessel) at the junction of middle and outer third of the lower orbital margin with the (bevel of the needle facing upwards) needle directed towards the floor of the orbit. If this is not satisfactory, the injection is given at the same site or at the supraorbital notch (bevel facing downwards, needle directed towards the orbital roof). Digital pressure is maintained intermittently for 2 to 5 minutes.

Sub-Tenon's anaesthesia: The operating eye is painted with 10% povidone iodine. After draping the eye, speculum is applied. Two to four drops of topical 4% lignocaine is instilled. The best exposed quadrant or the quadrant away from the site of surgery is selected. The patient is asked to move his eye so as to expose the area to be injected. Conjunctival tissue and the Tenon's fascia are grasped with the Colibri forceps. A small nick is made to expose the sclera 3mm away from the limbus. The scissors are reintroduced to further separate the Tenon's fascia. The sub-Tenon's cannula is introduced along a path following the contour of the globe till the hub of the cannula fits into the opening made. 2 to 3.5ml of the anaesthetic mixture is delivered rapidly. Digital pressure is maintained intermittently for 1 to 2 minutes.

The patient was asked to gauge for the pain during administration of the anaesthetic, pain during surgery and after it was completed. Postoperative pain after 4 h was also recorded. After each surgery the surgeon was asked to score for akinesia and to grade for positive pressure during surgery, chemosis, subconjunctival haemorrhage and overall 'discomfort'. Intraoperative complications were noted. The patients were followed on the first postoperative day, first week and sixth week after surgery. The postoperative complications were noted, as also the best corrected postoperative visual acuity and refraction.

The patients were asked to grade the pain they felt on a linear scale of 0-4 (No pain = grade 0, mild pain = grade 1, moderate pain = grade 2, severe pain = grade 3 and maximum pain imaginable = grade 4). Patients were asked to grade separately for pain during administration of anaesthesia, pain during surgery and pain 4 h after surgery. The last was taken when the patient was shifted to the wards.

The patients were asked to grade the pain they felt on a linear scale of 0-4 (No pain = grade 0, mild pain = grade 1, moderate pain = grade 2, severe pain = grade 3 and maximum pain imaginable = grade 4). Patients were asked to grade separately for pain during administration of anaesthesia, pain during surgery and pain 4 h after surgery. The last was taken when the patient was shifted to the wards.

The ophthalmologists also graded for chemosis, subconjunctival haemorrhage after administration of anaesthesia and positive pressure during surgery on a scale of 0-4, of increasing severity. The patients were asked to grade the pain they felt on a linear scale of 0-4 (No pain = grade 0, mild pain = grade 1, moderate pain = grade 2, severe pain = grade 3 and maximum pain imaginable = grade 4). Patients were asked to grade separately for pain during administration of anaesthesia, pain during surgery and pain 4 h after surgery. The last was taken when the patient was shifted to the wards. 'Akinesia' the patients were asked to grade the pain they felt on a linear scale of 0-4 (No pain = grade 0, mild pain = grade 1, moderate pain = grade 2, severe pain = grade 3 and maximum pain imaginable = grade 4). Patients were asked to grade separately for pain during administration of anaesthesia, pain during surgery and pain 4 h after surgery. The last was taken when the patient was shifted to the wards was scored on a scale designed to measure ocular movements in each quadrant (no movement = score 0, mild = 1, moderate = 2, severe = 3 in each quadrant, minimum score possible = 0, maximum score possible = $3 \times 4 = 12$). The patients were asked to grade the pain they felt on a linear scale of 0-4 (No pain = grade 0, mild pain = grade 1, moderate pain = grade 2, severe pain = grade 3 and maximum pain imaginable = grade 4). Patients were asked to grade separately for pain during administration of anaesthesia, pain during surgery and pain 4 h after surgery. The last was taken when the patient was shifted to the wards.

The surgeon also graded for the 'discomfort' he felt during surgery (grade 0 = no discomfort, grade 1 = mild discomfort, grade 2 = moderate, grade 3 = severe, grade 4 = surgery not possible).

Time taken for completion of surgery and the volume of anaesthetic injected were also noted.

Results

In the sub-Tenon's group, 60 patients had cataract extraction by phacoemulsification technique, 151 patients had small incision cataract surgery done. In the peribulbar group, 84 patients had cataract extraction by phacoemulsification technique, 93 patients had small incision cataract surgery done. Fig. 1 shows types of surgeries performed with peribulbar and sub tenon's anaesthesia. Parameters used under sub-Tenon's and peribulbar anaesthesia were statistically evaluated using „Z" test. There was no significant difference between the groups with respect to duration of surgery and the type of surgery.

The volume of anaesthetic injected ranged from 2ml to 3.5ml in the sub-Tenon's group while it ranged from 4ml to 9ml (in a combined superior and inferior injection) in peribulbar group. Peribulbar group required more amount of anaesthetic to be injected.

Pain scores for administration of anaesthesia were significantly lower (Z test, $p < 0.001$) for sub-Tenon's anaesthesia (mean 0.87 ± 0.68) compared with the peribulbar technique (mean 1.60 ± 0.80). The sub-Tenon's anaesthesia procedure was painless for 25.2% of the patients; 67.2% of the patients reported slight sensation or discomfort but no pain; and 4% of the patients experienced slight pain. The peribulbar anaesthesia procedure was painless for 8.91% of the patients; 33.3% of the patients reported slight sensation or discomfort but no pain; and 46.56% of the patients experienced slight pain ($p < 0.001$, statistically significant).

The anaesthetic block was very efficient with both the techniques. 94% of the patients, in the sub-Tenon's group and 95.14% of the patients in the peribulbar group reported no pain during surgery ($p > 0.05$, statistically not significant). Pain during anaesthetic administration was lower for sub-Tenon's anaesthesia (63, 25.2%). Chemosis is more common with sub-Tenon's anaesthesia. Subconjunctival haemorrhage is more common with sub-Tenon's anaesthesia.

Akinesia: 63.2% of the patients had no movement; and 31.2% of the patients had slight movement under sub-Tenon's anaesthesia. 80.57% of the patients had no movement; and 18.22% of the patients had slight movement under peribulbar anaesthesia. ($p < 0.001$, statically significant). 3.6% of the patients had moderate movement and 2% of the patients had complete movement under sub-Tenon's anaesthesia. Akinesia was better with peribulbar anaesthesia (mean 2.79 ± 0.43) compared to sub-Tenon's anaesthesia (mean 2.56 ± 0.66). The difference is statistically significant ($p < 0.001$).

Chemosis & sub conjunctival haemorrhage: With sub-Tenon's anaesthesia, 50% of the patients had no chemosis; 41.6% of the patients had chemosis involving one quadrant; and 7.2% of the patients had chemosis involving two quadrants. While 80.57% of the patients had no chemosis; 15.38% of the patients had chemosis involving one quadrant; and 3.24% of the patients had chemosis involving two quadrants with the peribulbar technique ($p < 0.001$). The mean score for chemosis was 0.6 ± 0.68 for the sub-Tenon's group and 0.24 ± 0.55 for the peribulbar group. The difference is statistically significant ($p < 0.001$).

With the sub-Tenon's technique, 45.2% of the patients had no haemorrhage; 50.4% of the patients had haemorrhage involving one quadrant; and 4.0% of the patients had haemorrhage involving two quadrants. 90.28% of the patients had no haemorrhage; 8.5% of the patients had haemorrhage involving one quadrant; and 0.4% of the patients had haemorrhage involving two quadrants with peribulbar technique ($p < 0.001$).

The mean score for subconjunctival haemorrhage was 0.6 ± 0.59 with sub-Tenon's anaesthesia and 0.12 ± 0.40 with peribulbar anaesthesia. The difference is statistically significant ($p < 0.001$) (Table 2 & 3)

Both the techniques provided excellent anaesthesia during surgery. The operation time ranged from 10 minutes to 45 minutes under sub-Tenon's and 15 to 45 minutes under peribulbar anaesthesia. The incidence of globe perforation in our study is 0.8% (2 in 250 cases) and that of retrobulbar haemorrhage is 0.4% (1 in 250 cases) with peribulbar anaesthesia. No complications were seen with sub-Tenon's anaesthesia, which is an encouraging factor.

Complications: With peribulbar technique, two patients (0.8%, 2 in 250 cases) had inadvertent globe perforation and one patient (0.4%, 1 in 250 cases) developed retrobulbar haemorrhage. 24 gauge needle (Sharp) was used to administer peribulbar block.

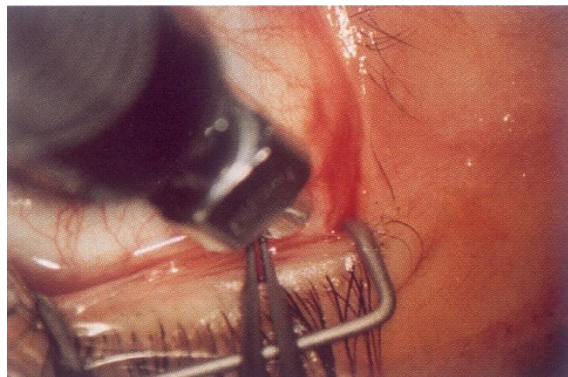


Fig. 2: Sub-Tenon's Cannula Introduced into the Tenon's Space

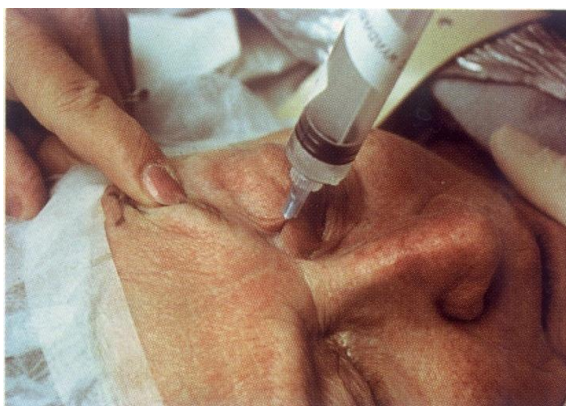

Fig. 1: Peribulbar Anaesthesia

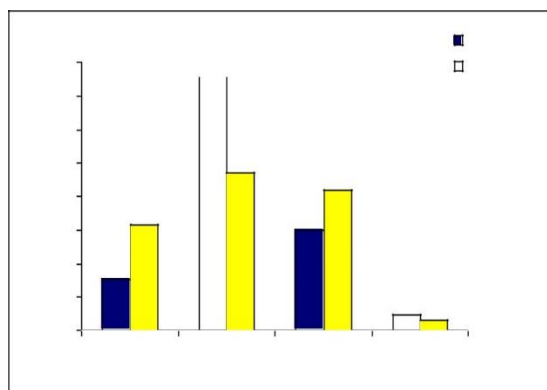


Table 1: Pain during anaesthetic administration

Grade	No. of Patients		p-value
	Sub-Tenon's Anaesthesia	Peribulbar Anaesthesia	
0	63(25.2%)	22(8.91%)	p<0.001
+1	168(67.2%)	82(33.2%)	P<0.001
+2	10(4%)	115(46.56%)	P<0.001
+3	7(2.8%)	28(11.34%)	p>0.001
+4	2(0.8%)	0	-
Total	250	247	

Table 2: Chemosis

Grade	No. of Patients		p Value
	Sub-Tenon's Anaesthesia	Peribulbar Anaesthesia	
0	125(50%)	199(80.57%)	p<0.001
+1	104(41.6%)	38(15.38%)	p<0.001
+2	18(7.2%)	8(3.24%)	p<0.05
+3	3(1.2%)	2(0.84%)	p>0.05
Total	250	247	

Table 3: Subconjunctival haemorrhage

Grade	No. of Patients		p-value
	Sub-Tenon's Anaesthesia	Peribulbar Anaesthesia	
0	113(45.2%)	223(90.28%)	p<0.001
+1	126(50.4%)	21(8.5%)	p<0.001
+2	10(4.0%)	1(0.4%)	p<0.01
+3	1(0.4%)	2(0.81%)	p>0.05

Discussion

The technique of peribulbar anaesthesia has recently been preferred to retrobulbar anaesthesia as it is associated with a smaller risk of globe perforation, retrobulbar haemorrhage, optic nerve damage and injection of the anaesthetic solution into the subarachnoid space⁶. However, the peribulbar method itself is not absolutely safe, as has been reported frequently^{7,8}. Subconjunctival anaesthesia is a further effective and safer alternative; however, this technique provides no akinesia.⁹ Sub-Tenon's anaesthesia as described by Hansen et al and by Stevens has recently become popular as it provides effective anaesthesia and akinesia without the risks associated with retrobulbar and to a lesser extent peribulbar anaesthesia^{10,11}.

In a study by Briggs MC et al, pain scores for administration of anaesthetic were significantly lower for sub-Tenon's anaesthesia compared with the peribulbar technique¹². These findings correlate with our study.

Patients find not having an injection through skin, simple and relatively painless.

For peribulbar anaesthesia, large volume of anaesthetic has to be placed extraconally for it to reach the ciliary ganglion and time to anaesthetic effect can be more than several minutes.

Briggs et al report per operative (during surgery) pain scores for sub-Tenon's anaesthesia to be lower than those for peribulbar but not significantly so.¹²

Pain during anaesthesia (Sub-Tenon's Group)

Parameter	Stan J et al ¹³	Zafirakis et al ¹⁴	Present Study
Grade 0	97.3%	86%	94%

Akinesia: Akinesia was better with peribulbar anaesthesia (mean 2.79 ± 0.43) compared to sub-Tenon's anaesthesia (mean 2.56 ± 0.66). The difference is statistically significant ($p < 0.001$). Stan J Roman et al and Tsuneoka et al report poor akinesia with 1 ml of 2% lignocaine solution¹³.

The volume of anaesthetic used for sub-Tenon's anaesthesia in the literature ranges from 1 ml to 5 ml. Greenbaum states that akinesia is directly proportional to the volume of anaesthetic injected¹⁵. Tokuda and co-workers state that for cataract surgery, 3ml is the optimal dose of anaesthetic solution in sub-Tenon's anaesthesia which correlates with our study which includes 2-3 ml¹⁶.

In our study, for sub-Tenon's anaesthesia, we have used 2-3.5 ml of 2% lignocaine with 1:200,000 adrenaline with 30IU of hyaluronidase and 0.5% bupivacaine. It correlates with Steven et al study who also used 30IU/ml of hyaluronidase. 12 while guise and Alwithri et al used 150IU.^{17,18}

In our study no complications occurred during surgery because of ocular motility.

However if the surgeon finds difficult to work without akinesia or in cases of patients completely unable to operate, peribulbar anaesthesia is preferred.

Akinesia if not sufficient, a top-up can easily be given in the sub-Tenon's group.

Sub-Tenon's block was repeated (1 ml) in 5 cases who had complete movements (akinesia was not deemed sufficient).

Complete akinesia with subtenon group was observed in 62% of cases while it was 41% in karpan et al study and 81% in merle et al study^{19,20}. Difference in the volume or mixture of the anaesthetic solution administered can explain the various reports of akinesia depending on publications.

Chemosis is more common with sub-Tenon's anaesthesia. In this study it was reported in more than 1 quadrant in 21% of cases while Stan j et al and watermen et al reported 39.4% and 39.8% respectively^{13,21}.

It takes a little practice to limit chemosis by ensuring that the anaesthetic solution is truly delivered to the posterior sub-Tenon's space and not to the anterior subconjunctival space. In many cases chemosis disappeared after digital massage.

Subconjunctival haemorrhage is caused by fine vessels inevitably severed on making the conjunctival cut during the sub-Tenon's technique. In our study, subconjunctival haemorrhage was frequent with sub-Tenon's technique. Stevens reports subconjunctival haemorrhage in 32% of the patients who were administered sub-Tenon's anaesthesia. In a study by Stan J Roman et al, subconjunctival haemorrhage was frequent and more than half of the patients (56%) had subconjunctival haemorrhage with sub-Tenon's technique¹³. A finding which co-relates with our study (54.8%)

For sub-Tenon's anaesthesia, we selected the best exposed quadrant or the quadrant away from the operative section. Chemosis and subconjunctival haemorrhage did not interfere with the operation.

Greenbaum advocates cauterization before making the button hole to lower the incidence of haemorrhage¹⁵.

Kastev and associates have suggested that the orbital apex contains large vessels and therefore the depth to which needles are inserted should be limited to 31 mm from the orbital rim²².

Three anterior orbital locations are relatively avascular, the inferotemporal, superotemporal and the superonasal. It has been mentioned in the literature that the superonasal area should be strenuously avoided because the end vessels of the ophthalmic artery are located there.

Inadvertent globe perforation occurred in two cases (0.8%) with peribulbar technique. The patients experienced marked pain and had excessive hypotony. The axial length in one of the patient was more than 26 mm.

In a study of 20 ocular perforations reported by Duker and co-workers, 18 perforations occurred with a retrobulbar technique, whereas only two were attributed to a periocular technique. Of the 20 injured eyes, 9 (45%) had an axial length greater than 26mm²³.

In our study, we have used 22 gauge, curved, blunt(26mm length)cannula for sub-tenon's anaesthesia. No complications occurred due to the use of this cannula. Techniques requiring multiple needle placements are associated with an increased incidence of complications compared with a single or reduced number of injections. In our study peribulbar anaesthesia was associated with rare but vision threatening complications. No complications occurred with the sub-Tenon's technique. Sub-Tenon's anaesthesia is a safe, simple, atraumatic technique.

Summary and Conclusion

The volume of anaesthetic injected is more with peribulbar anaesthesia when compared to sub-Tenon's anaesthesia. Pain during anaesthetic administration is lower with sub-Tenon's anaesthesia compared with the peribulbar technique. Chemosis and subconjunctival haemorrhage are more frequent with sub-Tenon's anaesthesia. They did not interfere with the surgery. Akinesia is limited with sub-Tenon's anaesthesia. No complications have occurred during surgery because of ocular motility. Both the techniques provided excellent anaesthesia during surgery.

References

1. Davis DB, Mandel MR. Efficacy and complication rate of 16224 consecutive peribulbar blocks, a prospective multicenter study. *J Cataract Surg.* 1994 20:327-337.
2. Wylie J, Henderson M, Doyle M, Dwyer-Hickey M. Persistent binocular diplopia following cataract surgery: aetiology and management. *Eye* 1994;8:543-546.
3. Puustjarvi T, Purhonen S. Permanent blindness following retrobulbar haemorrhage after peribulbar anaesthesia for cataract surgery. *Ophthalmic Surg* 1992;23:450-452.
4. Duker JS, Belmont JB, Benson WB. Inadvertent globe perforation during retrobulbar and peribulbar anaesthesia. *Ophthalmology* 1991;98:519-526.
5. Klein ML, Jampol LM, Condon PI, Rice TA, Serjeant GR. Central retinal artery occlusion after retrobulbar blockade. *Am J Ophthalmol* 1982;93:573-577.
6. Davis DB, Mandel MR. Posterior peribulbar anaesthesia: Davis DB, Mandel MR. Posterior peribulbar anaesthesia - alternative to retrobulbar anaesthesia Davis DB, Mandel MR. Posterior peribulbar anaesthesia. Davis DB, Mandel MR. Posterior peribulbar anaesthesia J Cataract Refract Surg Davis DB, Mandel MR. Posterior peribulbar anaesthesia-1986;12:182-4.
7. Mount AM, Seward He. Scleral perforations during peribulbar anaesthesia. *Eye* 1993;7:766-7.
8. Hawksworth NR. Peribulbar anaesthesia [letter]. *Br J Ophthalmol* 1992;76:254.
9. Redmond RM, Dallas NL. Extracapsular cataract extraction under local anaesthesia without retrobulbar anaesthesia. *Br J Ophthalmol* 1990;74:203-4.
10. Hansen EA, Mein CE, Mazzoli R. Ocular anaesthesia for cataract surgery: a direct sub-Tenon's approach. *Ophthalmic Surg* 1990;21:696-9.
11. Stevens JD. A new local anaesthetic technique for cataract extraction by one quadrant sub-Tenon's infiltration. *Br J Ophthalmol* 1992;76:670-4.
12. Briggs M C, Beck S A, Esakowitz L. Sub-Tenon's versus peribulbar anaesthesia for cataract surgery. *Eye.* 1997;11(pt 5):639-43.
13. Stan J Roman, Didier A Chongsit, Catherine M Boureau, Francois x auclin, Martine M Mullern. Sub-tenon's anaesthesia: an efficient and safe technique. *British journal of ophthalmology.* January 1997;81(8):673-6.
14. Zafirakis P, Voudouri A, Rowe S, Livir-Rallatos G, Livir-Rallatos-C, Cnakis C, Kokolakis S, Baltatzis S, Theodossiadis G. Topical versus sub-Tenon's anaesthesia without sedation in cataract surgery. *Journal of cataract and refractive surgery.* 2001 June 27(6):873-9.
15. Scott Greenbaum. Parabolbar anaesthesia. *Anaesthesia. Ophthalmology clinics of north America.* March 1998;131-32.
16. Tokuda Y, Oshika T, Amano S, Inouye J, Yoshitomi F. A Analgesic effects of sub-tenon's versus retrobulbar anaesthesia in planned extracapsular cataract extraction. Inouye Eye hospital, Tokyou, Japan. *J Cataract Refract Surg.* 1999 Sep;25(9):1250-3.
17. Guise P, Larent S. Sub-Tenon's block: the effect of hyaluronidase on speed on onset and block quality *Anaesthesia intensive care* 1999 April;27(2):179.
18. Alwitry et al. Effect of hyaluronidase on ocular motility in sub-Tenon's anaesthesia randomized controlled trial. *Journal of cataract and refractive surgery* 2002 August;28(8):1420-3.
19. Karpan Z, Uyar M, Eltutar K, Dincer N. One quadrant sub-Tenon's capsule anaesthesia in anterior segment surgery. *European Journal of Ophthalmology.* 1996 April-June;6(2):131-6.
20. Merle H et al Evaluation of single injection caruncular sub-Tenon's anaesthesia *J. Fr Ophthalmol* 2002 Feb;25(2)130-4.
21. Waterman et al An evaluation of the administration of sub-Tenon's local anaesthesia by a nurse practitioner. *British journal of ophthalmology* 2002 May;86(5):524-6.
22. Katsev DA, Drews RC, Rose BT: An anatomic study of retrobulbar needle path length. *Ophthalmology* 96:1221,1989.
23. Duker JS, Belmont JB, et al. Inadvertent globe perforation during retrobulbar and peribulbar anaesthesia. *Ophthalmology* 1991;98:519-26.