

Ocular co-morbidities and management outcomes in posteriorly dislocated crystalline lens and intra ocular lens

Kalpana Badami Nagaraj¹, Roopashree Kamisetty^{2,*}

¹Professor & Head, ²Fellow, Dept. of Vitreo Retina, Minto Ophthalmic Hospital, Bangalore

***Corresponding Author:**

Email: roopachee@gmail.com

Abstract

Aim: To evaluate the associated ocular morbidity and management outcomes in posteriorly dislocated crystalline lens and intraocular lens.

Methods: A retrospective study including sixty-eight eyes of patients presenting with dislocated lens and IOLs from January 2012 to May 2014 at the retina clinic were enrolled. Associated features, surgical approaches and postoperative visual outcomes were studied.

Results: Fifty three eyes (78%) had dislocated crystalline lens, 15(22%) had dislocated IOL. Anterior segment features in lens and IOL group include sphincter tears (82%,0%), corneal edema (40%, 100%), secondary glaucoma (22%,9%), hyphaema (18%,0%), angle recession (5%,0%) vitreous in pupillary area (30%,100%), surgical wound gape (0%,13%). Posterior segment features include vitreous haemorrhage (11%,13%), rhegmatogenous retinal detachments (9%,13%), retained intraocular foreign body (1%,0%) respectively. In the lens group, Pars plana vitrectomy(PPV) + lensectomy was done in 84%, lensectomy+ anterior vitrectomy 15%, combined with trabeculectomy 1%, IOFB removal 1%. In IOL group, PPV + IOL explanation was done in all the eyes. Scleral fixated IOL was done in 30% and 80%, PPV+ silicone oil implantation in 6% and 13% eyes with RRD in the lens and IOL group respectively. At 3 months postop, best corrected visual acuity (BCVA) > 20/40 was seen in 70% eyes of lens group and 75.5% of IOL group with scleral fixated lens.

Conclusion: Ocular co-morbidities and poor visual results are more common with dislocated crystalline lens than dislocated IOLs.

Key words: Dislocated lens, Dislocated IOL, Ocular comorbidities, Management outcomes

Access this article online	
Quick Response Code:	Website: www.innovativepublication.com
	DOI: 10.5958/2395-1451.2016.00025.1

Introduction

Posterior dislocation of crystalline lens and intraocular lens (IOL) are both seen in clinical practice.^[1]

Management of these entities however needs answers to few pertinent issues: how to deal with the dislocated lens and consequent aphakia and whether to deal with other concomitantly damaged ocular structures at the same time.^[2]

Most of the published reports so far, simply emphasize the surgical techniques and visual results, and little has been written about the concomitant anterior and posterior segment abnormalities in these eyes and their management.^[3]

Hence, our primary objective in this study is to evaluate the associated ocular morbidity with these common clinical entities, the various surgical modifications and the functional outcomes of their management.

Materials and Methods

This is a retrospective study of the medical records of patients who presented to the retina clinic with complete posteriorly dislocated lenses (crystalline lens and IOLs) from January 2012 to May 2014. Inclusion criteria were all eyes with posteriorly dislocated crystalline lenses or intraocular lenses that underwent surgery. Exclusion criteria included all eyes with subluxated lenses and those with follow up less than three months.

Data noted included the demographic profile of the patients, the aetiology of luxation, the nature of trauma and the clinical presentation. Best corrected visual acuity (BCVA), details of the slit lamp bio microscopic examination, fundus evaluation by indirect ophthalmoscopy, intraocular pressure (Goldman applanation tonometer), Bscan and glaucoma evaluation details were recorded.

The types of surgery performed along with the visual outcomes were recorded. All surgeries were performed under local anaesthesia. A standard three port pars plana vitrectomy with lensectomy or IOL explantation with endolaser was the most commonly performed surgery. The pars plana vitrectomy and technique of nuclear removal conformed to the published literature.^[4] Additional procedures were done wherever necessary. In eyes without any significant concomitant ocular morbidity, a scleral fixation of intraocular lens was performed during the same surgery.

Postoperative BCVA at three months was noted. The initial BCVA after injury and the VA at final follow up were grouped in four categories: Group 1 - VA > 20/40, Group 2 - VA: 20/50 < 20/200, Group 3 - VA: 20/200 - CF, Group 4 - VA: HM- PL. Statistical analysis was done using Student- T test.

Results

Fifty-three eyes (78%) had dislocated crystalline lenses and fifteen eyes (22%) had dislocated IOLs. The mean age in lens group was 36 +/- 0.7 years (range from 16 to 45) and in IOL group was 52 +/- 0.3 years (range from 44 to 72). Majority of the patients were males, 73.5% (39 out of 53) in lens group and 62% (9 out of 15) in IOL group. The predominance in males was statistically significant with $p < 0.001$.

Aetiology of dislocation in lens and IOL group has been as shown in the Table 1.

Trauma was the most common aetiology in lens group. Blunt trauma (with club and stone) accounting for 78% (42 of 53 eyes) was much commoner than penetrating trauma seen in 6(12%) eyes. Spontaneous dislocation of lens was seen in 4(8%) eyes with pseudoexfoliation and in 1 eye (2%) with Marfans syndrome. In IOL group, 14 out of 15 eyes (93%) had complicated cataract surgery with intraoperative posterior capsular rupture as the major risk factor. Twelve of fifteen eyes (80%) presented within two months of surgery. Two of the fifteen eyes (13%) presented around seven months after surgery with trivial trauma and one eye (7%) presented eight years after surgery with blunt trauma.

The preoperative best corrected visual acuity in lens group was as follows: group 1 -7 eyes (13%), group 2- 11 (21%), group 3- 14 (27%) and group 4- 21(39%) eyes. The preoperative best corrected visual acuity in IOL group was as follows: group 1- 2 eyes (13%), group 2- 10(67%), group 3- 1(7%) and Group 4- 2(13%) eyes.

The anterior and posterior segment morbidities observed in lens and IOL groups are as shown in the table -2. Of the 53 eyes in lens group, anterior segment features noted include sphincter tears in 43 (82%), corneal edema in 21 (40%), secondary glaucoma in 11(22%), hyphaema in 10(18%), angle recession in 3(5%) eyes. Of the 15 eyes in IOL group, corneal edema and vitreous herniation in pupillary area was noted in all eyes (100%), surgical wound gape in 2(13%), and secondary glaucoma in 1(9%) eyes.

The posterior segment morbidities observed between the two groups were as follows: Vitreous

haemorrhage was seen in 6 of 53 (11%) and 2 of 15 (13%) eyes and rhegmatogenous retinal detachments seen in 4 out of 53(9%) and 2 of 15(13%) eyes, respectively in lens and IOL groups. One case (1%) of a retained intraocular foreign body with RD following trauma was noted in lens group.

The various surgical procedures done in both groups are as shown in the Table 3.

In the lens group, 45 eyes (84%) underwent pars plana vitrectomy with lensectomy and endolaser (EL), 8 eyes (15%) underwent lensectomy with anterior vitrectomy. Additional procedures done included one case (1%) combined with trabeculectomy, one case (1%) with an intraocular foreign body removal and RD repair and 3(6%) with PPV+ 240BB+EL+fluid gas exchange + silicone oil implantation. One patient following blunt trauma had an inferior giant retinal tear with a sub retinal crystalline lens. This patient underwent a three port pars plana vitrectomy during which the sub retinal location of the crystalline lens under the giant retinal tear was confirmed. The lens was maneuvered into the vitreous cavity and appropriately managed.^[5] SFIOL implantation was done in 16 of 53(30%) eyes in lens group.

In the IOL group, pars plana vitrectomy with IOL explantation and endolaser was performed in all 15(100%) eyes. Combined PPV+ 240BB+EL+fluid gas exchange + silicone oil implantation was done in 2 eyes (13%). PFCL assisted levitation was needed in 1% eyes each in both groups. SFIOL implantation was done in 12 of 15 eyes (80%).

Graph 1 shows the Comparative analysis of preop and post op BCVA in Lens group. The post-operative BCVA in lens group noted was: group 1- 24 eyes (44%), group 2-8(16%), group 3-13 (24%) and group 4- 8 (16%) eyes.

Graph 2 shows comparative analysis of preop and post op BCVA in IOL group. In IOL group, group 1 included 10 eyes (64%), group 2- 3(20%), group 3- 1(4%) and group 4- 1(12%) eyes.

Similar postop BCVA was recorded in eyes with SFIOL in both groups. In lens group with scleral fixated lens, 11 out of 16 (70%) had better than 20/40, 5 out of 16(30%) patients had VA between 20/50 < 20/200. In IOL group with scleral fixated lens, 9 out of 12(75.5%) had VA better than 20/40, 3 out of 12(24.5%) patients had VA between 20/50 < 20/200. Complications noted were decentred SFIOL in 2, hyphaema in 3 eyes in lens group, RRD after 6 months seen in 1 eye of IOL group. Patient with RRD was unwilling for further intervention.

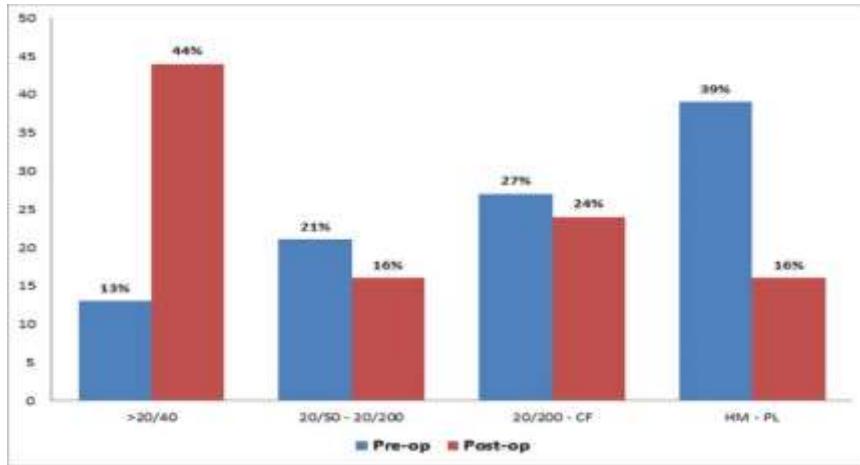


Fig. 1: Graph showing comparative pre op and post op BCVA in Lens group

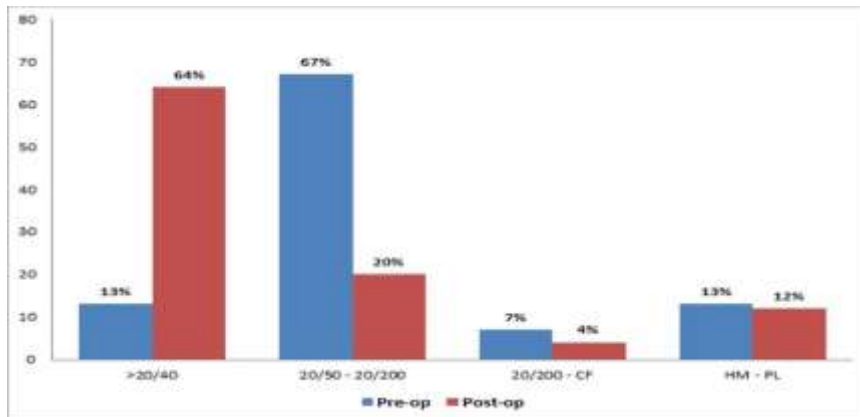


Fig. 2: Graph showing comparative pre op and post op BCVA in IOL group

Table 1: Aetiology of dislocation in Crystalline lens and IOL group

Crystalline lens group(53 eyes)	IOL group(15 eyes)
Blunt trauma (club & stone) – 42(78%)	Complicated cataract surgery with PCR – 12(80%) (within 2 months post op)
Penetrating trauma – 6(12%)	Trivial trauma with PCR – 2(13%) (within 7 months post op)
Spontaneous (pseudoexfoliation) –4(8%)	Blunt trauma – 1(7%)
Marfans syndrome – 1 (2%)	

Table 2: Comparison of the percentage of eyes with anterior and posterior segment comorbid features between Lens and IOL group

Anterior segment comorbid features	Lens group (53 eyes) (percentage of eyes)	IOL group(15 eyes) (percentage of eyes)
Corneal edema	21(40%)	15(100%)
Vitreous in pupillary area	16(30%)	15(100%)
Sphincter tears	43(82%)	-
Hyphaema	10(18%)	-
Secondary glaucoma	11(22%)	1(9%)
Surgical wound gape	-	2(13%)
Angle recession	3(5%)	-
Posterior segment comorbid features		
Vitreous haemorrhage	6(11%)	2(13%)
Rhegmatogenous retinal detachment	4(9%)	2(13%)
Retained intraocular foreign body	1(1%)	-

Table 3: Various Surgical procedures done in Lens and IOL group

Type of surgery	Lens group (53 eyes) (Percentage of eyes)	IOL group (15 eyes) (Percentage of eyes)
Pars plana vitrectomy + lensectomy (Phaco fragmatome)/ IOL explantation + endolaser	45(84%)	15(100%)
Lensectomy with anterior vitrectomy	8(15%)	-
SFIOL implantation	16(30%)	12(80%)
Combined IOFB removal+ RD repair	1(1%)	-
Combined with trabeculectomy	1(1%)	-
PPV + 240BB + EL + fluid gas exchange + Silicone oil implantation	3(6%)	2(13%)
Perfluorocarbon liquid assisted levitation	1(1%)	6(1%)

Discussion

Clinical Studies about the epidemiology and management of posteriorly dislocated lenses in our population are limited. The knowledge regarding the etiological factors and associated ocular findings in the anterior and posterior segment of the eye form part of an essential workup in cases of posteriorly dislocated lenses and IOLs.

We observed that the posterior dislocation of crystalline lens occurred more in younger patients (16 to 45) than the dislocated IOLs which frequented the older age group (44 to 72). This is explained by the fact that such eyes would have undergone surgery for cataractous lenses at an older age.

Most of the patients in the dislocated lens and IOL groups were males ($P < 0.001$). The higher rates of trauma among males that we report are consistent with other studies worldwide and are probably due to occupational hazards & their more frequent involvement in violent activities.^[6-8]

The most common aetiology of dislocated lenses was blunt trauma.^[1,9] Blunt trauma in an anteroposterior direction is believed to lead to equatorial expansion, which may disrupt the zonules and lead to lens dislocation or subluxation depending on the dominant mechanical forces of coup/countercoup resulting in luxation.^[10] We agree with the other authors that spontaneous lens dislocation can occur due to rupture of the zonular fibres as in pseudoexfoliation syndrome.^[11] Patients with Marfans syndrome may be at increased risk of lens dislocation even with minor ocular trauma.^[12]

In the posteriorly dislocated IOL group, the major risk factor observed was intraoperative posterior capsular rupture (PCR) conforming to the published data. The incidence of posterior dislocation of IOL after phacoemulsification is estimated to be between 0.3% and 1.1%^[13] and in some cases due to trauma.^[14] We also noted serious morbidities, including retinal detachment, uveitis, glaucoma, and dislocated IOLs in association with PCR^[15]. Hence steps taken to prevent PCR and vitreous prolapse preoperatively are important and effective.

A varied spectrum of anterior and posterior segment morbidities corresponding to the risk factors was observed.^[16] Ocular morbidities related to blunt trauma were seen more in the dislocated crystalline lens group when compared to the IOL group. However, the posterior segment signs were seen almost equally in both groups. Lenticular luxation secondary to ocular trauma in both open and closed globe injury subgroups can be associated with both the anterior and posterior segment sequelae such as hyphaema, iridodialysis, sphincter tears, angle recession, secondary glaucoma, cyclodialysis, vitreous haemorrhage, vitreous base avulsion, choroidal rupture, retinal dialysis and detachment.^[16] Post-traumatic lenticular luxation differs from other congenital aetiologies in being non progressive in nature, and associated with poor visual prognosis if any of the ocular co-morbidities co-exist.^[9]

Treatment of dislocated lens has improved with advances in automated vitrectomy techniques.^[17] There are many literatures about the methods to extract the dislocated lens/IOL. Standard surgical management performed varied according to the group along with the associated ocular morbidity. The choice of surgical approach is closely related to the nuclear hardness degree and the position of the dislocated lens/IOL. The technique of cataract extraction was determined by the surgeons based on their experiences and associated ocular findings. Pars plana vitrectomy (PPV) with lensectomy techniques are well suited to cases in which there is complete dislocation of the lens with an intact capsule.^[18] This technique is most commonly applied in the context of posterior segment disease to provide a better view posteriorly, allow vitreous base dissection, or treat lens-associated complications.^[19,20]

When the preoperative intraocular pressure cannot be effectively controlled after drug treatment, trabeculectomy may be combined with.^[2] The complications such as vitreous haemorrhage, retinal detachment, secondary glaucoma, iridodialysis associated with lens dislocation can be managed medically but sometimes surgery is indicated.^[21] Merani et al. report RDs occurring in a small percentage of eyes, approximately 7% of eyes having PPV for retained lens

material^[22]. We agree with Senn et al that combined surgery in selected patients is a safe and effective approach compared to sequential surgery^[23].

IOL implantation in primary surgery for posteriorly dislocated lens once was controversial.^[24] A combined procedure consisting of PPV lensectomy with IOL implantation was initially described by Blankenship et al.^[19] Subsequently, a procedure combining PPV and traditional anteriorly approached cataract removal was reported^[25]. With the improvement of technology and constant updates of equipment's, the feasibility and safety of the primary IOL implantation combined multiple operations were verified again and again.^[21] Currently the suture fixation of IOL in the ciliary sulcus is the mainstream choice of lens/IOL dislocation surgery. But primary IOL implantation should not be performed when the traumatic ocular situation is complex and intraocular situation is severe because postoperative intractable uveitis will occur more possibly in this situation.^[23]

Overall, the posteriorly dislocated IOL group fared better post-operatively compared to the dislocated lens group. Possibly, pre-operative variables, in the dislocated lens group, such as pre-operative visual acuity, hyphaema and glaucoma appeared to adversely affect the final vision outcome. In our opinion the early presentation (within two months of surgery) and the less associated anterior segment ocular morbidity contributed to better functional outcome in the IOL group. Another explanation could be that more eyes in the IOL group underwent SFIOL implantation. There was no significant change in the BCVA in eyes with SFIOL among the two groups. This could be explained by the fact that SFIOL implantation was done in eyes without significant ocular morbidity.

In general, the visual prognosis after PPV lensectomy for dislocated lens or IOL was generally favourable in our study; a final visual acuity of 20/40 or better was obtained in mean 73% of eyes of both groups in our study. This is comparable to the series reported by Chaudhry et al, in which a final visual acuity of 20/40 or better was obtained in 46% of eyes.^[20] Craig et al found in 55% eyes in their study.^[3] Fewer but significant postoperative complications like IOL decentration, retinal detachment and vitreous haemorrhage were also noted by Mutoh et al.^[26]

As a retrospective study, there was no uniform method of management, either at presentation or during surgery. Indeed, the spectrum of ocular trauma is such that there is no optimal method of management.^[3] It is therefore essential to identify the clinical profile of patients with lenticular luxation in order to contain such insults in future and to devise an appropriate management plan.^[9]

In short, the particularity of each case should be fully considered to treat posteriorly dislocated crystalline lens or IOL, associated with anterior and posterior co morbid features, and is the key point to choose

reasonable operation time and accordingly the surgical techniques to obtain better effect to improve the visual acuity and reduce the complications of the operation.

Limitations in our study are its retrospective nature and relatively small size. The reasons that prompted our study were the higher number of patients with dislocated lenses and IOLs at our tertiary referral centre. We also needed to analyse the reasons for the more favourable outcomes in cases with dislocated IOLs. However, the disparity in the number of eyes and the two groups being two entirely distinct entities precludes a valid comparison between them, despite our observations, this being another limitation of our study.

Conclusion

Ocular co-morbidities and poor visual results are more common with dislocated crystalline lens than dislocated IOLs. Visual outcomes are better with scleral fixated lenses in both the groups. However, additional surgical procedures may be required to deal with the co-morbidities for good prognosis in such cases.

References

1. Jarrett WH. Dislocation of the lens. A study of 166 hospitalized cases. *Arch ophthalmol* 1967;78:289-96.
2. Wang R, Bi CC, Lei CL, Sun WT, Wang SS, Dong XJ. Multiple methods of surgical treatment combined with primary IOL implantation on traumatic lens subluxation/dislocation in patients with secondary glaucoma. *Int J Ophthalmol* 2014;7:264-72.
3. Greven CM, Collins AS, Slusher MM, Weaver RG. Visual results, prognostic indicators, and posterior segment findings following surgery for cataract/lens subluxation-dislocation secondary to ocular contusion injuries. *Retina* 2002;22:575-80.
4. Charles S. Principles and techniques of vitreous surgery. In: Ryan SJ, editor. *Retina. Vol3: Surgical Retina*. 2nd ed. St. Louis, USA: CV Mosby; 1994. p.2063-92.
5. Nagaraj BN, Tirumale S, Sriprakash KS, Savitha CS, Jaydev C. Sub retinal crystalline lens – an unusual complication of blunt trauma. *Asian JO* 2013;13:68-70.
6. Schein OD, Hibberd PL, Shingleton BJ, et al. The spectrum and burden of ocular injury. *Ophthalmology* 1988;95:300-5.
7. McCarty CA, Fu CL, Taylor HR. Epidemiology of ocular trauma in Australia. *Ophthalmology* 1999;106:1847-52.
8. Nirmalan PK, Katz J, Tielsch JM, Robin AL, Thulasiraj RD, Krishnadas R et al. Ocular Trauma in a Rural South Indian Population- The Aravind Comprehensive Eye Survey. *Ophthalmology* 2004;111:1778-81.
9. Khokhar S, Agrawal S, Gupta S, Gogia V, Agarwal T. Epidemiology of traumatic lenticular subluxation in India. *Int Ophthalmol* 2014;34:197-204.
10. Shingleton BJ, Hersh PS, Kenyon KR. Eye trauma. In: Mosby-year book, 1991, The University of Michigan, 15 Aug 2008, p 427.
11. Hayashi K, Hirata A, Hayashi H. Possible predisposing factors for in-the bag and out-of-the-bag intraocular lens dislocation and outcomes of intraocular lens exchange surgery. *Ophthalmology* 2007;114:969-75.
12. Izadi S, Stewart RMK, Jain S. Bilateral posterior dislocation of the crystalline lens after a head injury sustained during a seizure. *Emerg Med J* 2007;24:1.

13. Pande M, Dabbs TR. Incidence of lens matter dislocation during phacoemulsification. *J Cataract Refract Surg* 1996;22:737–42.
14. Zech JC, Tanniere P, Denis P, Tresat C. Posterior chamber intraocular lens dislocation with the bag. *J Cataract Refract Surg* 1999;25:1168–69.
15. Chen M, LaMattina KC, Patrianakos T, Dwarakanathan S. Complication rate of posterior capsule rupture with vitreous loss during phacoemulsification at a Hawaiian cataract surgical centre: a clinical audit. *Clin Ophthalmol* 2014;8:375–78.
16. Viestenz A, Ku`chle M. Blunt ocular trauma. Part I: blunt anterior segment trauma. *Ophthalmologie* 2004;101:1239–57.
17. Marcus DM, Topping TM, Frederick AR Jr. Vitreoretinal management of traumatic dislocation crystalline lens. *Int Ophthalmol Clin* 1995;35:139–50.
18. Oh J, Smiddy WE. Pars plana lensectomy combined with pars plana vitrectomy for dislocated cataract. *J Cataract Refract Surg* 2010;36:1189–94.
19. Blankenship GW, Flynn HW Jr, Kokame GT. Posterior chamber intraocular lens insertion during pars plana lensectomy and vitrectomy for complications of proliferative diabetic retinopathy. *Am J Ophthalmol* 1989;108:1–5.
20. Chaudhry NA, Belfort A, Flynn HW Jr, Tabandeh H, Smiddy WE, Murray TG. Combined lensectomy, vitrectomy and scleral fixation of intraocular lens implant after closed-globe injury. *Ophthalmic Surg Lasers* 1999;30:375–81.
21. Lam DS, Chua JK, Kwok AK, Wong AK, Leung AT, Fan DS *et al.* Combined surgery for severe eye disease with extensive iridodialysis, posterior lens dislocation and intractable glaucoma. *J Cataract Refract Surg* 1999;25:285–88.
22. Merani R, Hunyor AP, Playfair TJ, Chang A, Gregory-Roberts J, Hunyor AB *et al.* Pars plana vitrectomy for the management of retained lens material after cataract surgery. *Am J Ophthalmol* 2007;144:364–70.
23. Senn P, Schipper I, Perren B. Combined pars plana vitrectomy, phacoemulsification, and intraocular lens implantation in the capsular bag: a comparison to vitrectomy and subsequent cataract surgery as a two-step procedure. *Ophthalmic Surg Lasers* 1995;26:420–28.
24. Foster RE, Lowder CY, Meisler DM, Zakov ZN, Meyers SM, Ambler JS. Combined extra capsular cataract extraction, posterior chamber intraocular lens implantation, and pars plana vitrectomy. *Ophthalmic Surg* 1993;24:446–52.
25. Douglas MJ, Scott IU, Flynn HW Jr. Pars plana lensectomy, pars plana vitrectomy and silicone oil tamponade as initial management of cataract and combined traction/rhegmatogenous retinal detachment involving the macula associated with severe proliferative diabetic retinopathy. *Ophthalmic Surg Lasers Imaging* 2003;34:270–8.
26. Mutoh T, Matsumoto Y, Chikuda M. Use of pars plana vitrectomy with phacoemulsification in vitreous cavity to treat complete posterior dislocation of lens. *Clin Ophthalmol* 2011;5:937–40.