

Content available at: <https://www.ipinnovative.com/open-access-journals>

Indian Journal of Clinical and Experimental Ophthalmology

Journal homepage: [www.ijceo.org](http://www.ijceo.org)

## Original Research Article

# Comparison of corneal ulcer size and depth measurement by slit lamp and anterior segment optical coherence tomography

Alok Sharma<sup>1\*</sup>, Arun Kumar Singh<sup>1</sup>, Alka Gupta<sup>1</sup>, Kumudini Sharma<sup>1</sup>,  
Rajendra Prakash Maurya<sup>2</sup>, Deepti Gangwar<sup>1</sup>

<sup>1</sup>Dept. of Ophthalmology, Hind Institute of Medical Sciences., Barabanki, Uttar Pradesh, India

<sup>2</sup>Regional Institute of Ophthalmology, Institute of Medical Sciences, Banaras Hindu University, Varanasi, Uttar Pradesh, India



## ARTICLE INFO

## Article history:

Received 20-08-2024

Accepted 14-09-2024

Available online 30-09-2024

## Keywords:

Corneal ulcer

SLIT LAMP biomicroscopy

Optical coherence tomography

Corneal thickness

Anterior segment-optical coherence tomography

## ABSTRACT

**Objective:** To evaluate the correlation between corneal ulcer size and depth measurements using slit lamp biomicroscopy and anterior segment optical coherence tomography (AS-OCT).

**Materials and Methods:** A prospective, observational study was conducted on 100 patients with corneal ulcers at the Hind Institute of Medical Sciences after taking clearance from the ethical committee. Corneal ulcer parameters, including width, height, and depth, were measured and compared using both slit lamp biomicroscopy and AS-OCT.

**Results:** The mean age of patients was  $45.74 \pm 13.61$  years ranging from 22 to 78 years. Majority of patients were males (75%). Right eye was involved among more than half of patients (65%) followed by left eye (35%). The length and depth of infiltrate was significantly ( $p=0.001$ ) lower by SLIT LAMP than ASOCT method observed by both the observers. The breadth of infiltrate was significantly ( $p<0.05$ ) higher by SLIT LAMP than ASOCT method observed by both the observers. Corneal thickness measured by ASOCT was significantly ( $p=0.04$ ) lower evaluated by observer 1 ( $637.76 \pm 135.26$ ) than observer 2 ( $640.66 \pm 130.16$ ). Highly significant positive ( $p=0.0001$ ) correlation was found between SLIT and ASOCT in all the measurements evaluated by both the observers.

**Conclusion:** AS-OCT provides accurate and non-invasive measurements of corneal ulcer depth, which is not possible with slit lamp biomicroscopy. The use of AS-OCT as an adjunctive modality can enhance diagnosis and management of corneal ulcers. This study highlights the utility of AS-OCT in monitoring disease activity and providing valuable imaging guidelines for clinicians.

This is an Open Access (OA) journal, and articles are distributed under the terms of the [Creative Commons Attribution-NonCommercial-ShareAlike 4.0 License](https://creativecommons.org/licenses/by-nc-sa/4.0/), which allows others to remix, tweak, and build upon the work non-commercially, as long as appropriate credit is given and the new creations are licensed under the identical terms.

For reprints contact: [reprint@ipinnovative.com](mailto:reprint@ipinnovative.com)

## 1. Introduction

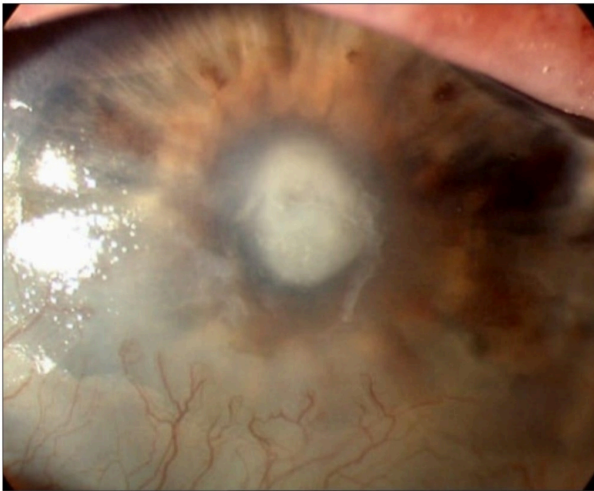
A corneal ulcer is defined as disruption in outer layer of cornea affecting the stroma beneath, poses a significant threat to vision and is contemplated an ocular emergency.<sup>1</sup> Even with prompt treatment, the patient may experience severe morbidity, such as anterior and posterior synechiae, corneal scarring or perforation, cataract, glaucoma and impairment of vision. If left untreated, infectious keratitis

can lead to endophthalmitis and even blindness.<sup>2</sup> In the US, the annual prevalence of corneal ulcers is anticipated to be beyond tens of thousands, with approximately 12.2% of corneal transplants performed to manage infectious keratitis.<sup>3</sup>

Corneal ulceration, may resolve without medical intervention, or may progress to perforation with serious consequences, or result in an opacity that can lead to vision loss if focal. The chronicity of is influenced by a combination of factors, including geographic and regional aspects, the level of development of the country, prevalent

\* Corresponding author.

E-mail address: [alokdixit2692@gmail.com](mailto:alokdixit2692@gmail.com) (A. Sharma).



**Figure 1:**

influencing factors, and the types of infections often found in the community.<sup>4,5</sup>

Accurate measurement of corneal ulcers is essential for diagnosing the severity of the condition, monitoring progression, and assessing the efficacy of treatments. Traditionally, slit lamp biomicroscopy has been the primary method used by ophthalmologists for evaluating corneal ulcers. However, it has limitations, particularly in terms of accuracy and reproducibility. Measurements obtained from slit lamp examinations can vary significantly between different observers due to the subjective nature of the evaluation. Newer imaging approaches including Optical coherence tomography (OCT) has demonstrated a great deal of promise for utilization. It has revolutionized clinical and surgical treatment of the cornea by improving understanding of corneal pathology. A non-contact, in vivo ocular imaging technology called AS-OCT uses low-coherence interferometry to determine the echo time lag of light scattered back from tissue organization. It combines numerous axial scans to create a composite B-scan picture.<sup>6</sup>

A number of corneal diseases have been studied by AS-OCT, including keratitis, ectatic disorders, corneal dystrophies and degenerations, and ocular surface disorders. Additionally, it is helpful for ocular trauma, keratoplasty, and refractive surgery's planning prior to surgery and during recovery. Although the Principal diagnosis of these conditions is clinical, AS-OCT is beneficial in cases with subtle or subclinical trait. Additionally, OCT can quantify corneal changes, aiding in the grading of disease graveness and keeping track of progression.<sup>6</sup>

This study aimed to explore the correlation between the size and depth of corneal ulcers measurements utilizing SLIT LAMP and Anterior Segment Optical Coherence Tomography.

## 2. Materials and Methods

A hospital-based, prospective, non-randomized, observational clinical study conducted in the Department of Ophthalmology at Hind Institute of Medical Sciences, Safedabad, Uttar Pradesh over the duration of 18 months.

After taking clearance from ethical committee, 100 subjects were recruited & written informed consent were obtained.

### 2.1. Inclusion criteria

1. New diagnosed cases of corneal ulcer that occurred before corneal scraping.
2. Corneal ulcers of diverse sizes.
3. Patients willing to participate in the study.
4. Aged 16 years and above till

### 2.2. Exclusion criteria

1. Perforated ulcers.
2. Ulcers with impending perforation.
3. Total corneal ulcers.
4. Non-infective ulcers such as Mooren's ulcer and Shield's ulcer.
5. Past corneal surgery performed on the affected eye.
6. Acuity of vision less than 3/60.
7. Patients with ages under 16.
8. Women who are expecting.
9. Patients who refuse to participate.

### 2.3. Sample Size

100 subjects recruited for the study.

Formula:

Adequate sample size was calculated by using the formula

$$N = Z^2 \alpha p (1-p) / E^2$$

Where, p – Proportion or prevalence or incidence

Z $\alpha$  - Critical value of standard normal variate at  $\alpha$  level of significance

E- Margin of error or Allowable error

E- 10% = 0.1 (Absolute margin of Error)

$$n - (1.96)^2 \times 0.468 (1-0.468) / (0.1)^2 = 95.6$$

N = 96 (Sample Size)

Thus total sample size taken as 100.

### 2.4. Methodology

The patient was recruited from Ophthalmology OPD, Hind hospital. After documenting the detailed history and ocular examination of the patient, the following clinical examination steps were taken-

1. Visual Acuity (UCVA) using Snellen's chart at 6 mts
2. Corneal ulcer was initially evaluated n slit lamp Biomicroscopy, prior and post staining with

Fluorescein dye, before the corneal scraping, and the findings were measured.

3. Following slit lamp evaluation, the ulcer size was measured using Appasamy SD-OCT.
4. Parameters were measured and the final value was considered for the interpretation of the results.
5. The parameters measured in the anterior segment OCT were maximum vertical diameter (length), maximum horizontal diameter (breadth), depth of the infiltrate and corneal thickness at the point of maximum infiltration.

2.5. Data collection

1. Individual interviews and thorough ocular evaluations of the individual were used to collect the principal data in accordance with the study protocol.
2. A thorough database was then created by entering the gathered data into Microsoft Excel sheet.
3. To compare with the principal data, secondary data were also obtained from a variety of publications and papers, PubMed, and Cochrane.

2.6. Statistical analysis

Results were analyzed as frequencies, percentages, and mean ± SD. The Paired t-test was used to compare continuous variables. The Pearson correlation coefficient was calculated. A p-value of less than 0.05 was contemplated significant. All analyses were performed availing SPSS version 16.0 (Chicago, Inc., USA). The statistical Analysis was done using SPSS (Statistical Package for Social Science) Version 16.0 Statistica Analysis Software. The values were represented in Number (%) and Mean ± SD.

3. Results

This study set out to compare the reliability of slit lamp evaluation and indigenous anterior segment optical coherence tomography in determining the size and depth of corneal ulcers at the Hind Institute of Medical Sciences' Department of Ophthalmology. In all, 100 patients were enrolled in the research.

More than one third of patients were between 51-60 years of age (37%), 41-50 (23%), <30 (22%) and 30-40 & >60 (9%) years. The mean age of patients was 45.74±13.61 years ranging from 22 to 78 years. Majority of patients were males (75%). Right eye was involved among more than half of patients (65%) followed by left eye (35%). (Table 1)

The length of infiltrate was remarkably (p=0.001) lower by SLIT LAMP than ASOCT method observed by both the observers. The breadth of infiltrate was remarkably (p<0.05) higher by SLIT LAMP than ASOCT method observed by both the observers. The depth of infiltrate was remarkably (p=0.001) lower by SLIT LAMP than ASOCT method observed by both the observers. No significant (p>0.05)

difference was seen in the measurement of length, breadth and depth of infiltrate by SLIT LAMP and ASOCT methods between both the observers. (Table 2)

Corneal thickness measured by ASOCT was remarkably (p=0.04) lower evaluated by observer 1 (637.76±135.26) than observer 2 (640.66±130.16). (Table 3) Highly significant positive (p=0.0001) correlation was found between SLIT and ASOCT in all the measurements evaluated by both the observers. (Table 4)

**Table 1:** Patient's distribution as per age, gender, eye involvement and diabetes mellitus status

	No. (n=100)	%	
<b>Age in years</b>	<30	22	22.0
	30-40	9	9.0
	41-50	23	23.0
	51-60	37	37.0
	>60	9	9.0
	Mean±SD	45.74±13.61	
	(Range)	(22-78)	
<b>Gender</b>	Male	75	75.0%
	Female	25	25.0%
<b>Eye involved</b>	Left	35	35.0%
	right	65	65.0%

**Table 3:** Comparison of corneal thickness between observer 1 and 2 by ASOCT

	Corneal thickness (Mean±SD)
Observer 1	637.76±135.26
Observer 2	640.66±130.16
p-value <sup>1</sup>	0.04*

4. Discussion

An essential component of ocular examination is the assessment of the anterior segment. Traditionally, a slit lamp and gonioscope are used to assess the anterior segment and iridocorneal angle. Technology progressed to the point that low coherence interferometry was created, which served as the foundation for optical coherence tomography (OCT). OCT offers several fine-grained cross-sectional pictures of biological tissue's interior architecture. OCT has gained notoriety as a vital tool for the diagnosis and treatment of several corneal and anterior segment conditions, delivering a thorough assessment in a safe and non-contact manner. At present there are two anterior segment (AS-OCT) models in the market the slit-lamp OCT and the Visante OCT. Non-invasive investigation of the anatomy and the diseases of the Anterior segment have been made feasible since the availability of these two models.<sup>7</sup>

According to Shousha MA et al (2013)<sup>8</sup> there is a strong agreement between the results of histology and AS-OCT in cases with ocular surface lesions, suggesting that AS-OCT probably be put to be used as an additional

**Table 2:** Comparison of length of infiltrate, breadth of infiltrate and depth of infiltrate between SLIT LAMP and ASOCT

		SLIT LAMP	ASOCT	p-value <sup>1</sup>
Length of infiltrate	Observer 1	4.08±2.27	4.27±2.06	0.001*
	Observer 2	4.08±2.27	4.24±2.07	0.001*
	p-value <sup>1</sup>	1.00	0.09	
Breadth of infiltrate	Observer 1	7.52±0.86	7.44±0.59	0.02
	Observer 2	7.51±0.87	7.45±0.55	0.03
	p-value <sup>1</sup>	0.92	0.08	
Depth of infiltrate (%)	Observer 1	29.01±12.04	33.14±13.62	0.001
	Observer 2	29.56±11.59	33.77±13.73	0.001
	p-value <sup>1</sup>	0.15	0.06	

**Table 4:** Correlation of various measurements between SLIT LAMP and ASOCT

	Observer 1		Observer 2	
	Correlation coefficient	p-value <sup>1</sup>	Correlation coefficient	p-value <sup>1</sup>
Length of infiltrate	0.97	0.0001*	0.97	0.0001*
Breadth of infiltrate	0.97	0.0001*	0.79	0.0001*
Depth of infiltrate	0.96	0.0001*	0.92	0.0001*

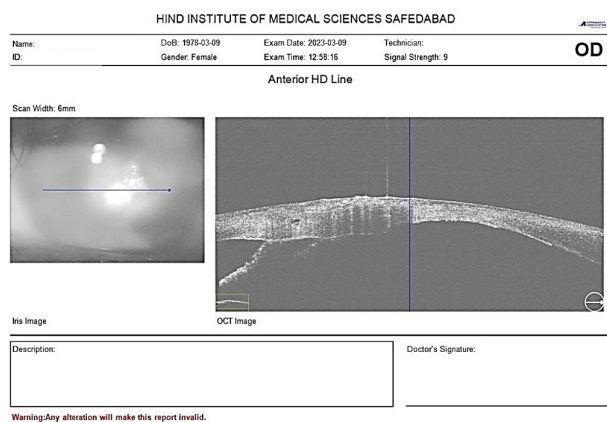
examining instrument. Histological diagnosis is difficult to obtain in patients with peripheral ulcerative keratitis (PUK) (Ladas and Mondino, 2000).<sup>9</sup> With a resolution of 1um/pixel, confocal microscopy may also be useful for studying epithelial cells and stromal keratocytes since it may provide pictures similar to those obtained from histochemical approaches (Hernandez-Quintela E et al, 1998).<sup>10</sup>

Above one-third of the patients in this research were between the ages of 51 and 60 (37%), followed by those between the ages of 41 and 50 (23%), <30 (22%) and 30-40 & above 60 (9%). Patients varied ranging in age from 22 to 78 years, with a 45.74±13.61 year mean. The age range of the patients in the Konstantopoulos A et al (2011) 11 study was 21 to 80 years old, with a mean age of 48.4. In a follow-up study, Uyar E et al. (2022) 12 discovered that the mean age was 35.8±11.0 years. Bonnet C et al. (2020)<sup>13</sup> report that the patients' ages ranged from 33 to 74 years old, with a mean diagnostic age of 50.3 sd 14.7 years. According to Tawfeek M et al (2023),<sup>11</sup> the mean age of the patients was 42.8 sd 8.35years.

Majority of patients were males (75%) in the current study while as the study done by Konstantopoulos A et al(2011)<sup>12</sup> found that half of patients were males (50%), Uyar E et al (2022)<sup>13</sup> reported that out of 63 patients, 96.8% of the patients were men. In the study by Bonnet C et al (2020),<sup>14</sup> out of 6 eyes of 6 patients, there were 4 women (66.7%) and two men (33.3%). of the 17 patients who were included in the Chaturvedi I et al (2021),<sup>15</sup> 11 were female and 6 were male this study found that right eye was involved among more than half of patients (65%) followed by left eye (35%). Similar to the attending study, Konstantopoulos A et al (2011)<sup>12</sup> also found that right side eye was involved among more than half of patients (69.2%).

In the current study, the breadth of infiltrate was notably (p<0.05) higher by SLIT LAMP than ASOCT method observed by both the observers. When measuring the breadth of infiltration using the SLIT LAMP and ASOCT techniques, there was no significant difference (p>0.05) observed between the two observers. The SLIT LAMP method significantly (p=0.001) reduced the infiltration depth compared to the ASOCT method that both observers noticed. The depth of infiltrate was notably (p=0.001) lower by SLIT LAMP than ASOCT method observed by both the observers. There was no significant (p>0.05) dissimilarity in the measurement of depth of infiltrate by SLIT LAMP and ASOCT methods between both the observers. According to AS-OCT measurements, the mean depth and breadth of the corneal wounds in the study by Uyar E et al (2022)<sup>13</sup> were 117.0+/-42.5 and 332.9+/-99.4um, respectively. 18.9+/-6.1% was the mean percentage of corneal wound depth. Over the course of the two months, it was noted that in 20 patients who showed up for follow-up, the diameter of the incision widened and the thinnest stromal thickness at the wound site shrank. According to Patel TP et al (2018)<sup>16</sup> the interobserver consistency (ICC) of ophthalmologists measurements with SL calipers ranged from 0.84 to 0.88. The ICC range for SAS measurements was 0.96-0.98. According to Parikh PC et al (2017),<sup>17</sup> cornea specialists measured epithelial abnormalities in controlled, artificial setting with high reproducibility. In a non-trivial number of instances (31% to 52%), cornea experts disagreed in measuring length by >0.5mm, regardless of the method used.

This study found that corneal thickness measured by ASOCT was notably (p=0.04) lower evaluated by observer 1 (637.76±135.26) than observer 2 (640.66±130.16). In the attending study, there was high significant positive



**Figure 2:**

( $p=0.0001$ ) correlation between SLIT and ASOCT in all the measurements evaluated by both the observers. The mean IT and mean CT in the infiltrated region were both thickest at attendation (710.88 $\mu$ m and 288.76 $\mu$ m respectively), according to Chaturvedi I et al (2021).<sup>15</sup> On days 3, 7, 14, 28 and 6 weeks, the mean CT shrank to 665.12 $\mu$ m, 650.24 $\mu$ m, 584.35 $\mu$ m, 549 $\mu$ m, and 507.47 $\mu$ m in that order. In a similar study, the mean IT dropped to 154.82 $\mu$ m, 197 $\mu$ m, 244.41 $\mu$ m and 287.24 $\mu$ m. The study concluded that AS-OCT might display the morphological traits of infectious keratitis and provide a quantitative evaluation at each subsequent visit. Bonnet C et al (2020)<sup>14</sup> reported that the mean total CT at when the patient came at last follow up was significantly thicker (509 $\pm$ 147 $\mu$ m) on AS-OCT than it was at the outset (408 $\pm$ 131 $\mu$ m;  $P=0.03$ ). The mean stromal thickness did not differ statistically (433 $\pm$ 130 $\mu$ m at the final follow-up vs. 399 $\pm$ 126 $\mu$ m at commencement,  $P=0.62$ ) when measured at the thinnest point, the epithelium was sometimes non-existent owing to an epithelial defect, hence the epithelial thickness was often not quantifiable at start.

Hsiao CH et al (2011)<sup>18</sup> discovered that in a single instance of *Alternaria* Keratitis, the central corneal thickness dropped from 584 $\mu$ m to 532 $\mu$ m in the only quantitative investigation on fungal keratitis. According to Chaturvedi I et al. (2021),<sup>15</sup> after three days after beginning therapy, there was a drop in CT in eight instances and andecrease in IT in eleven cases out of 13 cases of fungal keratitis.

The total daily decrease in CT and IT of Fungal Keratitis was 1.09% ( $p<0.0001$ ) and 0.67% ( $p<0.0001$ ) over the course of six weeks. In two instances of disciform keratitis Hsiao CH et al (2011)<sup>18</sup> discovered that in a single instance of *Alternaria* Keratitis, the central corneal thickness dropped from 584 $\mu$ m to 532 $\mu$ m in the only quantitative investigation on fungal keratitis. According to Chaturvedi I et al (2021),<sup>15</sup> after three days after beginning therapy, there was a drop in CT in eight instances and decrease in IT in eleven cases out of 13 cases of fungal keratitis.

The study population was limited to a specific geographic area, potentially impacting the applicability of results to

broader populations. Some processes in the study still rely on manual input, which may introduce variability and human error.

## 5. Conclusion

This study showed the length and depth of infiltrate was significantly lower by SLIT LAMP than ASOCT method however the breadth of the infiltrate measured was higher by SLIT LAMP than AS-OCT. The overall corneal thickness measured was also found to be high when measured with AS-OCT. AS-OCT provides accurate and non-invasive measurements of corneal ulcer depth, which is not possible with slit lamp biomicroscopy. The use of AS-OCT as an adjunctive modality can enhance diagnosis and management of corneal ulcers. This study highlights the utility of AS-OCT in monitoring disease activity and providing valuable imaging guidelines for clinicians.

## 6. Source of Funding

None.

## 7. Conflict of Interest

None.


## References

- Ahmed F, House RJ, Feldman BH. Corneal Abrasions and Corneal Foreign Bodies. *Prim Care*. 2015;42(3):363–75.
- Lin A, Rhee MK, Akpek EK, Amescua G, Farid M, Garcia-Ferrer FJ, et al. Bacterial Keratitis Preferred Practice Pattern. *Ophthalmology*. 2019;126(1):1–55.
- Sharma S. Keratitis. *Biosci Rep*. 2001;21(4):419–44.
- Ibrahim YW, Boase DL, Cree IA. Factors affecting the epidemiology of *Acanthamoeba* keratitis. *Ophthalmic Epidemiol*. 2007;14(2):53–60.
- Bharathi MJ, Ramakrishnan R, Meenakshi R, Shivakumar C, Raj DL. Analysis of the risk factors influencing to fungal, bacterial & *Acanthamoeba* keratitis in south India. *Indian J Med Res*. 2009;130:749–57.
- Gupta N, Varshney A, Ramappa M, Basu S, Romano V, Acharya M, et al. Role of AS-OCT in Managing Corneal Disorders. *Diagnosics*. 2022;12(4):918.
- Li H, Jhanji V, Dorairaj S, Liu A, Lam DS, Leung CK. Anterior Segment Optical Coherence Tomography and its Clinical Applications in Glaucoma. *J Curr Glaucoma Pract*. 2012;6(2):68–74.
- Shousha MA, Karp CL, Canto AP, Hodson K, Oellers P, Kao AA, et al. Diagnosis of ocular surface lesions using ultra-high-resolution optical coherence tomography. *Ophthalmology*. 2013;120(5):883–91.
- Ladas JG, Mondino BJ. Systemic disorders associated with peripheral corneal ulceration. *Curr Opin Ophthalmol*. 2000;11(6):468–71.
- Hernández-Quintela E, Mayer F, Dighiero P, Briat B, Savoldelli M, Legeais JM. Confocal microscopy of cystic disorders of the corneal epithelium. *Ophthalmology*. 1998;105(4):631–6.
- Tawfeek M, Fouda S, Shahien E, Atia M. Correlation between slit lamp (SL) examination and anterior segment optical coherence tomography (AS-OCT) for the evaluation of central infectious corneal perforation. *Zagazig Univ Med J*. 2023;29(4):1051–8.
- Konstantopoulos A, Yadegarfar G, Fievez M, Anderson DF, Hossain P. In vivo quantification of bacterial keratitis with optical coherence tomography. *Invest Ophthalmol Vis Sci*. 2011;52(2):1093–7.


13. Uyar E, Saribaş F. Evaluating Depth and Width of Corneal Wounds Using Anterior Segment Optical Coherence Tomography After Foreign Body Removal. *Semin Ophthalmol*. 2022;37(6):774–9.
14. Bonnet C, Debillon L, Al-Hashimi S, Hoogewoud F, Monnet D, Bourges JL, et al. Anterior segment optical coherence tomography imaging in peripheral ulcerative keratitis, a corneal structural description. *BMC Ophthalmol*. 2020;20:205.
15. Chaturvedi I, Singh K, Rana J, Dwivedi K, Sachan R. Role of anterior segment optical coherence tomography in the evaluation of microbial keratitis. *Indian J Clin Exp Ophthalmol*. 2021;7(3):548–53.
16. Patel TP, Prajna NV, Farsi S, Valikodath N, Niziol LM, Dudeja L. 2017.
17. Parikh PC, Valikodath N, Estopinal CB, Shtein RM, Sugar A, Niziol LM. 2017.
18. Hsiao CH, Yeh LK, Chen HC, Lin HC, Phil, David. Clinical Characteristics of Alternaria Keratitis. *Journal of ophthalmology*. 2014;2014:1–7.


### Author biography


**Alok Sharma**, PG Resident  <https://orcid.org/0009-0006-9528-2136>

**Arun Kumar Singh**, Associate Professor  <https://orcid.org/0009-0007-3151-9349>

**Alka Gupta**, Assistant Professor  <https://orcid.org/0009-0006-0352-8961>

**Kumudini Sharma**, Professor and Head  <https://orcid.org/0000-0003-4206-5462>

**Rajendra Prakash Maurya**, Professor  <https://orcid.org/0000-0001-9343-6003>

**Deepthi Gangwar**, PG Resident  <https://orcid.org/0009-0006-4701-5287>

**Cite this article:** Sharma A, Singh AK, Gupta A, Sharma K, Maurya RP, Gangwar D. Comparison of corneal ulcer size and depth measurement by slit lamp and anterior segment optical coherence tomography. *Indian J Clin Exp Ophthalmol* 2024;10(3):464–469.