

Content available at: <https://www.ipinnovative.com/open-access-journals>

Indian Journal of Clinical and Experimental Ophthalmology

Journal homepage: [www.ijceo.org](http://www.ijceo.org)

## Original Research Article

## Efficacy of topical autologous serum versus preservative free artificial tears in patients having isotretinoin induced dry eye diseases

Snigdha Sen<sup>1</sup>, Himanshu K Yadav<sup>2</sup>, Anu Jain<sup>1</sup>, Ila Tripathi<sup>3\*</sup>, Yatendra Chahar<sup>4</sup>, Rajendra Prakash Maurya<sup>5</sup><sup>1</sup>Dept. of Ophthalmology, S N Medical College, Agra, Uttar Pradesh, India<sup>2</sup>Dept. of Ophthalmology, Government Medical College, Saharanpur, Uttar Pradesh, India<sup>3</sup>Dept. of Ophthalmology, Autonomous State Medical College, Kanpur, Uttar Pradesh, India<sup>4</sup>Dept. of Dermatology, S N Medical College, Agra, Uttar Pradesh, India<sup>5</sup>Regional Institute of Ophthalmology, IMS, BHU, Varanasi, Uttar Pradesh, India

## ARTICLE INFO

## Article history:

Received 16-08-2024

Accepted 14-09-2024

Available online 30-09-2024

## Keywords:

Acne vulgaris

Preservative free artificial tears

Autologous serum

Dry eye

Isotretinoin

## ABSTRACT

**Aims:** Aim of this study was to compare the efficacy and safety of topical autologous serum versus preservative free artificial tears in management of systemic Isotretinoin induced dry eye**Materials and Methods:** In this prospective observational analytical study a total of 182 eyes of 97 patients with systemic Isotretinoin induced dry eye were enrolled. Baseline evaluations including the ocular surface disease index (OSDI) scoring, Schirmer's test, tear film break up time (TBUT) and National Eye Institute (NEI) grading for corneal and conjunctival staining were performed. All study subject were underwent thorough ophthalmic examinations including best-corrected visual acuity (BCVA) assessments and intraocular pressure measurements. The study participants were divided into two groups: group I treated with 40% autologous serum (AS) and group II treated with preservative free artificial tears (PFAT). Follow-up evaluation were conducted at 15 days, 1 month, 2 months, and 3 months. Statistical Analysis: The results were analyzed using the Chi-square test and t-test. P<0.05 was considered statistically significant.**Result:** After 3 months of treatment, a significant improvement was noticed in OSDI, Schirmer's test, TBUT, and NEI Scoring in both AS and PFAT groups but improvement was found stronger in AS group as compared to PFAT group (p < 0.001).**Conclusion:** Topical autologous serum may be an effective alternative for treatment of dry eye condition caused by drug Isotretinoin.This is an Open Access (OA) journal, and articles are distributed under the terms of the [Creative Commons Attribution-NonCommercial-ShareAlike 4.0 License](https://creativecommons.org/licenses/by-nc-sa/4.0/), which allows others to remix, tweak, and build upon the work non-commercially, as long as appropriate credit is given and the new creations are licensed under the identical terms.For reprints contact: [reprint@ipinnovative.com](mailto:reprint@ipinnovative.com)

## 1. Introduction

Acne vulgaris is a commonly prevalent chronic skin condition affecting about 85% of teenagers and about two-thirds of adults aged 18 years or more, globally.<sup>1</sup> Since, nearly half of India's population falls within this age range, the prevalence of acne is considerably high. This inflammatory disorder of the sebaceous glands

mainly presents with facial seborrhea, comedones, papules, pustules, nodules, pseudocysts and scarring, in severe forms.<sup>1</sup> In India, the average age of onset for acne has been reported as 24.64 years.<sup>2</sup> Various treatment options are available for acne vulgaris, including cleansers, moisturizers, Adapalene, Benzoyl Peroxide, antibiotics like clindamycin, and Retinoids. Retinoids are compounds that include natural and synthetic forms of vitamin A (such as retinol, retinal, and retinoic acid) and their derivatives.<sup>3</sup> A form of 13-cis retinoic acid, Isotretinoin is a form of 13-

\* Corresponding author.

E-mail address: [ilatipathi96956@gmail.com](mailto:ilatipathi96956@gmail.com) (I. Tripathi).

cis retinoic acid, was approved by the US Food and Drug Authority (US FDA) in 1982 for the treatment of severe nodulocystic acne.<sup>4</sup> In the usual oral dosage of 0.5 to 1.0 mg/kg per day, Isotretinoin works by reducing the size and activity of the sebaceous glands, thereby decreasing sebum production.<sup>5</sup>

However, Isotretinoin has been associated with various ocular adverse effects, like, altered meibomian gland secretion, blepharoconjunctivitis, corneal opacities, increased tear osmolarity, keratitis, ocular discomfort, keratoconjunctivitis sicca, and photophobia. Among these, permanent keratoconjunctivitis sicca (dry eye) is a likely distressing complication.<sup>6</sup> Patients receiving Isotretinoin often complain dry eye symptoms which are in congruence with the definition of dry eye as provided by the second Tear Film and Ocular Surface Society's Dry Eye Workshop (TFOS DEWS II), 2017. Dry eye is described as a multifactorial disease of the affecting ocular surface, characterized by tear film instability, hyperosmolarity, inflammation, damage, and neurosensory dysfunction.<sup>7</sup> Common symptoms include dryness, a foreign body sensation, and burning, which tend to worsen throughout the day. Other symptoms include discharge, blurred vision, redness, and eyelid crusting, all of which can significantly impact the patient's quality of life.

Topical Autologous serum (AS), in the form of eye drops, has emerged as an effective treatment option for dry eye, especially in cases resistant to conventional therapies. In addition to its lubricant function, AS also contains biochemical components that more closely resemble natural tears, such as growth factors, vitamins, and immunoglobulins.<sup>8–11</sup> These components are known to hasten the healing of the ocular surface, providing a faster symptomatic relief. AS has, also, been shown to promote cell proliferation and migration, especially in corneal epithelial cells.<sup>12</sup> Its use in treating dry eye was first described by Fox,<sup>13</sup> and it has since been found beneficial for conditions like Neurotrophic Keratitis.<sup>14</sup>

At our institute, AS, along with Preservative-Free Artificial Tears (PFAT), is routinely used to manage dry eye. This study aims to evaluate the effectiveness of AS compared to PFAT in treatment of Isotretinoin induced dry eye condition.

## 2. Materials and Methods

We conducted a prospective observational analytical study on patients experiencing dry eye due to systemic Isotretinoin therapy. Ethical approval was obtained from the Institutional Ethics Committee. Acne patients treated with systemic Isotretinoin for >3 months were evaluated for presence of dry eye, using Ocular Surface Disease Index (OSDI), Schirmer test (ST) I, Tear Break-up Time (TBUT) assessed with Fluorescein sodium solution 2%, with three readings averaged and National Eye Institute (NEI) corneal and

conjunctival staining. Patients with an OSDI score >12, ST I <15 millimetres, TBUT <10 seconds and NEI corneal and conjunctival staining grade >0, were enrolled in the study, after obtaining a written informed consent. A thorough ophthalmic work-up was performed to exclude patients with pre-existing ocular pathologies or infections, a history of ocular herpes or dry eye prior to isotretinoin treatment, uncontrolled diabetes mellitus, systemic conditions such as Sjogren's syndrome and rheumatoid arthritis, regular contact lens use, smoking history, use of medications affecting tear production, severe anaemia (haemoglobin < 10 g/dL), and those who were HIV, HBsAg, or HCV positive.

The sample size was determined using the Charan and Biswas (2013) formula, resulting in a required sample of 86 participants. Allowing for a 10% data loss, the final sample size was adjusted to 88 patients.

After thorough ocular examination, 97 patients (182 eyes) were included in the study. Participants were divided into two groups based on their prescribed treatment: the Preservative-Free Artificial Tears (PFAT) group and the Autologous Serum (AS) group. The PFAT group was prescribed artificial tear vials to be instilled six times daily for three months, with instructions to store the vials in a cool, dark place.

For the AS group, patients underwent serological testing and provided informed consent. A 20 ml sample of venous blood was collected, allowed to rest at room temperature for two hours, and then centrifuged at 4°C at 4000 RPM for 10 minutes under sterile conditions. The serum was diluted with isotonic saline to prepare 40% solution and was dispensed in multiple commercially available empty eye drop vials (2.4 ml each) with pre-formed drop nozzle. Patients were instructed to use AS four times daily, along with artificial tears (0.5% Carboxy methyl Cellulose) twice daily. Patients were also advised to store the currently used vial in the refrigerator at 4°C, to be discarded after five days, and stock rest of the vials in a freezer at -20°C for no more than 3 months. Before use, the vials needed to be thawed at 4°C. All the instructions were provided to the patients in vernacular language in printed form to ensure proper AS vial storage and usage as well as ocular hygiene.

Follow-up assessments were conducted at 15 days, 1 month, 2 months, and 3 months.

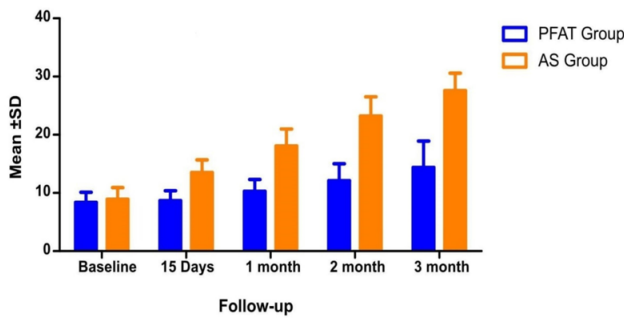
## 3. Results

Distributions of patients with dry eye due to systemic isotretinoin therapy into PFAT group and AS group are depicted in Table 1. The mean age was not significantly different between the two treatment groups as shown in Table 2. The gender distribution among either treatment groups was also not found significantly different (Table 3). The baseline mean ST (mm), TBUT(Sec), OSDI Scoring, and NEI scoring of corneal and conjunctival stain was

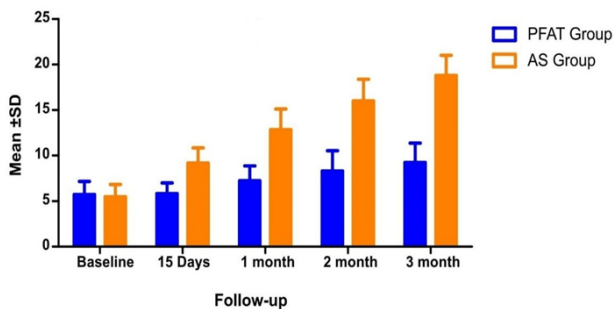
also not significantly different between the groups ( $p = 0.111$ ). Moreover, the mean Schirmer's (mm) TBUT(Sec), OSDI Scoring, and NEI scoring of corneal and conjunctival stain at 15 days, 1 month, 2 months, and 3 months were significantly higher in the AS group as compared to the PFAT group ( $p < 0.001$ ). The result is elaborated in detail in Table 4 and Figures 1, 2, 3 and 4.

**Table 1:** Distribution of study group according to treatment

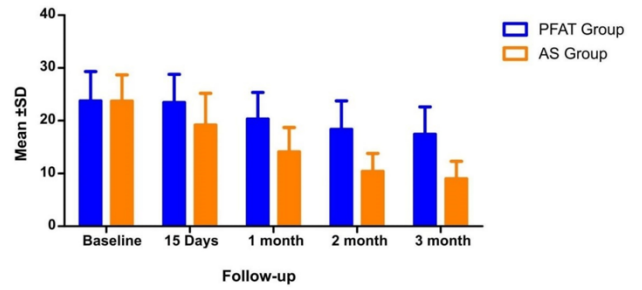
Study Groups	Treatment	n	%
PFAT Group	Preservative Free Artificial Tear	88	48.35
AS Group	Autologous Serum (40%)	94	51.65



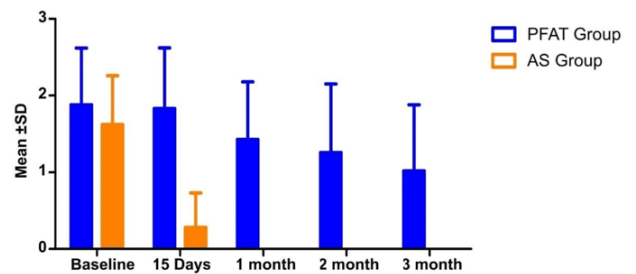
**Figure 1:** Bar chart shows the association of mean Schirmer's (mm) at baseline, 15 days, 1 month, 2 months and 3 months between preservative free artificial tears (PFAT) group and autologous serum (AS) group



**Figure 2:** Bar chart shows the association of mean tear break up time (TBUT) in sec. at baseline, 15 days, 1 month, 2 months and 3 months between preservative free artificial tears (PFAT) group and autologous serum (AS) group



**Figure 3:** Bar chart shows the association of mean ocular surface disease index (OSDI) Score at baseline, 15 days, 1 month, 2 months and 3 months between preservative free artificial tears (PFAT) group and autologous serum (AS) group



**Figure 4:** Bar chart shows the association of national eye institute (NEI) Grading of corneal and conjunctival staining at baseline, 15 days, 1 month, 2 months and 3 months between preservative free artificial tears (PFAT) group and autologous serum (AS) group

#### 4. Discussion

In this study, we found higher mean Schirmer in the AS group as compared to the PFAT group at 15 days, 1 month, 2 months, and 3 months. Similar trends were observed by Rawat et al. (2022)<sup>15</sup>, Noda-Tsuruya et al. (2006),<sup>16</sup> and Wang et al. (2020).<sup>17</sup> In agreement with the observations of the other researchers like Celebi et al. (2014),<sup>18</sup> Jirsova et al.<sup>19</sup>, Hussain,<sup>20</sup> and Garcia-Conca et al. (2018)<sup>21</sup> present study, found a significant improvement in Schirmer's test treated with autologous serum/ platelet rich plasma, compared to artificial tears alone. Furthermore, Karalezli et al. (2009)<sup>22</sup> and Tsubota et al. (1996)<sup>23</sup> demonstrated that Schirmer's test performed after the application of 0.5% proparacaine hydrochloride eye drops was more accurate and reliable for assessing dry eye status than the test without anesthesia.

Additionally, the mean TBUT in the AS group was significantly higher than that in the PFAT group at all follow-up assessments (15 days, 1 month, 2 months, and 3 months). Rawat et al. (2022)<sup>15</sup> similarly noted a significant improvement in TBUT after 3 months in the autologous platelet-rich plasma (aPRP) group ( $P < 0.001$ ), while the

**Table 2:** Association of mean age with preservative free artificial tears (PFAT) group and autologous serum (AS) group

PFAT Group (n=88)		AS Group (n=94)		t	p-Value
Mean age	±SD	Mean age	±SD		
23.55	3.29	23.68	3.73	-0.26	0.796

PFAT: Preservative free artificial tears  
AS: Autologous serum

**Table 3:** The distribution of patients according to gender in preservative free artificial tears (PFAT) group and autologous serum (AS) group

Gender	PFAT Group (n=88)		AS Group (n=94)		Chi sq.	p-Value
	n	%	n	%		
Male	46	52.27	56	59.57	0.71	0.400
Female	42	47.73	38	40.43		

PFAT: Preservative free artificial tears  
AS: Autologous serum

**Table 4:** Comparison between autologous serum (AS) and preservative free artificial tear

Types of Examination	Duration	PFAT Group		AS Group		t	p - value
		Mean	± SD	Mean	± SD		
<b>Schirmer I Test (mm)</b>	Baseline	8.38	1.75	8.83	1.95	-1.60	0.111
	15 Days	8.67	1.71	13.51	2.18	-16.58	<0.001*
	1 Month	10.27	2.04	18.09	2.88	-20.98	<0.001*
	2 Month	12.13	2.88	23.23	3.30	-24.13	<0.001*
	3 Month	14.38	4.54	27.57	3.02	-23.24	<0.001*
<b>TBUT (Sec)</b>	Baseline	5.73	1.44	5.49	1.35	1.15	0.251
	15 Days	5.84	1.17	9.18	1.66	-15.59	<0.001*
	1 Month	7.24	1.63	12.84	2.27	-19.01	<0.001*
	2 Month	8.31	2.23	16.01	2.38	-22.49	<0.001*
	3 Month	9.23	2.13	18.81	2.21	-29.79	<0.001*
<b>OSDI Score</b>	Baseline	1.68	0.74	1.62	0.64	0.56	0.560
	15 Day	1.56	0.79	0.28	0.45	-13.54	<0.001*
	1 Month	1.43	0.75	0.00	0.00	17.17	<0.001*
	2 Month	1.26	0.89	0.00	0.00	12.82	<0.001*
	3 Month	1.02	0.86	0.00	0.00	10.80	<0.001*
<b>NEI scoring of Corneal and Conjunctival stain</b>	Baseline	1.68	0.74	1.62	0.64	0.56	0.560
	15 Days	1.56	0.79	0.28	0.45	-13.54	<0.001*
	1 Month	1.43	0.75	0.00	0.00	17.17	<0.001*
	2 Month	1.26	0.89	0.00	0.00	12.82	<0.001*
	3 Month	1.02	0.86	0.00	0.00	10.80	<0.001*

PFAT- Preservative free artificial tears, AS- Autologous Serum, TBUT- Tear break up time, OSDI- Ocular surface disease index, NEI- National eye institute

improvement in the artificial tear group was not significant (P = 0.058). Comparable results were reported by Celebi et al. (2014),<sup>18</sup> Noda-Tsuruya et al. (2006),<sup>16</sup> Yilmaz (2017),<sup>24</sup> Wang et al. (2020),<sup>17</sup> Alio et al.,<sup>25</sup> and Valim et al.<sup>26</sup>

Regarding NEI grading for corneal staining, the Autologous Serum group showed significantly lower scores compared to the Preservative-Free Artificial Tear group across all time points. Garcia-Conca et al. (2018)<sup>21</sup> reported a 50% reduction in corneal staining in the PRP group after 15 days of treatment, a reduction that was less pronounced in the artificial tear group. Kojima et al. (2005)<sup>27</sup> also observed significant improvement in patients managed by

AS as compared to those treated with saline solution, while Alio et al. (2017)<sup>25</sup> found that 76.1% of patients exhibited reduced fluorescein staining, with at least a one-point drop on the modified Oxford scale, indicating improvement.

Furthermore, the mean OSDI scores were significantly better in the Autologous Serum group at all follow-up points. Rawat et al. (2022)<sup>15</sup> found a significantly lower OSDI score in the autologous PRP group (P < 0.001). Consistent findings were observed by Alio et al. (2017),<sup>25</sup> Sanchez-Avila et al. (2017),<sup>28</sup> and Merayo-Llodes et al. (2017).<sup>29</sup> Celebi et al.<sup>18</sup> reported a 55.18% reduction in OSDI scores in the Autologous Serum group (P < 0.001) compared to the Preservative-Free Artificial Tear group.

Yilmaz et al.,<sup>24</sup> in a study on dry eye caused by systemic Isotretinoin therapy, found a significant reduction in OSDI scores in both the Autologous Serum and Preservative-Free Artificial Tear groups, with a greater reduction in the Autologous Serum group ( $P < 0.0001$ ). Wang et al. (2020)<sup>17</sup> also concluded that OSDI scores were lower following Autologous Serum treatment compared to artificial tear treatment.

However, Urzua et al.<sup>30</sup> did not find Autologous Serum superior to artificial tears in terms of tear film break-up time (TBUT), Schirmer's test, or fluorescein staining for dry eye treatment. Noble et al. (2004)<sup>31</sup> also observed improvements in impression cytology in the Autologous Serum group but noted no significant differences in Rose-Bengal staining, Schirmer's test, or TBUT outcomes.

A limitation of the current study was the lack of refrigeration facilities among many participants due to their lower socioeconomic status, which impacted the proper storage of Autologous Serum.

## 5. Conclusions

Patients on systemic Isotretinoin therapy undergo treatment for 3 months during which they develop dry eye. Autologous Serum eye drops (AS) have a potential benefit over standard treatments in case of dry eye due to systemic Isotretinoin therapy since they not only act as a lubricant replacement but also contain additional biochemical components that allow them to resemble natural tears more precisely. It is a cost-efficient alternative to Artificial tears alone.

## 6. Source of Funding

None.

## 7. Conflict of Interest

None.

## References


- Layton AM. Disorders of the Sebaceous Glands. In: Burns T, Breathnach S, Cox N, Griffiths C, editors. Rook's Textbook of Dermatology. United States: Wiley Online Library; 2010.
- Budamakuntla L, Parasramani S, Dhoot D, Deshmukh G, Barkate H. Acne in Indian population: An epidemiological study evaluating multiple factors. *Indian J Clin Exp Dermatol*. 2020;6(3):237–42.
- Zasada M, Budzisz E. Retinoids: active molecules influencing skin structure formation in cosmetic and dermatological treatments. *Postepy Dermatol Alergol*. 2019;36(4):392–7.
- Layton A. The use of isotretinoin in acne. *Dermatoendocrinol*. 2009;1(3):162–9.
- Zaenglein AL, Pathy AL, Schlosser BJ, Stern M, Boyer KM, Bhushan R, et al. Guidelines of care for the management of acne vulgaris. *J Am Acad Dermatol*. 2016;74(5):945–73.
- Fraunfelder FT, Fraunfelder FW, Edwards R. Ocular side effects possibly associated with isotretinoin usage. *Am J Ophthalmol*. 2001;132(3):299–305.
- Craig JP, Nichols KK, Akpek EK, Caffery B, Dua HS, Joo C, et al. TFOS DEWS II Definition and Classification Report. *Ocul Surf*. 2017;15(3):276–83.
- Pan Q, Angelina A, Marrone M, Stark WJ, Akpek EK. Autologous serum eye drops for dry eye. *Cochrane Database Syst Rev*. 2017;2(2):CD009327.
- Tsubota K, Goto E, Fujita H, Ono M, Inoue H, Saito I, et al. Treatment of dry eye by autologous serum application in Sjögren's syndrome. *Br J Ophthalmol*. 1999;83(4):390–5.
- Nelson JD, Gordon JF. Topical fibronectin in the treatment of keratoconjunctivitis sicca. Chiron Keratoconjunctivitis Sicca Study Group. *Am J Ophthalmol*. 1992;114(4):441–7.
- Joh T, Itoh M, Katsumi K, Yokoyama Y, Takeuchi T, Kato T, et al. Physiological concentrations of human epidermal growth factor in biological fluids: use of a sensitive enzyme immunoassay. *Clin Chim Acta*. 1986;158(1):81–90.
- Nishida T, Ohasai Y, Awata T, Manabe R. Fibronectin a new therapy for corneal trophic ulcer. *Arch Ophthalmol*. 1983;101(7):1046–8.
- Fox RI, Chan R, Michelson JB, Michelson PE. Beneficial effect of artificial tears made with autologous serum in patients with keratoconjunctivitis sicca. *Arthritis Rheum*. 1984;27(4):459–61.
- Matsumoto Y, Dogrou M, Goto E, Ohashi Y, Kojima T, Ishida R, et al. Autologous serum application in the treatment of neurotrophic keratopathy. *Ophthalmology*. 2004;111(6):1115–20.
- Rawat P, Agrawal R, Bhaisare V, Walia S, Kori N, Gupta R. Autologous platelet-rich plasma eye drop versus artificial tear eye drop for symptomatic dry eye disease: A prospective comparative interventional study. *Indian J Ophthalmol*. 2022;70(5):1549–53.
- Noda-Tsuruya T, Asano-Kato N, Toda I, Tsubota K. Autologous serum eye drops for dry eye after LASIK. *J Refract Surg*. 2006;22(1):61–6.
- Wang L, Cao K, Wei Z, Baudouin C, Labbé A, Liang Q. Autologous serum eye drops versus artificial tear drops for dry eye disease: A systematic review and meta-analysis of randomized controlled trials. *Ophthalmic Res*. 2020;63(5):443–51.
- Celebi AR, Ulusoy C, Mirza GE. The efficacy of autologous serum eye drops for severe dry eye syndrome: a randomized double-blind crossover study. *Graefes Arch Clin Exp Ophthalmol*. 2014;52(4):619–26.
- Jirsova K, Brejchova K, Krabcova I, Filipec M, Fakh AA, Palos M, et al. The application of autologous serum eye drops in severe dry eye patients; subjective and objective parameters before and after treatment. *Curr Eye Res*. 2014;39(1):21–30.
- Hussain M, Shtein RM, Sugar A, Soong HK, Woodward MA, Deloss K, et al. Long-term use of autologous serum 50% eye drops for the treatment of dry eye disease. *Cornea*. 2014;33(12):1245–51.
- García-Conca V, Abad-Collado M, Hueso-Abancens JR, Mengual-Verdú E, Piñero DP, Aguirre-Balsalobre F, et al. Efficacy and safety of treatment of hyposecretory dry eye with platelet-rich plasma. *Acta Ophthalmol*. 2019;97(2):170–8.
- Karalezli A, Borazan M, Altinors DD, Dursun R, Kiyici H, Akova YA. Conjunctival Impression Cytology, Ocular Surface, and Tear-Film Changes in Patients Treated with Systemic Isotretinoin. *Cornea*. 2009;28(1):46–50.
- Tsubota K, Xu KP, Fujihara T, Katagiri S, Takeuchi T. Decreased reflex tearing is associated with lymphocytic infiltration in lacrimal glands. *J Rheumatol*. 1996;23(2):313–20.
- Yılmaz U, Küçük E, Koç Ç, Gökler E. Comparison of Autologous Serum Versus Preservative Free Artificial Tear in Patients with Dry Eyes Due to Systemic Isotretinoin Therapy. *Curr Eye Res*. 2017;42(6):827–31.
- Alio JL, Rodriguez AE, Ferreira-Oliveira R, Wróbel-Dudzińska D, Abdelghany AA. Treatment of Dry Eye Disease with Autologous Platelet-Rich Plasma: A Prospective, Interventional, Non-Randomized Study. *Ophthalmol Ther*. 2017;6(2):285–93.
- Valim V, Trevisani VF, Pasoto SG, Serrano EV, Ribeiro SLE, Fidelix T, et al. Recommendations for the treatment of Sjögren's syndrome. *Rev Bras Reumatol*. 2015;55(5):446–57.
- Kojima T, Ishida R, Dogru M, Goto E, Matsumoto Y, Kaido M, et al. The effect of autologous serum eyedrops in the treatment of severe

- dry eye disease: a prospective randomized case-control study. *Am J Ophthalmol*. 2005;139(2):242–6.
28. Sanchez-Avila RM, Lloves JM, Riestra AC, Anitua E. The effect of immunologically safe plasma rich in growth factor eye drops in patients with Sjogren Syndrome. *J Ocul Pharmacol Ther*. 2017;33(5):391–9.
29. Merayo-Llodes J, Sanchez-Avila RM, Riestra AC, Anitua E, Begoña L. Safety and efficacy of autologous plasma rich in growth factors eye drops for the treatment of evaporative dry eye. *Ophthalmic Res*. 2016;56(2):68–73.
30. Urzua CA, Vasquez DH, Huidobro A, Hernandez H, Alfaro J. Randomized double-blind clinical trial of autologous serum versus artificial tears in dry eye syndrome. *Curr Eye Res*. 2012;37(8):684–8.
31. Noble BA, Loh RSK, MacLennan S, Pesudovs K, Reynolds A, Bridges LR, et al. Comparison of autologous serum eye drops with conventional therapy in a randomised controlled crossover trial for ocular surface disease. *Br J Ophthalmol*. 2004;88(5):647–52.

### Author biography


**Snigdha Sen**, Professor and HOD  <https://orcid.org/0000-0003-1437-5869>

**Himanshu K Yadav**, Professor and HOD

**Anu Jain**, Associate Professor  <https://orcid.org/0000-0003-1833-7528>

**Ila Tripathi**, Senior Resident

**Yatendra Chahar**, Associate Professor

**Rajendra Prakash Maurya**, Professor  <https://orcid.org/0000-0001-9343-6003>

**Cite this article:** Sen S, Yadav HK, Jain A, Tripathi I, Chahar Y, Maurya RP. Efficacy of topical autologous serum versus preservative free artificial tears in patients having isotretinoin induced dry eye diseases. *Indian J Clin Exp Ophthalmol* 2024;10(3):441–446.