

Content available at: <https://www.ipinnovative.com/open-access-journals>

Indian Journal of Clinical and Experimental Ophthalmology

Journal homepage: [www.ijceo.org](http://www.ijceo.org)

## Original Research Article

## To study the optic nerve characteristics in patients with optic neuritis

Supriya B N<sup>1\*</sup>, Srinivas Phani Nakkella<sup>2</sup>, Divya Prasad<sup>3</sup><sup>1</sup>Dept. of Ophthalmology, Adichunchanagiri University (ACU), Bellur, Karnataka, India<sup>2</sup>Dept. of Ophthalmology, Shri Ganesh Vinayak Eye Hospital, Raipur, Chattisgarh, India<sup>3</sup>Dept. of Ophthalmology, Navodaya Medical College and Research Center, Raichur, Karnataka, India

## ARTICLE INFO

## Article history:

Received 14-12-2023

Accepted 10-02-2024

Available online 04-07-2024

## Keywords:

Optic neuritis

Optic nerve

Multiple sclerosis

## ABSTRACT

**Background:** Optic neuritis is defined as an autoimmune demyelinating disorder of the optic nerve. It can be idiopathic/post infectious/component of multiple sclerosis. It is not associated with other systemic diseases so commonly. It causes inflammation, which affects the myelin lining of the optic nerve. Aim of this study was to identify study the optic nerve characteristics in patients with optic neuritis in a tertiary care center.

**Materials and Methods:** A descriptive study was done on 30 patients with optic neuritis, by considering specific components that determine the optic nerve function. Components of optic nerve studied includes, visual acuity, color vision, contrast sensitivity, visual fields, visual evoked potential and magnetic resonance imaging (MRI).

**Results:** Optic neuritis is more common in females than males (66.6%). Most common age group is 26-35 years (36.6%). Relative afferent pupillary defect (RAPD) seen in 50% of patients (15 pts). Visual acuity loss majority in between hand movements—counting fingers close to face (40%). Color vision defects were present in all the patients, Red-Green color defect was more common. Visual fields showed severely depressed fields in 30% patients. MRI was normal in 83% patients.

**Conclusion:** Optic neuritis usually affects young adults. Proper diagnosis of the disease, correct treatment at right time is necessary. Combined approach for treatment with neurologist is required to make them aware of disease process, treatment & to prevent recurrences.

This is an Open Access (OA) journal, and articles are distributed under the terms of the [Creative Commons Attribution-NonCommercial-ShareAlike 4.0 License](https://creativecommons.org/licenses/by-nc-sa/4.0/), which allows others to remix, tweak, and build upon the work non-commercially, as long as appropriate credit is given and the new creations are licensed under the identical terms.

For reprints contact: [reprint@ipinnovative.com](mailto:reprint@ipinnovative.com)

## 1. Introduction

Optic neuritis is defined as an autoimmune demyelinating disorder of the optic nerve. It can be idiopathic/or postinfectious component of multiple sclerosis. It is not associated with other systemic diseases so commonly.<sup>1</sup> It causes inflammation, which affects myelin lining of the Optic Nerve. The general characteristics of optic neuritis, especially in an isolated type are unilateral, subacute, and painful loss of vision without systemic or other neurological symptoms. Loss of vision in acute cases is usually abrupt

and takes several hours to days, progression for more than one-week recovery in the next four to six weeks. Pain may be of mild, dull eye ache, more with retrobulbar type, aggravated by ocular movements present in more than 90% of the cases. The severity of visual loss varies from a mild visual field defect to a severe loss of central acuity [scotomas /nerve bundle defects]. RAPD is detected in almost all unilateral cases of optic neuritis.<sup>1</sup>

Objective of this study was to study the optic nerve characteristics in patients with optic neuritis.

\* Corresponding author.

E-mail address: [supriyabnsupriya@gmail.com](mailto:supriyabnsupriya@gmail.com) (Supriya B N).

**2. Materials and Methods**

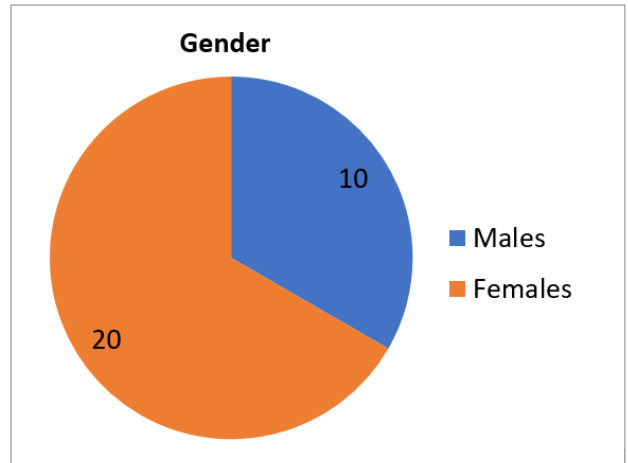
It was a prospective study conducted on 30 patients with optic neuritis in the department of Ophthalmology, at a tertiary care center, from July 2020 to June 2021. The institute Ethics Committee approval was obtained. A written and informed consent was taken from the patient regarding the study in his/her vernacular language and English. Patients were subjected to: A detailed history of symptoms and its duration. Detailed history of systemic diseases and its duration, medication were noted. Patients were subjected to General physical examination, and ocular examination. Visual acuity was recorded by Snellen’s chart, Slit lamp bio-microscopy of anterior segment was done, Pupillary reactions were noted. Detailed examination of the posterior segment was done with Direct and indirect ophthalmoscopy and also with 90D Lens. Colour vision test was done with Ishihara pseudo-isochromatic plates. Visual field with full threshold HVF 30-2 test done. MRI brain imaging done. The results of these 30 patients were collected, tabulated and analysed. The data collected was entered in excel spread sheet. The data was analyzed by using SPSS statistical software version 20. Statistical analysis in the form of percentages was done.

**3. Results**

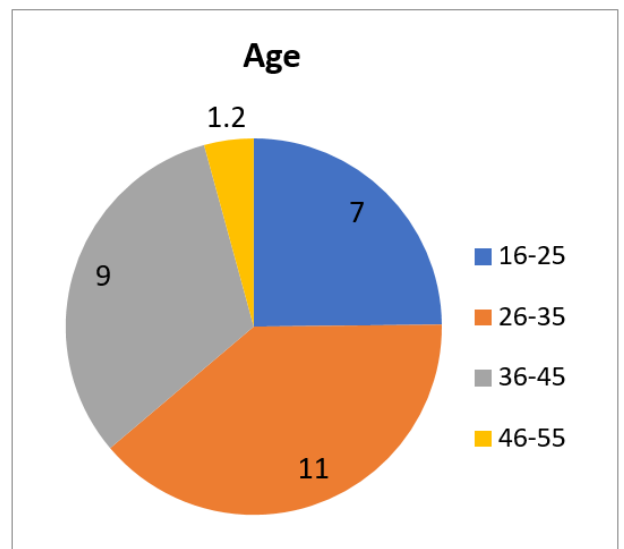
Optic neuritis is more common in females than males and is about 66.6% (Graph 1). Most common age group is 26-35 years and it is 36.6% followed by 36-45 years which is 32% (Graph 2). In the pupillary reactions, RAPD was seen in 50% of patients that is in 15 patients. Grade 2 RAPD was the most common type seen in 5 patients (Graph 3). Visual acuity loss, majority of patients were in between hand movements–counting fingers close to face and was about 40% (Table 1). On fundus examination, edematous disc with the blurred disc margins was the most common finding seen in 40% of the patients (Table 2). Colour vision defects were present in all the patients, Red-Green colour defect was more common and was seen in 18(60%) patients. Visual fields showed severely depressed fields in 30% patients. MRI was normal in 83% patients, but in 17% of patients features suggestive of retrobulbar optic neuritis like hyperintense lesions in retrobulbar optic nerve was found.

**Table 2:** Visual acuity based distribution of the study subjects

Visual acuity	Number of patients
No PL	4
HM – CF close to face	12
CF1m - CF3m	4
CF 3m – CF 5m	6
>6/60	6



**Figure 1:**



**Figure 2:**

**Table 1:** Fundus disc findings of the patients

Fundus disc findings	Number
Edematous disc with blurred disc margins	20
Hyperemic disc	2
Pale disc	2
Tilted disc	1
Normal	5

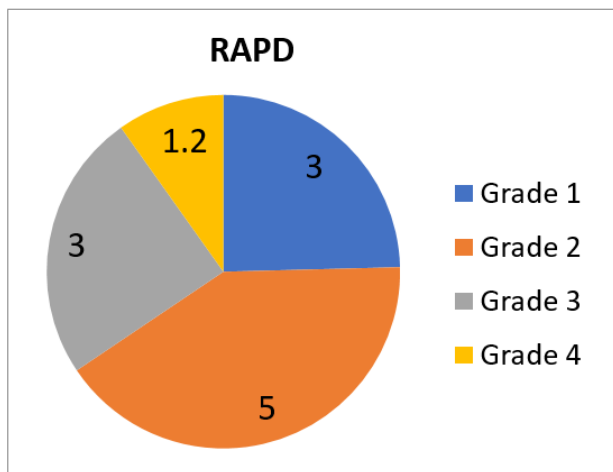


Figure 3:

#### 4. Discussion

Optic neuritis, a primary inflammation of the optic nerve, is referred to as papillitis when the optic disc is swollen and as retrobulbar Neuritis when the disc appears normal. The most common form of optic neuritis is acute demyelinating optic neuritis. The optic nerve function characteristics studied are in the form of visual acuity which is done by Snellen's chart; colour vision by Ishihara plates; contrast sensitivity by PelliRobson chart; visual fields by Humphreys visual field 30-2; Visual Evoked Potential VEP; lastly MRI brain.

In a study conducted by D. Pau et al.,<sup>2</sup> they have concluded that the patients with acute demyelinating ON are healthy young adults typically and most of the patients age range was between 20-45 years of age, with female preponderance by a ratio of 3:1, their study findings are correlating with our study.

Beck R et al.<sup>3</sup> in their study showed a female (77%) predominance, which is in correlation with our study.

In a study conducted by Schneck ME et al.<sup>4</sup> on colour vision defect type, showed mixed red-green defects [RG] and blue-yellow [BY] colour defects. Verriest et al.<sup>5</sup> and Silverman SE et al.<sup>6</sup> also shows RG>BY colour defects. Our study is in correlation with these studies. Katz b et al.,<sup>7</sup> in their study concluded that blue, yellow defects were the majority at the time of the acute attack, whereas at six months, red/green defects were the majority.

Griffin et al.,<sup>8</sup> study concluded that the number of errors increased with greater residual optic nerve damage. Kuchenbecker J et al.<sup>9</sup> have written, that the number of incorrectly identified plates correlated with a decrease in visual acuity. They used advanced technology for doing the test known as the web test. They said that, altering the combination of plates may be used as a next step by using the web-based analysis. Our study is in correlation with these studies.

John L. Keltner et al.,<sup>10</sup> 20% eyes had retinal nerve fiber defects; 8% had central /centrocecal scotomas, and 24% of eyes had other types. Our study is in contrast to their study. Nevalainen J et al.,<sup>11</sup> concluded that central and retinal nerve fiber bundle defects as the most common visual field defects in acute optic neuritis which is in contrast to our study. These studies confirmed that it is unlikely that a specific group of nerve fiber bundles are vulnerable in optic neuritis patients so they confirmed that automated perimetry alone could not be used to distinguish optic neuritis reliably from other acute optic neuropathies. Standardised techniques for performing and analysing the defects was studied and demonstrated. This might be the reason for severely depressed fields in our study because we have used the Humphreys visual field analyser rather than other perimeters; and so our findings are in contrast to other studies.

Gerling J et al.<sup>12</sup> study concluded that a central scotoma as the most common visual field defect which is in contrast to our study.

Fazzone HE et al.,<sup>13</sup> concluded that when optic neuritis involves the orbital segment of the optic nerve, pain was significantly more frequent. In contrast, the pain was absent more often when the orbital segment was not involved. In our study, pain was present in 10 out of 30 patients. Of that, only 6 had retrobulbar neuritis, and in them, only 4 had pain [66.6%]. So our study is correlating with their study.

In another study by Alshualb WB et al.,<sup>14</sup> where they compared VEP abnormalities in multiple sclerosis and optic neuritis have found that decreased amplitude and P100 and N145 latencies were prolonged in optic neuritis and also in confirmed MS patients. Our study is correlating with their study, P100 latencies were prolonged in our study, although our study didn't have any multiple sclerosis-associated patients.

In a study conducted by Chuntao Lai et al.,<sup>15</sup> on lesion activity on brain MRI in a Chinese population with unilateral optic neuritis have said that out of 40 patients, 19 patients, i.e. 48% had brain lesions that were characteristics of Multiple sclerosis and 3% had gd-enhanced brain lesions. However, patients exhibited low lesion activity. But in our study, we had no cases associated with multiple sclerosis, no similar studies found in literature; moreover, MRI brain was normal. And hence not correlating with their study.

#### 5. Conclusion

Optic neuritis usually affects young adults. Proper diagnosis of the disease, correct treatment at right time is necessary. The major concern lies with the future recurrences and association of optic neuritis with multiple sclerosis and /other demyelinating disorders, because once the patient receives the treatment and gets relieved he/she starts neglecting it. Combined approach for treatment with neurologist is required to make them aware of disease

process, treatment & to prevent recurrences.

## 6. Source of Funding

None.

## 7. Conflict of Interest

None.

## References

- Schiefer U, Wilhelm H, Hart W, editors. Clinical Neuro-Ophthalmology- A Practical Guide. Berlin Heidelberg: Springer-Verlag; 2007.
- Pau D, Zubidi NA, Yalamanchili S, Plant GT, Lee AG. Optic neuritis. *Optic Neuritis Eye*. 2011;25(7):833–42.
- Beck RW. The optic neuritis treatment trial: three-year follow-up results. *Arch Ophthalmol*. 1995;113(2):136–7.
- Schneck ME, Haegerstrom-Portnoy G. Color vision defect type and spatial vision in the optic neuritis treatment trial. *Invest Ophthalmol Vis Sci*. 1997;38(11):2278–89.
- François J, Verriest G. On acquired deficiency of colour vision, with special reference to its detection and classification by means of the tests of Farnsworth. *Vis Res*. 1961;1(3-4):201–9.
- Silverman SE, Hart WM, Gordon MO, Kilo C. The dyschromatopsia of optic neuritis is determined in part by the fovea/perifoveal distribution of visual field damage. *Invest Ophthalmol Vis Sci*. 1990;31(9):1895–902.
- Katz B. the dyschromatopsia of optic neuritis : a descriptive analysis of data from the optic neuritis treatment trial. *Trans Am Ophthalmol Soc*. 1995;93:685–708.
- Griffin JF, Wray SH. Acquired color vision defects in RetrobulbarNeuritis. *Am J Ophthalmol*. 1978;86(2):193–201.
- Kuchenbecker J, Blum M, Paul F. Investigation of color vision in acute unilateral optic neuritis using a web-based color vision test. *Ophthalmologe*. 2016;113(3):223–9.
- Keltner JL, Johnson CA, Spurr JO, Beck RW. Baseline Visual Field Profile Of Optic neuritis. *Arch Ophthalmol*. 1993;111(2):231–4.
- Nevalainen J, Krapp E, Paetzold J, Mildenerger I, Besch D, Vonthein R, et al. Visual field defects in acute optic neuritis–distribution of different types of defect pattern, assessed with threshold-related supraliminal perimetry, ensuring high spatial resolution. *Graefes Arch Clin Exp Ophthalmol*. 2008;246(4):599–607.
- Gerling J, Meyer JH, Kommerell G. Visual field defects in optic neuritis and anterior ischemic optic neuropathy: distinctive features. *Graefe's Arch Clin Exp Ophthalmol*. 1998;236:188–92.
- Fazzone HE, Lefton DR, Kupersmith MJ. Optic neuritis: correlation of pain and magnetic resonance imaging. *Ophthalmology*. 2003;110(8):1646–9.
- Aishualb WB. Progression of visual evoked potential abnormalities in multiple sclerosis and optic neuritis. *Electromyogr Clin Neurophysiol*. 2000;40(4):243–52.
- Lai C, Chang Q. Lesion Activity on Brain MRI in a Chinese Population with Unilateral Optic Neuritis. *PLoS One*. 2015;10(10):e0141005.

## Author biography

**Supriya B N**, Assistant Professor

**Srinivas Phani Nakkella**, Consultant Ophthalmologist

**Divya Prasad**, Assistant Professor

**Cite this article:** Supriya B N, Nakkella SP, Prasad D. To study the optic nerve characteristics in patients with optic neuritis. *Indian J Clin Exp Ophthalmol* 2024;10(2):298-301.