

Content available at: <https://www.ipinnovative.com/open-access-journals>

Indian Journal of Clinical and Experimental Ophthalmology

Journal homepage: [www.ijceo.org](http://www.ijceo.org)

## Case Report

# Novel incision to debulk eyelids in a case of Orbital Periorbital Plexiform Neurofibroma (OPPN): A case report

Umesh Kumar<sup>1\*</sup>, Sudipta Bera<sup>1</sup>, Shikha Jaiswal<sup>1</sup>, K Cheruvu Natraj Navya<sup>1</sup>,  
Vivek Vijay Kumar<sup>1</sup>, Rajendra P Maurya<sup>2</sup>

<sup>1</sup>Dept. of Plastic Surgery, Institute of Medical Sciences, Banaras Hindu University, Varanasi, Uttar Pradesh, India

<sup>2</sup>Regional Institute of Ophthalmology, Institute of Medical Sciences, Banaras Hindu University, Varanasi, Uttar Pradesh, India



## ARTICLE INFO

### Article history:

Received 26-10-2023

Accepted 11-12-2023

Available online 29-12-2023

### Keywords:

Periorbital  
Neurofibroma  
Debulking  
Incision

## ABSTRACT

**Background:** Plexiform neurofibroma with neurofibromatosis 1 is a autosomal dominant condition and a relatively rare condition. It is also termed as Von Recklinghausen disease. PN involving the structures like eyelid, orbit, periorbital and facial structures are labelled as orbital-periorbital PN(OPPN). These are slowly progressing lesions and are present since birth but increase in size during childhood and are locally infiltrating in nature.

**Aim:** To describe a lid incision to simultaneously debulk both upper and lower eyelid, preserving the vascularity in a case of Orbital Periorbital Plexiform Neurofibroma (OPPN).

**Case Presentation:** We report a case of 22 year male who presented with a disfiguring swelling of right side of face since childhood. After thorough clinical and radiological evaluation it was diagnosed to be a OPPN. Staged debulking was planned and after stage 1 debulking, tissue was sent for HPE which revealed overgrowth of peripheral nerve components and connective tissue dermis showing infiltrating tumour composed of oval to spindle cells with pleomorphic nuclei and moderate cytoplasm. Staged debulking with lid reduction surgery was performed.

**Discussion:** Neurofibroma is a rare entity with plexiform neurofibroma occurring in 5-15% of patients. OPPN infiltrates locally without respecting the anatomical planes but follows the trigeminal nerve distribution usually. Indications for debulking procedure are usually the disfigurement and optimal timing is also not certain because the extent and rate of growth cannot be predicted.

**Conclusion:** The facial appearance and outcome in patients with OPPN can be significantly improved through lid reduction surgery.

This is an Open Access (OA) journal, and articles are distributed under the terms of the [Creative Commons Attribution-NonCommercial-ShareAlike 4.0 License](https://creativecommons.org/licenses/by-nc-sa/4.0/), which allows others to remix, tweak, and build upon the work non-commercially, as long as appropriate credit is given and the new creations are licensed under the identical terms.

For reprints contact: [reprint@ipinnovative.com](mailto:reprint@ipinnovative.com)

## 1. Introduction

Neurofibromatosis type 1 (NF-1) is a common condition which occurs approximately in 1:3500 births.<sup>1,2</sup> Plexiform neurofibroma involving structures like eyelid, orbit, periorbital and facial structures are labelled as periorbital plexiform neurofibroma(OPPN). They are rare tumours associated with neurofibromatosis 1(NF1), a tumour

predisposing syndrome. The gene responsible for this condition is located on chromosome 17 at locus 17q11.2. It codes for a protein called neurofibromin.<sup>3</sup> OPPN are present since birth but progress gradually during early childhood. Substantial morbidity in these lesions is due to physical appearance and tendency of causing functional or neurological impairments. Most common indications for surgical intervention are improvement in physical appearance. OPPN often invade adjacent structures without respecting the anatomical planes and this complicates the

\* Corresponding author.

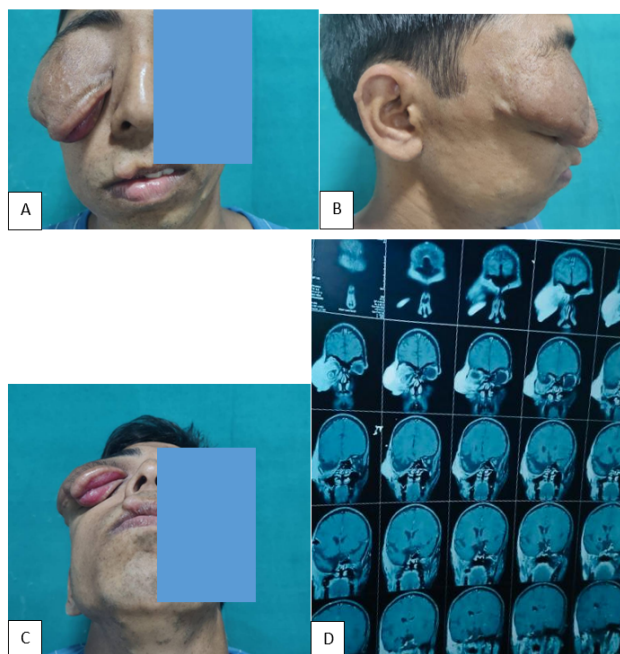E-mail address: [umeshkrplastic@gmail.com](mailto:umeshkrplastic@gmail.com) (U. Kumar).

surgical treatment. Because of the infiltrating nature most of the cases require multiple surgeries as total excision is usually not possible.<sup>3</sup> Literature on surgical procedures for patients with NF-1 associated OPPN are scanty. We present a case where a single incision was planned preserving the vascular arcades of eyelids to simultaneously debulk both upper and lower eyelids.

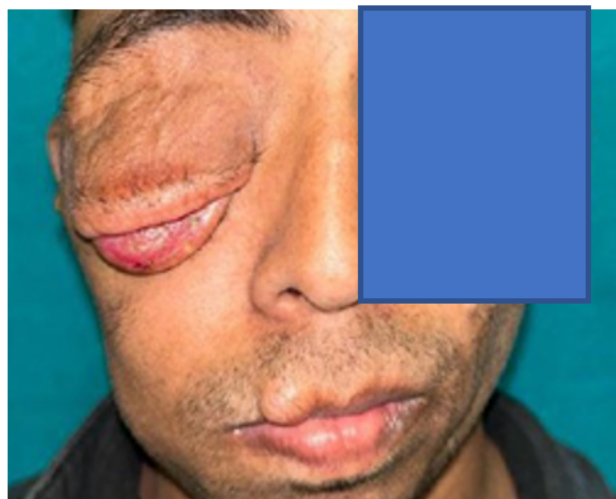## 2. Case Report

A 22-year male patient presented to us with complaints of swelling of the right side of face. (Figure 1 A, B, C) Swelling appeared in childhood and was initially 2\*2 cm in size which slowly progressed. No positive family history. On physical examination a single diffuse swelling of size 8\*6 cm size hanging down from right upper eyelid with normal surrounding skin extending from right supraorbital rim to upper third cheek vertically. Horizontally from medial canthus to 3 cms beyond lateral orbital rim. The swelling was not well circumscribed. It was firm in consistency. Phthisis bulbi of right eye was noted. Café au lait macules and several freckles were seen in the axilla, back and trunk. He had multiple swellings over his face, neck and trunk. Clinical diagnosis of OPPN was made based on above findings. MRI showed right periorbital plexiform neurofibroma with extensions postero-inferiorly into right temporal fossa abutting external pericranium of right fronto-temporo-zygomatico-maxillary areas without bony/intracranial extension, medially involving eyelid and orbit with resultant phthisis bulbi, inferiorly right masticator space hypoplasia of right half of sphenoid bone, deformed small size right bony orbit with shrunken calcified right globe, optic nerve and canal not visualized.(Figure 1 D) As complete excision was not possible, staged debulking and lid reduction surgery was planned. The horizontal eye width and lid crease were marked. Incision marked over upper eyelid swelling extending beyond the lateral orbital wall. Mass was seen infiltrating deep and the tissue planes could not be delineated. Subtotal excision of mass was done with readjustment of skin flap and reasonable post-op correction. Tissue sent for histopathological examination. On histopathological examination the findings were overgrowth of peripheral nerve components and connective tissue dermis showed infiltrating tumour consisting of oval to spindle cells with pleomorphic nuclei and moderate cytoplasm with no cytological atypia.

In second stage of debulking, preoperative marking of incision was done as showed retaining the vascular arcade of upper and lower eye lids (Figure 3 A, B, C) Normal eye measurements were noted, distance between medial canthus and lateral orbital wall measured 4 cm, distance between midline and lateral orbital wall measured 6.5cms and distance between supraorbital rim and distal end of tarsal plate measured 1.5 cm. Lid crease marked comparing with other side and lid traction sutures taken according

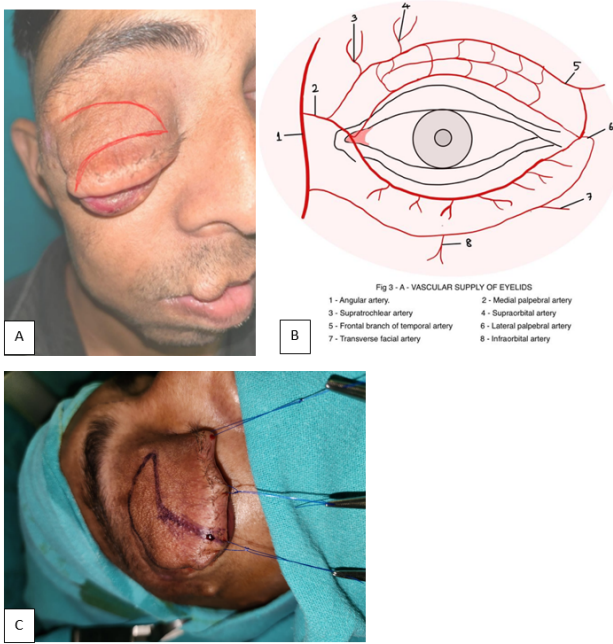


**Figure 1:** Orbital plexiform NF involving Right eyelids; **A):** Frontal view; **B):** Lateral view; **C):** Worm's eye view; **D):** MRI-Coronal section

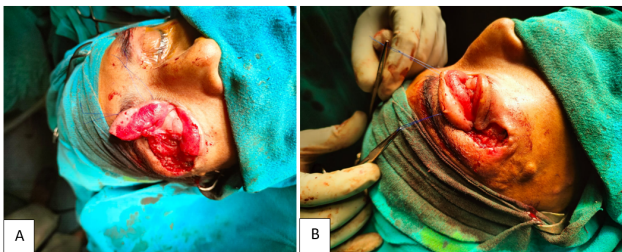

**Figure 2:** Follow up after first debulking

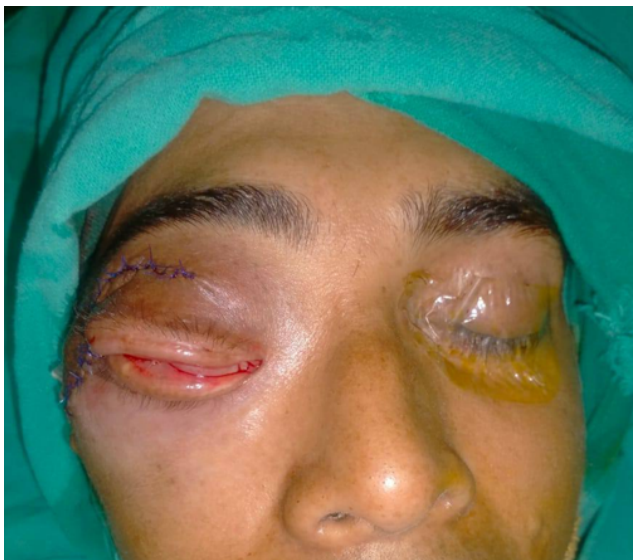to the measurements made in normal lid, markings made in right upper and lower lids. Tumour mass excised and removed from upper and lower eyelids. Sutures were applied in the lateral canthal area between the skin flap and the lateral orbital margin so as to prevent pulling down of the eyelids. Incision closed in layers.(Figure 6) The postoperative period was uneventful. Further, planning includes medial canthopexy and correction of ptosis.



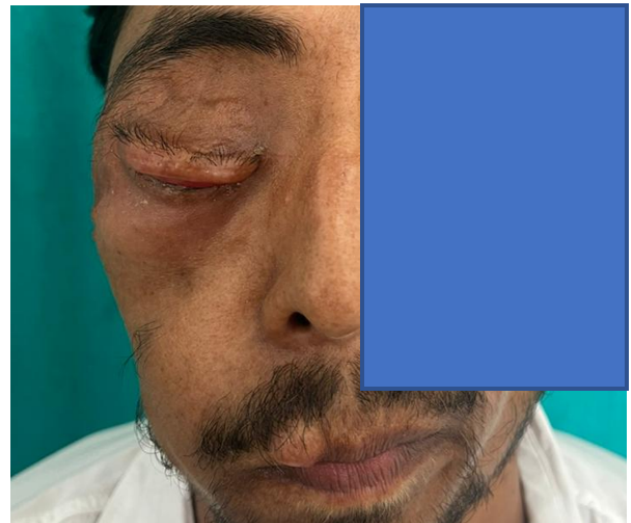**Figure 3: (A , B, C):** Planned incision line



**Figure 4: A):** View after debulking; **B):** Lateral view after lateral canthopexy



**Figure 5:** Suture line in Frontal view



**Figure 6:** Folow up after 6 months

### 3. Discussion

Neurofibromatosis 1(NF 1) is an autosomal dominant disease occurring due to NF1 gene mutation. Plexiform neurofibroma involving the structures like eyelid, orbit, periorbital and facial structures has been labelled as orbital-periorbital plexiform neurofibroma (OPPN). OPPN affects less than 10% NF1 cases and most of the lesions track along the trigeminal nerve distribution. It can infiltrate into surrounding structures causing proptosis, ptosis, amblyopia and facial disfigurement leading to visual disturbances and social distress.<sup>4</sup> The conference of the national institute of health in Bethesda (MD, USA) held in 1988 established 7 main criteria for the diagnosis of NF1. Diagnosis of NF 1 is made when any 2 of the following features are seen in the same individual (NIH, 1988): (1) first-degree relative affected (child, sibling or parent), (2) at least 6 café-au-lait spots: > 0.5 cm in prepubertal and >1.5 cm pubertal patients, (3) inguinal or axillary freckles (crowe sign), (4) minimum 2 neurofibromas of any type/ at least 1 plexiform neurofibroma, (5) optic nerve glioma, (6) at least 2 iris hamartomas called lisch nodules and (7) a specific bone lesion, like: sphenoid wing dysplasia with cortical long bone thinning and pseudoarthrosis. Histologically, these are peripheral nerve sheath tumours and are identified by an increase in the matrix of endoneurium along with separation of fascicles and proliferation of Schwann cells. Conversion into malignancy is seen in 4-5% individuals.<sup>5</sup> Indication for debulking surgery is usually the disfigurement and optimal timing is uncertain because the extent and rate of growth cannot be predicted and orbital deformities often continue progression after initial excision and repair but these are not actual recurrences, rather a progression of remnant periorbital and orbital tumours. Jackson classification for OPPN is based on the severity of lesions: group 1

(Involvement of orbital soft tissue with normal vision), group 2 (Involvement of orbital soft tissue and bony orbit with normal vision), and group 3 (Involvement of orbital soft tissue and bony orbit with a blind eye, phthisis bulbi or absent eye).<sup>6</sup> The swelling progresses relatively rapid in childhood and pubertal period but slowly in later life. PN growth varies greatly among individuals. Families are generally extremely motivated for surgical intervention but must be informed positively regarding need of multiple procedures which will be done in stages. In a 20-year study conducted at the children's hospital of Philadelphia (NF1 clinic), 131 patients had 302 procedures for head and neck tumours. The freedom from progression in overall cases was 56%. Compared with tumours excised from the extremities, the head and neck tumours had double the probability of recurrence.<sup>7</sup> Appearance concerns included ptosis, contour and asymmetry of the eyelids, canthal abnormalities. Due to weight of OPPN deformities of cheek and oral commissure are seen. Degree of surgical intervention and the time to intervene are controversial subjects. To prevent the orbital deformity and preserve the form and function of the eye, most surgeons usually recommend surgery during early childhood though a rapid growth phase is known to occur during early childhood and puberty. In contrast, correction of ptosis for cosmetic concerns is delayed until the age of 18, as disease progression is stabilised by that age. The recurrence rate is on higher side. To prevent the effects of expansion of the mass on both the periorbital soft tissues and the bony orbit, early surgical intervention before the age of 10 years may be necessary. Early surgery is important to minimize psychosocial concerns and to maximize the patient's cosmetic outcome. Early surgery helps boost self-esteem reduces social embarrassment as these affect the child as well as the entire family. Procedures for resection and reconstruction involving eyelids and periorbital region are extremely complex. OPPN present with infiltration into deeper planes requiring subtotal or total eyelid resection. Postoperative bleeding is concerning factor in the reduction of PN. Bleeding can already influence the extent and duration during the surgical intervention. However, the wound healing is aesthetically satisfactory.<sup>8</sup>

#### 4. Conclusion

Orbital plexiform neurofibroma significantly impacts the facial appearance of the patient. Holistic approach in stages can significantly improves the cosmetic appearance and helps in integration of patient into the society. The approach for debulking should be planned to preserve the vascularity of lids and should be along the langer's line to give optimal cosmetic and functional outcome.

#### 5. Source of Funding

None.


#### 6. Conflict of Interest

None.

#### References


1. Lynch TM, Gutmann DH. Neurofibromatosis 1. *Neurol Clin.* 2002;20(3):841–65.
2. Ferner RE. Neurofibromatosis 1 and neurofibromatosis 2: a twenty first century perspective. *Lancet Neurol.* 2007;6(4):340–51.
3. Poswal P, Bhutani N, Arora S, Kumar R. Plexiform neurofibroma with neurofibromatosis type I/ von Recklinghausen's disease: A rare case report. *Ann Med Surg (Lond).* 2020;57:346–50.
4. Yoshinaga A, Tsuge I, Saito S, Morimoto N. Orbital/Periorbital Plexiform Neurofibromas: Classification and Surgical Strategies for a Better Outcome. *Plast Reconstr Surg Glob Open.* 2023;11(7):e5108.
5. Dogra BB, Rana KS. Facial plexiform neurofibromatosis: A surgical challenge. *Indian dermatology online journal. Indian Dermatol Online J.* 2013;4(3):195–8.
6. Choi MS, Choi SH, Lee JH. Surgical correction in orbitotemporal neurofibromatosis with dystopia. *BMC Ophthalmol.* 2016;16:4.
7. Avery RA, Katowitz JA, Fisher MJ, Heidary G, Dombi E, Packer RJ, et al. Orbital/Periorbital Plexiform Neurofibromas in Children with Neurofibromatosis Type 1: Multidisciplinary Recommendations for Care. *Ophthalmology.* 2017;124(1):123–32.
8. Friedrich RE, Modemann M. Neurofibromatosis Type 1-Associated Plexiform Neurofibromas of the Face and Adjacent Head Regions: Topography of Lesions and Surgical Treatment Data of 179 Patients. *J Maxillofac Oral Surg.* 2023;22(3):511–24.

#### Author biography


**Umesh Kumar**, Associate Professor and HOD  <https://orcid.org/0000-0002-3832-3310>

**Sudipta Bera**, Assistant Professor  <https://orcid.org/0000-0002-7948-6175>

**Shikha Jaiswal**, Senior Resident  <https://orcid.org/0009-0006-6605-6172>

**K Cheruvu Natraj Navya**, Senior Resident  <https://orcid.org/0009-0000-7289-5630>

**Vivek Vijay Kumar**, Senior Resident

**Rajendra P Maurya**, Associate Professor  <https://orcid.org/0000-0001-9343-6003>

**Cite this article:** Kumar U, Bera S, Jaiswal S, Navya KCN, Kumar VV, Maurya RP. Novel incision to debulk eyelids in a case of Orbital Periorbital Plexiform Neurofibroma (OPPN): A case report. *Indian J Clin Exp Ophthalmol* 2023;9(4):653–656.