

Content available at: <https://www.ipinnovative.com/open-access-journals>

Indian Journal of Clinical and Experimental Ophthalmology

Journal homepage: www.ijceo.org

Original Research Article

Incidence and determinants of hypertensive retinopathy in hypertension patients at a teaching hospital in North Western Karnataka

Chethana Warad^{1*}, Ruben Roy Simon¹, Radhika Wani¹, Ruchi Singh¹, Shivakrishna Pavuluri¹, V A Kothiwale²¹Dept. of Ophthalmology, Jawaharlal Nehru Medical College, Belagavi, Karnataka, India²Dept. of General Medicine, Jawaharlal Nehru Medical College, Belagavi, Karnataka, India

ARTICLE INFO

Article history:

Received 09-09-2023

Accepted 03-11-2023

Available online 29-12-2023

Keywords:

Hypertension

Hypertensive retinopathy

Age

Duration

Risk factors

ABSTRACT

Background: Persistently raised blood pressure not only leads to retinal vascular damage but also leads to systemic diseases. The retinal vasculature observation by fundoscopy offers a great opportunity to explore the association of systemic microvascular disease caused by hypertension. Hypertensive retinopathy (HR) is considered to be a marker for vascular disease and death.

Objectives: The aim of the present study was to find out the prevalence of hypertensive retinopathy among hypertensive subjects and assess the pattern of retinopathy and associated risk factors.

Materials and Methods: This was a hospital based cross-sectional study conducted among hypertensive patients at a teaching hospital, for a period of 3 months.

Results: A total of 300 hypertensive patients formed the study population. The prevalence of the hypertensive retinopathy in the present study was 49.33%. Hypertensive retinopathy was more prevalent in men 62% than women 38%. The prevalence of grade 1 and grade 2 hypertensive retinopathies was 43.24% and 33.11% respectively and 20.95% and 2.7% had grade 3 and 4 respectively. The prevalence of retinopathy was found to be statistically higher in patients who had h/o hypertension for more than 5 years. The prevalence of hypertensive retinopathy was more common in age group >60yrs. The prevalence of target organ damage was higher in those having retinopathy.

Conclusion: The prevalence of hypertensive retinopathy is high in the present study which reflects lack of awareness, patient compliance, sub optimal measures to control blood pressure and even lack of prompt follow up with ophthalmologists. There is need to spread awareness and take adequate measures to reduce the burden of hypertensive retinopathy.

This is an Open Access (OA) journal, and articles are distributed under the terms of the [Creative Commons Attribution-NonCommercial-ShareAlike 4.0 License](https://creativecommons.org/licenses/by-nc-sa/4.0/), which allows others to remix, tweak, and build upon the work non-commercially, as long as appropriate credit is given and the new creations are licensed under the identical terms.

For reprints contact: reprint@ipinnovative.com

1. Introduction

Elevated blood pressure constitutes a significant and pressing public health concern in both developed and developing nations. The World Health Organization has issued warnings about developing countries facing a looming crisis of non-communicable diseases, with hypertension being a prominent example.¹ Systemic

hypertension is a prevalent chronic health condition in India, often underreported due to its asymptomatic nature, especially in its early stages. It is a well-established risk factor for systemic conditions that can lead to damage in target organs. Since the retina is a sensorineural tissue, it is susceptible to the effects of high blood pressure, resulting in various adverse outcomes such as retinopathy, optic neuropathy, choroidopathy, and various retinal vascular occlusions like CRAO, CRVO, BRAO, and BRVO, all of which are not uncommon in ophthalmic practice.

* Corresponding author.

E-mail address: cwarad639@gmail.com (C. Warad).

Among these conditions, hypertensive retinopathy stands as the most prevalent ocular manifestation of systemic hypertension. Furthermore, hypertensive retinopathy is closely associated with cardiovascular morbidity and mortality.^{2–4} Given that the eyes are unique in allowing direct observation of vascular changes through fundus examination, hypertensive retinopathy plays a crucial role in the clinical management of hypertensive patients, serving as an indicator for cardiovascular risk assessment. This assessment can guide the initiation of antihypertensive therapy, even in individuals with prehypertension or stage 1 hypertension.^{4–6}

Hypertensive retinopathy was first described by Marcus Gunn in 1898, who noted retinal vascular abnormalities linked to hypertension.⁷ Wong and Mitchell later defined hypertensive retinopathy as retinal microvascular signs that develop in response to elevated blood pressure. In 1939, Keith and his colleagues introduced the now universally adopted Keith-Wagener-Barker classification of hypertensive retinopathy.^{7–9}

Since hypertensive retinopathy is the most prevalent ocular manifestation of systemic arterial hypertension, any case of hypertension should be promptly referred to an ophthalmologist for fundal evaluation, given the higher likelihood of hypertensive retinopathy in such patients. Early detection and timely management can mitigate the risks of ocular and systemic morbidity and mortality.

The present study was conducted at a teaching hospital in northwestern Karnataka to determine the prevalence of hypertensive retinopathy among hypertensive patients, assess the patterns of hypertensive retinopathy stages, and identify associated risk factors.

2. Materials and Methods

This cross-sectional hospital-based study took place over a three-month period at a teaching hospital in north western Karnataka. The study adhered to the guidelines of the Institutional Review Board, and ethical clearance was obtained from the Institutional Ethics Committee before the study's initiation.

2.1. Inclusion criteria

1. Inclusion of male or female patients aged 18 years or older who were diagnosed with hypertension, with systolic blood pressure exceeding 130 mm Hg and diastolic blood pressure exceeding 90 mm Hg.
2. Patients currently receiving antihypertensive medication with blood pressure controlled within normal limits.
3. Patients willing to participate in the study.

2.2. Exclusion criteria

1. Exclusion of patients with comorbidities such as diabetes mellitus or any ocular diseases like corneal or lens opacities, causing media haze that impedes fundus assessment.
2. Exclusion of hypertensive patients under the age of 18 or those diagnosed with hypertension before 18 years of age.
3. Exclusion of pregnant women.
4. Exclusion of patients with preexisting retinal vascular disorders unrelated to hypertension.
5. Exclusion of patients taking medications known to have retinotoxic effects, such as chloroquine, ethambutol, isoniazid, or chemotherapy for cancer.
6. Exclusion of patients who declined to participate in the study.

Following the application of these inclusion and exclusion criteria, the study population comprised a total of 300 subjects.

A comprehensive medical history was obtained from all patients, including demographic information such as age, gender, known duration of hypertension, smoking history, and comorbidities such as stroke and chronic kidney disease (CKD). Additionally, the weight and height of all subjects were recorded to calculate their body mass index (BMI), classifying them as normal, overweight, or obese. Ocular examinations included measurements of unaided and best-corrected visual acuity (BCVA).

Normal blood pressure was defined as systolic blood pressure less than 130 mmHg and diastolic blood pressure less than 85 mmHg. Mild high blood pressure was defined as systolic blood pressure between 140-159 mmHg and diastolic blood pressure between 90-99 mmHg, moderate high blood pressure as systolic blood pressure ranging from 160-179 mmHg and diastolic blood pressure between 100-109 mmHg, and severe high blood pressure as systolic blood pressure exceeding 180 mmHg and diastolic blood pressure over 110 mmHg. Blood pressure was measured manually using a sphygmomanometer and stethoscope.

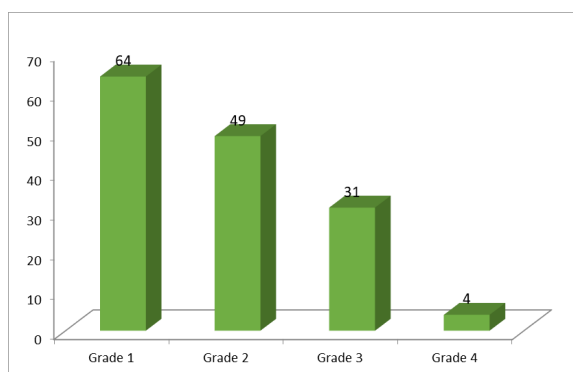
Anterior segment examination was conducted using a slit lamp biomicroscope. Pupils were dilated with tropicamide 0.8% and 5% phenylephrine hydrochloride ophthalmic solution, and fundus examination was performed using an indirect ophthalmoscope with a 20 D lens or a slit lamp with a 90 D lens. Hypertensive retinopathy was documented if present, and its severity was graded according to Keith Wagener's classification, which consists of four grades: slight arteriolar constriction (Grade 1), focal arteriolar narrowing with arteriovenous nicking (Grade 2), flame-shaped hemorrhages, cotton wool spots, and hard exudates (Grade 3), and optic disc swelling (Grade 4).¹⁰

3. Results

The data collected was entered into excel sheet and was analysed using SPSS version 25.0. Qualitative variables were expressed as frequencies (percentages) and quantitative variables as Mean±SD. Student's t-test was used to compare normally distributed continuous variables and proportions were compared using Chi-square test or Fisher exact test as applicable. P-value<0.05 was taken as statistically significant and p-value<0.01 as highly statistically significant.

Table 1 shows that the prevalence of hypertensive retinopathy was 49.33%. The mean age of the study participants was 63.42 years (SD=13.95 years). The mean age of the patients with hypertensive retinopathy was 69.09 years (SD=13.15 years) with majority of the patients belonging to the age group >60 years (61.63%), followed by the age group 51-60 years(40%), 41-50 years(26.67%), and 31-40 years (16.67%). The difference was found to be highly statistically significant (p<0.01).

Table 2 shows the sex distribution of all the study participants in which males were 186 (62%) while females were 114 (38%).



Graph 1: Distribution of Hypertensive retinopathy subjects according to the Keith Wagener Barker grading system

Graph 1 shows that 64(43.24%) patients had grade 1, 49(33.11%) had grade 2, 31(20.95%) had grade 3 and 4(2.7%) had grade 4 HR.

Table 3 shows that 34(22.97%) patients with Hypertensive retinopathy had hypertension for ≤5 years and 114(77.03%) had for >5 years. 34(22.97%) had Ischemic heart disease (IHD), 24(16.22%) had Chronic kidney disease (CKD) and 22(14.86%) had stroke. The difference was found to be highly statistically significant.

Table 4 shows the common risk factors such as age (69.09 years in Hypertensive retinopathy, 57.89 years without Hypertensive retinopathy), smoking in 56.76% in Hypertensive retinopathy, 26.32% without Hypertensive retinopathy. Regular exercise was seen in 22.97% patients with Hypertensive retinopathy patients and 65.79% in without Hypertensive retinopathy patients. Height and

weight of the subjects were recorded and BMI was calculated, and they were classified accordingly. BMI overweight was seen in 44.59% patients with Hypertensive retinopathy and 17.11% patients without Hypertensive retinopathy. Obesity was found in 37.84% patients with Hypertensive retinopathy. 85.15% patients with Hypertensive retinopathy had sedentary lifestyle whereas 47.37% patients without Hypertensive retinopathy had sedentary lifestyle. Duration of hypertension was 7.14 years and 3.59 years in patients with Hypertensive retinopathy and without Hypertensive retinopathy respectively.

4. Discussion

Hypertension is not only prevalent in the elderly but also among middle-aged individuals. Hypertensive retinopathy, a clinical manifestation, is a leading cause of visual impairment in adults with hypertension.^{11,12} It encompasses a range of retinal changes, pathologically linked to damage to retinal microvessels resulting from elevated blood pressure.¹³ The timely identification of alterations in retinal vasculature can provide insight into the underlying changes in the vascular systems of various target organs. Thus, the use of funduscopy by ophthalmologists serves as a window into the detection of damage to target organs, such as those in the cerebrovascular and cardiovascular systems, chronic kidney disease, pre-eclampsia, and other conditions. Retinal arteriolar stenosis, considered a hallmark of hypertensive retinopathy and a sign of target organ damage, underscores its significance in assessing the duration, severity, and prognosis of hypertension.¹⁴ A study conducted by Thiagarajah R et al. has suggested that screening for hypertensive retinopathy can be an indicator for assessing the risk of developing hypertensive strokes in the future.¹⁵ Furthermore, Biesenbach et al. study from 1994 showed that funduscopy and eye exams improve the indication for systemic therapy in the assessment of hypertension.¹⁶ In fact, a diagnosis of hypertensive retinopathy can help doctors pinpoint hypertensive patients who need more aggressive care.¹⁷ Hypertensive retinopathy is recognized as a marker for vascular disease and is associated with increased mortality.

In the current study, the prevalence of hypertensive retinopathy was found to be 49.33%. Comparatively, other studies have reported varying prevalence rates, such as Priyadarshini Cholera et al¹⁸ who observed a prevalence of 53.81% in Mumbai, Ifrath Nusaiba et al¹⁹ with a prevalence of 28.5% in Chennai, Erden et al²⁰ with a prevalence of 66.3%, and Kabedi et al,²¹ who identified an 83.6% prevalence in the African population. This latter study noted that chronic kidney disease (CKD) is the most significant factor for predicting severe hypertensive retinopathy. ST Godar²² reported a prevalence of 38.95% in Nepal, while Mondal R et al²³ in Bangladesh found a prevalence of 29.9%, Besharati MR et al²⁴ reported a prevalence of 39.9%

Table 1: Distribution of subjects according to age and prevalence of hypertensive retinopathy

Age(in years)	Total, n	With Hypertensive retinopathy (n=148)	Without Hypertensive retinopathy (n=152)	p-value
18-30	6	0(0)	6(100)	
31-40	12	2(16.67)	10(83.33)	
41-50	30	8(26.67)	22(73.33)	<0.001
51-60	80	32(40)	48(60)	
>60	172	106(61.63)	66(38.37)	
Total	300	148(49.33)	152(50.67)	

Values in n(%), % taken row wise, *p-value<0.01-highly statistically significant.

Table 2: Distribution of subjects according to gender

Sex	Frequency(n)	Percentage
Male	186	62
Female	114	38

Table 3: Distribution of study subjects according to comorbidities

Comorbidities	With Hypertensive Retinopathy n=148	Without Hypertensive Retinopathy n=152	p-value
Duration of Hypertension			
≤ 5 years	34(22.97)	112(73.68)	<0.001*
> 5 years	114(77.03)	40(26.32)	
Target organ damage			
Ischemic heart disease (IHD)	34(22.97)	2(1.32)	<0.001*
Stroke	22(14.86)	0(0)	
Chronic kidney disease(CKD)	24(16.22)	2(1.32)	

Values in n(%), *p-value<0.01-highly statistically significant

Table 4: Assessment of risk factors

Risk factors	With Hypertensive retinopathy (n=148)	Without Hypertensive retinopathy (n=152)	p-value
Age(years)	69.09±13.15 [#]	57.89±12.44 [#]	<0.001*
Smoking	84(56.76)	40(26.32)	<0.001*
Regular exercise	34(22.97)	100(65.79)	<0.001*
Overweight	66(44.59)	26(17.11)	<0.001*
Obese	56(37.84)	0(0)	<0.001*
Sedentary lifestyle	126(85.14)	72(47.37)	<0.001*
Duration of hypertension	7.14±3.02 [#]	3.59±2.44 [#]	<0.001*

Values in n(%), #-mean±SD, *p-value<0.01-highly statistically significant

in Iran, and Ray S et al²⁵ discovered a prevalence of 62.25% in West Bengal.

Concerning the distribution of hypertensive retinopathy grades among hypertensive patients, grade 1 and grade 2 were observed in 64 (43.24%) and 49 (33.11%) individuals, respectively, while 31 (20.95%) had grade 3, and 4 (2.7%) had grade 4. This pattern of hypertensive retinopathy in our study aligns with observations in other research. For instance, Godar ST et al²¹ reported higher proportions of grade 1 (7.36%) and grade 2 (17.86%) compared to grade 3 (10.52%) and grade 4 (3.15%). Similar patterns were noted by Ray S et al,²⁵ Cholera P et al,¹⁸ and Pun CB et al²⁶ in their respective studies. Additionally, Ifrath Nusaiba et al¹⁹ reported that the highest number of

hypertensive retinopathy patients had grade 1 (32), followed by grade 2 (16), with fewer cases of grade 3 and 4 (8 and 1, respectively). The relatively high prevalence in our study may be attributed to a lack of knowledge regarding hypertension and funduscopy, leading to delayed patient presentation, non-compliance with treatment regimens, a lack of follow-up visits, lower socioeconomic status, and inadequate care for senior citizens at home, all of which contribute to the higher prevalence in our society.

In our study, we observed that hypertensive retinopathy was more prevalent in men (62%) than in women (38%). Similar findings were reported in studies by Mondal R et al.²³ and Godar ST et al.,²² which indicated male predominance (64.1% vs. 35.9% and 40.0% vs. 37.7%,

respectively). In contrast, a study by Besharati MR et al. demonstrated a 1.4 times higher prevalence in women compared to men (45.8% vs. 32.6%). Other studies by Badhu BP et al.²⁷ and Modi P et al.²⁸ showed a female preponderance. However, studies by S Ray et al.²⁵ and Gupta et al.²⁹ noted no significant gender bias in hypertensive retinopathy prevalence. This variation in gender distribution may be attributed to risk factors, particularly the higher prevalence of smoking among men in our study.

The prevalence of hypertensive retinopathy was highest among individuals aged over 60, accounting for 106 cases (61.63%). It was followed by the age group of 51 to 60 years, with 32 cases (40%), and the age group of 41 to 50 years, with 8 cases (26.67%). The age group of 31 to 40 years had 2 cases (16.67%), while none of the patients aged 18 to 20 years showed signs of hypertensive retinopathy. This suggests that the prevalence of hypertensive retinopathy increases with age. A similar observation was made by Mondal R et al., who found a positive correlation between increasing age, particularly over 60 years, and a longer duration of hypertension (more than 5 years) with the presence of hypertensive retinopathy²³. Studies conducted by Modi P et al.²⁸ and Cholera P et al.¹⁸ also arrived at the same conclusion regarding the relationship between increasing age and the duration of hypertension. In contrast, Ifrath Nusaiba et al.¹⁹ found no statistically significant differences in the distribution of retinopathy among various age groups.

The study population was divided into two groups based on the duration of hypertension: less than 5 years and more than 5 years. Out of the 146 patients with hypertension for less than 5 years, 34 (22.97%) had hypertensive retinopathy. Among the 154 patients with hypertension for more than 5 years, 114 (77.03%) had hypertensive retinopathy. The prevalence of retinopathy was significantly higher in patients with a history of hypertension for more than 5 years compared to those with hypertension for 5 years or less. This result is consistent with earlier research, such as that by Ifrath Nusaiba et al,¹⁹ which found a connection between the frequency of hypertensive retinopathy and the length of hypertension. In accordance with the findings of our investigation, Erden et al²⁰ similarly came to the conclusion that both the degree and duration of hypertension contribute to the higher incidence of retinopathy.

A total of 36 individuals with ischemic heart disease (IHD), 34 of whom had retinopathy, and 22 with a history of stroke, all of whom displayed symptoms of retinopathy, had target organ damage. In addition, 24 of the 26 individuals with chronic kidney disease (CKD) also had retinopathy. These findings show that people with retinopathy had a considerably greater prevalence of target organ damage ($p < 0.001$).

These findings align with other studies, such as Ifrath Nusaiba et al¹⁹ and Mondal R et al,²³ both of which suggested that hypertensive retinopathy can serve as an indicator of target organ damage, along with left ventricular hypertrophy and renal failure. Suri MFK et al³⁰ reported a heightened risk of coronary artery disease (CAD) and stroke in the presence of retinal vascular disease after accounting for other contributing factors. S Ray et al. indicated that earlier stages of retinopathy can predict acute cerebrovascular events, while severe grades of retinopathy are indicative of renal morbidity.²⁵ Kolman SA and Muiesan ML conducted research indicating that systemic hypertension has the potential to harm the circulatory systems of the retina, heart, and kidneys. They noted that retinal funduscopy offers a non-invasive means to identify Hypertension Mediated Organ Damage, much like microalbuminuria and electrocardiography do.^{17,31} The study by Kolman SA et al. emphasized that hypertensive retinopathy is independently associated with an increased risk of stroke and all-cause cardiovascular disease (CVD), regardless of blood pressure and other cardiovascular risk factors.¹⁷ Additionally, studies by Mitchell P and Wang JJ et al³² showed a strong relationship between hypertensive retinopathy and stroke mortality.

Furthermore, in our study, we observed a higher prevalence of hypertensive retinopathy among individuals who were smokers, overweight, obese, and had a sedentary lifestyle. Conversely, individuals who engaged in regular exercise showed a lower incidence of hypertensive retinopathy. These findings align with those of Mondal R et al., who reported similar results in their study.²³ Additionally, Modi P et al. emphasized that smoking constitutes a significant risk factor associated with hypertensive retinopathy.²⁸

Given that the eye is the only organ where vascular changes related to systemic hypertension can be visually assessed through funduscopy, it is crucial for general practitioners and physicians to be aware of this condition. They should actively encourage patients to undergo periodic ophthalmic fundal evaluations to enable early detection and monitoring of the progression of hypertensive retinopathy.

5. Conclusion

The current study revealed that nearly half of the hypertensive patients exhibited signs of retinopathy, signifying suboptimal blood pressure control within this patient group. This outcome underscores the insufficient awareness, early detection, and aggressive treatment measures for this population. Notably, male gender, advancing age (especially above 60 years), extended hypertension duration, smoking, obesity, and a lack of physical activity emerged as significant risk factors for hypertensive retinopathy. It is imperative to implement stringent blood pressure control measures to prevent

target organ damage and vision impairment. Public education campaigns about hypertension and its associated consequences are warranted, emphasizing the importance of adhering to hypertension management and attending regular follow-up appointments with ophthalmologists.

However, it's important to acknowledge the study's limitations. Since it was conducted in a hospital setting, the findings are applicable to a limited population. Additionally, the study's duration was relatively short, and it did not explore potential correlations between the severity of hypertension and the grading of hypertensive retinopathy. Genetic and dietary factors were also not investigated.

6. Financial Support

None.


7. Conflicts of Interest

None.

References

1. The fifth report of the Joint National Committee on Detection, Evaluation, and Treatment of High Blood Pressure (JNC V). *Arch Intern Med.* 1993;153(2):154–83.
2. Wong TY, Klein R, Couper DJ, Cooper LS, Shahar E, Hubbard LD, et al. Retinal microvascular abnormalities and incident stroke: the Atherosclerosis Risk in Communities Study. *Lancet.* 2001;6(9288):1134–40.
3. Wong TY, Klein R, Sharrett AR, Duncan BB, Couper DJ, Tielsch JM. Retinal arteriolar narrowing and risk of coronary heart disease in men and women. The Atherosclerosis Risk in Communities Study. *JAMA.* 2002;287(9):1153–9.
4. Grosso A, Veglio F, Porta M, Grignolo FM, Wong TY. Hypertensive retinopathy revisited: some answers, more questions. *Br J Ophthalmol.* 2005;89(12):1646–54.
5. Baker ML, Hand PJ, Wang JJ, Wong TY. Retinal signs and stroke: revisiting the link between the eye and brain. *Stroke.* 2008;39(4):1371–9.
6. Ramsay LE, Williams B, Johnston GD, Macgregor GA, Poston L, Potter JF, et al. British Hypertension Society guidelines for hypertension management 1999: summary. *BMJ.* 1999;319(7210):630–5.
7. Walsh JB. Hypertensive retinopathy. Description, classification, and prognosis. *Ophthalmology.* 1982;89:1127–31.
8. Wong TY, Mitchell P. The eye in hypertension. *Lancet.* 2007;369(9559):425–35.
9. Marco ED, Aiello F, Lombardo M, Marino MD, Missiroli F, Mancino R, et al. A literature review of hypertensive retinopathy: systemic correlations and new technologies. *Eur Rev Med Pharmacol Sci.* 2022;26(18):6424–43.
10. Keith NM, Wagener HP, Barker NW. Some different types of essential hypertension: their course and prognosis. *Am J Med Sci.* 1974;268(6):336–45.
11. Wang J, Chen H, Zhang H, Yang F, Chen RP, Li YB, et al. The performance of a diabetic retinopathy risk score for screening for diabetic retinopathy in Chinese overweight/obese patients with type 2 diabetes mellitus. *Ann Med.* 2014;46(6):417–23.
12. Stryjewski TP, Papakostas TD, Vavvas D. Proliferative hypertensive retinopathy. *JAMA Ophthalmol.* 2016;134:345–6.
13. Kanski JJ, Bowling B. *Clinical Ophthalmology: A Systematic Approach.* UK: Elsevier Health Sciences; 2011.
14. Zhang Y, Zhao L, Li H, Wang Y. Risk factors for hypertensive retinopathy in a Chinese population with hypertension: The Beijing Eye study. *Exp Ther Med.* 2018;17(1):453–8.
15. Thiagarajah R, Kandasamy R, Sellamuthu P. Hypertensive Retinopathy and the Risk of Hemorrhagic Stroke. *J Korean Neurosurg Soc.* 2021;64(4):542–51.
16. Biesenbach G, Zazgornik J. High prevalence of hypertensive retinopathy and coronary heart disease in hypertensive patients with persistent microalbuminuria under short intensive antihypertensive therapy. *Clin Nephrol.* 1994;41(4):211–8.
17. Kolman SA, Sijl AMV, Sluijs F, Deree MAV. Consideration of hypertensive retinopathy as an important end-organ damage in patients with hypertension. *J Hum Hypertens.* 2017;31(2):121–5.
18. Cholera P, Pendse M. A study of prevalence of hypertensive retinopathy at tertiary health care center. *MedPulse Int J Med.* 2020;13(3):118–21.
19. Veeramani P, Nusaiba I. Prevalence of hypertensive retinopathy in hypertensive patients. *Int J Res Pharm Sci.* 2022;13(2):145–9.
20. Erden S, Bicakci E. Hypertensive retinopathy: Incidence, risk factors and comorbidities. *Clin Exp Hypertens.* 2012;34:397–401.
21. Kabedi NN, Mwanza JC, Lepira FB, Kayembe TK, Kayembe DL. Hypertensive retinopathy and its association with cardiovascular, renal and cerebrovascular morbidity in Congolese patients. *Cardiovasc J Afr.* 2014;25(5):228–32.
22. Godar ST, Kaini KR. Prevalence and Risk Factors of Hypertensive Retinopathy in Hypertensive Patients in a Tertiary Hospital of Gandaki Province of Nepal. *J Lumbini Med Coll.* 2020;8(2):270–4.
23. Mondal RN, Matin MA, Rani M, Hossain MZ, Shaha AC, Singh RB, et al. Prevalence and Risk Factors of Hypertensive Retinopathy in Hypertensive Patients. *J Hypertens.* 2017;6(2):241.
24. Besharati MR, Rastegar A, Shoja MR, Maybodi ME. Prevalence of retinopathy in hypertensive patients. *Saudi Med J.* 2006;27(11):1725–8.
25. Ray S, Sahu BK, Naskar S. Hypertensive retinal changes: It's prevalence and associations with other target organ damage. *Indian J Med Sci.* 2020;72(3):195–200.
26. Pun CB, Tuladhar S. Profile of Hypertensive Retinopathy in a Tertiary Center in Western Nepal. *J Gandaki Med Coll Nepal.* 2019;12(1):22–4.
27. Badhu BP, Shreshta JK. Hypertensive patients in eye OPD, TUTH. *J Inst Med.* 1998;20:188–92.
28. Modi P, Arsiwalla T. Hypertensive Retinopathy [Internet]. Treasure Island (FL): StatPearls Publishing; 2023.
29. Gupta RP, Gupta S, Gahlot A, Sukharamwala D, Vashi J. Evaluation of hypertensive retinopathy in patients of essential hypertension with high serum lipids. *Med J DY Patil Univ.* 2013;6(2):165–9.
30. Suri MFK, Qureshi IA. Hypertensive Retinopathy and Risk of Cardiovascular Diseases in a National Cohort. *J Vasc Interv Neurol.* 2008;1(3):75–8.
31. Muiesan ML, Salvetti M, Rizzoni D, Painsi A, Agabiti-Rosei C, Aggusti C, et al. Resistant hypertension and target organ damage. *Hypertens Res.* 2013;36(6):485–91.
32. Mitchell P, Wang JJ, Wong TY, Smith W, Klein R, Leeder SR. Retinal microvascular signs and risk of stroke and stroke mortality. *Neurology.* 2005;65(7):1005–9.


Author biography

Chethana Warad, Associate Professor  <https://orcid.org/0000-0002-6330-3872>

Ruben Roy Simon, M.B.B.S Student

Radhika Wani, M.B.B.S Student  <https://orcid.org/0009-0002-3727-8420>

Ruchi Singh, UG Student

Shivakrishna Pavuluri, UG Student  <https://orcid.org/0000-0002-5214-3842>

V A Kothiwale, Professor

Cite this article: Warad C, Simon RR, Wani R, Singh R, Pavuluri S, Kothiwale VA. Incidence and determinants of hypertensive retinopathy in hypertension patients at a teaching hospital in North Western Karnataka. *Indian J Clin Exp Ophthalmol* 2023;9(4):634-640.