

Content available at: <https://www.ipinnovative.com/open-access-journals>

Indian Journal of Clinical and Experimental Ophthalmology

Journal homepage: www.ijceo.org

Original Research Article

Analysis of subfoveal choroidal thickness alteration in relation to presence and severity of diabetic retinopathy

Shashi Jain¹, Shivani Gupta², Anamika Dwivedi¹, Aashi Jain¹, Manoj Tyagi^{2,*}¹Dept. of Ophthalmology, Shyam Shah Medical College, Rewa, Madhya Pradesh, India²Dept. of Ophthalmology, Government Medical College, Datia, Madhya Pradesh, India

ARTICLE INFO

Article history:

Received 08-05-2023

Accepted 29-05-2023

Available online 29-09-2023

Keywords:

Subfoveal choroidal thickness

Diabetic retinopathy

Diabetic choroidopathy

ABSTRACT

Aim: To assess alteration in subfoveal choroidal thickness in diabetics with or without diabetic retinopathy (DR) and compare it with severity of DR.**Materials and Methods:** All patients attending the ophthalmic OPD fulfilling inclusion and met no exclusion criteria were enrolled in this study. All eyes underwent comprehensive and standardized ophthalmic examination. The SFCT (subfoveal choroidal thickness) was measured using high definition enhanced depth imaging spectral domain optical coherence tomography using Cirrus HD OCT Model 500.**Result:** The mean SFCT in diabetics was significantly lesser than age matched controls. It was also significantly lesser in diabetics with diabetic retinopathy as compare to diabetics without diabetic retinopathy. The SFCT was significantly decreased with increasing severity of diabetic retinopathy. The mean SFCT was also decreased in diabetic with diabetic macular edema (DME) and PRP treated DR as compared to diabetic without DME and PRP untreated DR respectively.**Conclusion:** The SFCT could be a marker of severity of diabetic retinopathy. It was decreased in diabetics as compared to nondiabetics and was significantly decreased with increasing severity of DR and in presence of DME. PRP also significantly decreases SFCT.This is an Open Access (OA) journal, and articles are distributed under the terms of the [Creative Commons Attribution-NonCommercial-ShareAlike 4.0 License](https://creativecommons.org/licenses/by-nc-sa/4.0/), which allows others to remix, tweak, and build upon the work non-commercially, as long as appropriate credit is given and the new creations are licensed under the identical terms.For reprints contact: reprint@ipinnovative.com

1. Introduction

Diabetic retinopathy is a prevalent sight threatening disorder of retina which is caused by abnormalities in capillaries and vessels of retina in patients with diabetes. It is the worldwide leading cause of loss of vision.¹ The development of macular edema and proliferative retinopathy are among the important cause of impairment of vision.^{1,2}

The choroid is highly vascularised tissue that provide blood supply to outer retina, including photoreceptors and retinal pigmented epithelial cells (RPE) especially in fovea region where there is no retinal vasculature.³ It is the only source of oxygen and nutrients to outer retina and RPE

and plays an important role in the pathophysiology of the diabetic retinopathy(DR).

Clinical and experimental findings have suggested that choroidal vasculopathy in diabetes might play a role in progression and severity of DR.⁴⁻⁶ Although diabetic retinopathy is a disease that primarily affect microvasculature of retina, the concept of diabetic choroidopathy came into light when it was first established that there is significantly higher loss of choroidocapillaris in diabetic subjects as compared to aged control healthy controls.⁷ Several abnormalities of choroid including vascular degeneration, obstruction of choriocapillaries, choroidal aneurysm and choroidal neovascularisation have been reported in histological studies of diabetic eye.^{4,7,8}

* Corresponding author.

E-mail address: drttyagimanoj@gmail.com (M. Tyagi).

Choroidal angiopathy has been received less research attention. Until the recent time choroid could have been evaluated only by laser Doppler flowmetry (Doppler flowmeter has also shown decreased choroidal perfusion),⁹ ultrasound and indocyanine green angiography.¹⁰ The techniques though useful for finding vascular abnormalities or any changes in choroidal blood flow but they did not give any anatomical information about RPE or choroidal layers.

Spectral domain optical coherence tomography (SD-OCT) now provides a high quality high resolution cross sectional images of macula. Additionally, enhanced depth imaging (EDI) software provides a very reliable and reproducible estimation of the choroidal thickness. EDI-OCT is unique in having capability of tracking fovea, was recently described as a new method to measure thickness of choroidal in normal and pathologic states.^{11–16}

Studies on association of thickness of choroid with diabetes or with progression of diabetic retinopathy have shown contradictory results. Some studies have shown increase in choroidal thickness^{17,18} while other have shown decrease in thickness of choroid^{19–23} in patient with diabetes or with increase in severity of DR.

In view of scarcity of definitive evidence of change in choroidal thickness in association with diabetes/diabetic retinopathy we have done cross-sectional study to compare subfoveal choroidal thickness in nondiabetic and diabetic also in various grades of diabetic retinopathy.

2. Materials and Methods

All patients having diabetes coming to ophthalmology OPD in a tertiary care center in central India from February 2019 to August 2020 who fulfil the given inclusion criteria as well as met no exclusion criteria were included in the study.

2.1. Inclusion criteria

1. Age more than or equal to 18 years.
2. Known diabetic with or without diabetic retinopathy.
3. Age matched healthy controls.

2.2. Exclusion criteria

1. History of vitreoretinal surgery
2. Vitreoretinal disorders other than diabetic retinopathy currently or in past.
3. Cataract surgery in past 6 months.
4. Spherical equivalent of refractive error more than or equal to ± 6 D.
5. Any media opacity likely to cause signal strength attenuation in OCT.
6. Signal strength $< 6/10$ in OCT.
7. Panretinal photocoagulation (PRP) treated within 3 months.
8. History of intravitreal anti-VEGF.

After taking a written informed consent a comprehensive history has been taken that included a detailed ocular and systemic (duration of diabetes and antidiabetic medication) history, demography (age, sex) laterality, systemic comorbidities (hypertension, kidney disease). General examination and systemic examination of associated systemic diseases was done.

The ophthalmic examination included assessment of BCVA on Snellens which was then converted into log MAR value, intraocular pressure, anterior segment examination, fundus examination, digital fundus photography, fundus fluorescein angiography (if required), OCT using Cirrus HD OCT Model 500 were done and relevant investigations were advised.

As per ETDRS classification, patients were categorized into mild, moderate and severe non-proliferative diabetic retinopathy (NPDR) and proliferative diabetic retinopathy (PDR). Each patient with diabetic retinopathy were also grouped on the basis of presence or absence of diabetic macular edema (DME). Patients were also divided into PRP untreated DR and PRP treated DR with history of last session of PRP of more than 3 months.

The SFCT was measured using EDI-HDOCT technique and the scan passing through foveola, was selected. Measurement was taken as the vertical distance between hyper-reflective line of Bruch's membrane to the innermost hyper-reflective line of chorio-scleral interface. (Figure 1)

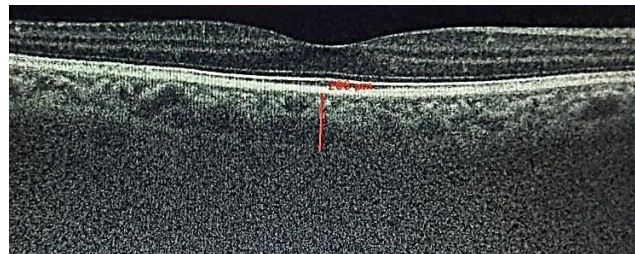


Fig. 1: Showing SFCT in enhanced depth imaging high definition raster scan of OCT in moderate diabetic retinopathy patient.

2.3. Statistical analysis

The collected data were laid in computer in MS excel and the analysis was done utilizing the SPSS (Statistical Package for the Social Sciences version 20) for statistics. Student t-test and one way ANOVA were applied to analyze quantitative variables.

3. Result

During the course of study, a total of 400 eyes of 200 patients were included in this study which were categorized as 320 eyes of patients having diabetes and 80 eyes of age matched healthy controls.

Three twenty eyes were divided on the basis of severity of DR into diabetics with no diabetic retinopathy (50 eyes), mild NPDR (60 eyes), moderate NPDR (62 eyes), severe NPDR (70 eyes), PDR (48 eyes) and PRP treated DR (30 eyes). On the basis of presence of DME, patients were categorized as 75 eyes with DME and 195 eyes without DME.

Patients with DR were also divided on the basis of history of last session PRP more than 3 months into PRP treated DR (30 eyes) and PRP untreated DR (240 eyes).

The base line features of cases and controls including mean age, sex, duration of diabetes and mean BCVA were measured.

The mean SFCT in diabetics and age matched healthy controls were $259.93 \pm 53.7 \mu\text{m}$ and $368.68 \pm 10.18 \mu\text{m}$ respectively. It was significantly lesser in diabetics than age matched healthy controls having p value <0.001 .

The mean SFCT values in diabetics without DR was $345.6 \pm 9.11 \mu\text{m}$ and diabetics with DR was $244.07 \pm 42.29 \mu\text{m}$. It was significantly greater in diabetic without DR as compared to diabetic with DR (p value <0.001).

While measuring SFCT in different grades of DR, the mean SFCT values were no DR, mild, moderate and severe NPDR and PDR were $345.60 \pm 9.11 \mu\text{m}$, $302.28 \pm 19.19 \mu\text{m}$, $266.56 \pm 15.46 \mu\text{m}$, $227.27 \pm 8.47 \mu\text{m}$ and $201.4 \pm 7.77 \mu\text{m}$ respectively. It implied that SFCT decreased significantly as the severity of DR increased with p value <0.001 . The SFCT further decreased significantly in PRP treated eyes (mean SFCT= $188.63 \pm 10.22 \mu\text{m}$) with p value <0.001 .

The mean SFCT values in diabetic without DME ($267.09 \pm 56.82 \mu\text{m}$) and diabetic with DME ($236.56 \pm 32.62 \mu\text{m}$) showed significant differences, it was significantly greater in diabetic without DME than diabetic with DME (p value <0.001).

The mean SFCT in PRP untreated DR eyes and PRP treated DR were $251 \pm 39.58 \mu\text{m}$ and $188.63 \pm 10.22 \mu\text{m}$ respectively showed that it significantly greater in PRP untreated DR than PRP treated DR with p value <0.001 .

4. Discussion

Diabetic retinopathy is the common sight threatening retinopathy. It is the worldwide leading cause of loss of vision.¹ The major cause of visual impairment are development of macular edema and proliferative retinopathy.^{1,2} The choroid is highly vascularised tissue that provide blood supply to outer retina, including photoreceptors and RPE especially in fovea region where there is no retinal vasculature.³ It is the only source of oxygen and nutrients to outer retina and RPE and plays an important role in the pathophysiology of the DR.

While comparing SFCT in diabetics with age matched healthy controls, the mean SFCT was significantly greater in eyes of healthy controls as compare to eyes of patients having history of diabetes mellitus. The reason for thinning

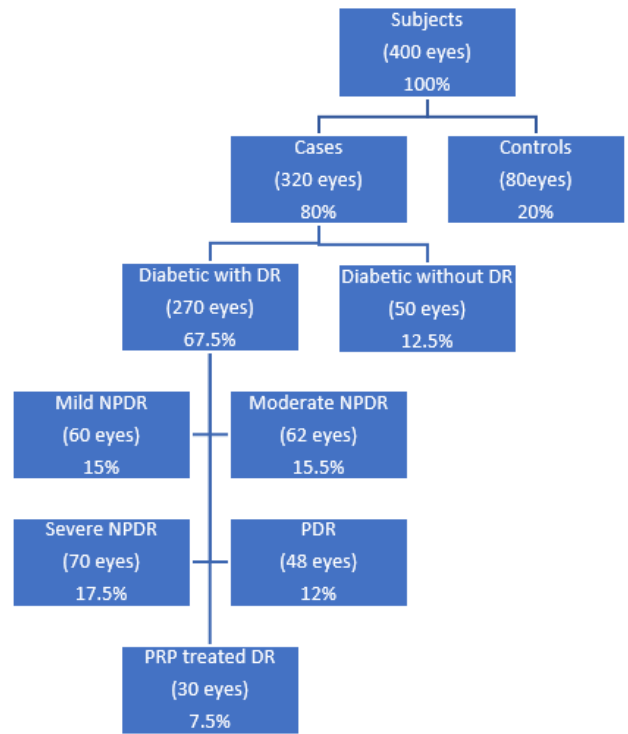


Fig. 2: Showing distribution of patients

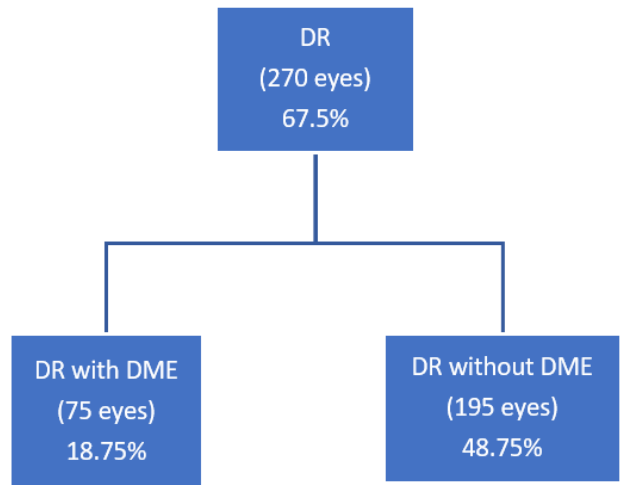


Fig. 3: Showing distribution of patients according to presence of DME

of choroid might be as a result of thinning and dropout of choroidal vessels due to luminal narrowing of capillaries in diabetic retinopathy. Our findings were in consistent with previous studies done by Sudhalkar A et al,²⁴ Verma A et al²⁵ and Wang X et al.²⁶ While Wang H et al²⁷ found no significant difference between two groups in their study.

Comparison of SFCT in diabetics with and without DR revealed that the mean SFCT was significantly greater in diabetic with no DR group as compare to diabetic with DR

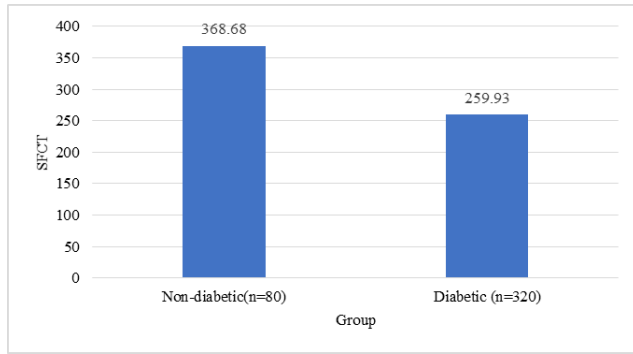


Fig. 4: Showing SFCT in non-diabetics and diabetics

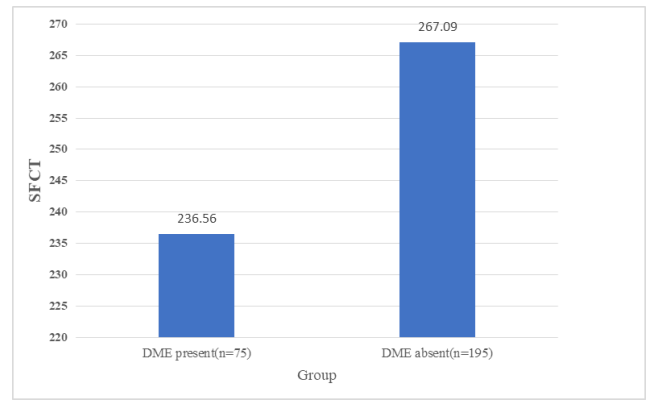


Fig. 7: Showing SFCT in diabetic with and without DME

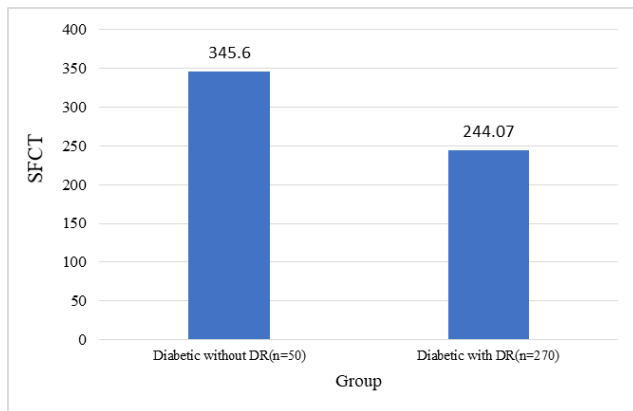


Fig. 5: Showing SFCT in diabetic with and without diabetic retinopathy

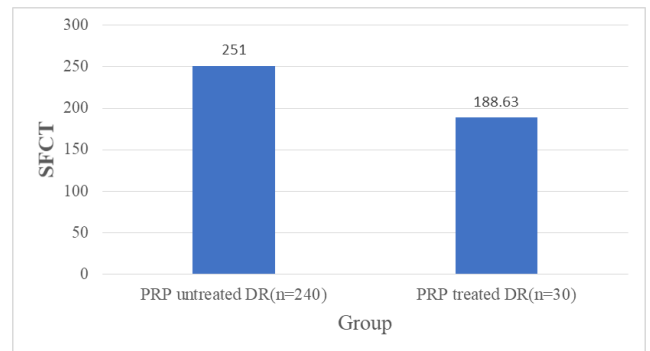


Fig. 8: Showing SFCT in PRP treated and PRP untreated DR

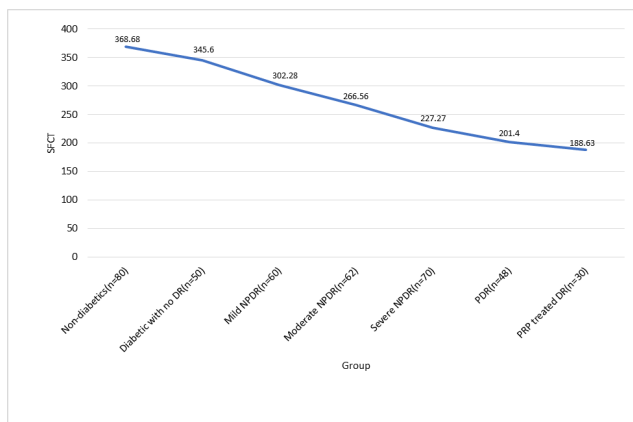


Fig. 6: Showing trend of SFCT with severity of DR

group. The finding in our study were consistent with study done by Sudhalkar A et al²⁴ and Ambiya V et al.²⁸

When SFCT in various grades of DR decreased significantly as the severity of diabetic retinopathy increased. It further decreased significantly in PRP treated eyes. Wang S et al²⁹ and Sudhalkar A et al²⁴ also found similar observation. Ambiya V et al²⁸ noted a significant moderately negative correlation of SFCT with severity of DR i.e.as compare to healthy control SFCT decreased in mild NPDR and moderate NPDR but not statistically significant however decrease in severe NPDR and PDR was statistically significant. Wang H et al²⁷ and Rewbury R et al³⁰ found that SFCT significantly increase with increasing severity of DR as compare to diabetic eyes and healthy controls.

The mean SFCT was found to be significantly greater in eyes without DME as compare with eyes with DME (p value<0.001). Our finding was consistent with finding noticed by Querques G et al.¹⁹ The reduced SFCT may cause hypoxia of retinal tissues which leads to increased expression of VEGF in RPE, pericytes and microvascular endothelial cells and may induce breakdown of blood retinal barrier, that forms the basis of diabetic macular edema. Sudhalkar A et al²⁴ found no significant difference between two groups, while Kim JT et al¹⁸ found increase in SFCT in

DME group.

The SFCT was compared in PRP treated DR eyes with PRP untreated DR eyes which was found to be significantly greater in PRP untreated DR as compare with PRP treated DR. Similar observation was noted by Kang HM et al²¹ and Kim JT et al.¹⁸ Wang H et al²⁷ also found greater mean SFCT in PRP untreated DR as compare with PRP treated DR but that difference was not statistically significant. Sudhalkar A et al²⁴ observed no significant difference in between PRP untreated DR and PRP treated DR.

PRP causes photoreceptor cells and RPE coagulation, also affects choriocapillaris. It also causes obliteration of choriocapillaris, and the choroidal blood flow is also significantly slower in PRP-treated eyes. In addition to impairment of choroidal circulation caused by PRP itself, improved inner retinal layers oxygenation and decreased VEGF secretion may also contribute to decreased permeability of choroid and alteration of choroidal autoregulation which results in generalized thinning of choroid. Thus, both directly and indirectly, various choroidal changes produced by PRP, may affect choroidal circulation.

5. Limitations

1. Owing to the smaller sample size generalizability of results is not feasible to diabetic population.
2. The measurement of subfoveal choroidal thickness was done manually so there might be inter-observer variation in measurement of thickness.
3. The measurement of subfoveal choroidal thickness may not be precise in eyes that did not show clear outer limit of choroid in OCT.
4. Due to shadowing effect of overlying fluid accumulation in retinal layers, it was difficult to measure subfoveal choroidal thickness.

6. Conclusion

We conclude that the SFCT could be a marker of severity of diabetic retinopathy. It was decreased in diabetics as compared to nondiabetics and was significantly decreased with increasing severity of DR and in presence of DME. PRP also significantly decreases SFCT.

7. Conflict of Interest

None declared.

8. Source of Funding

None.

References

1. Moss SE, Klein R, Klein BE. The 14-year incidence of visual loss in a diabetic population. *Ophthalmology*. 1998;105(6):998–1003. doi:10.1016/S0161-6420(98)96025-0.
2. Klein R, Klein BE, Moss SE, Cruickshanks KJ. The Wisconsin Epidemiologic Study of diabetic retinopathy. XIV. Ten-year incidence and progression of diabetic retinopathy. *Arch Ophthalmol*. 1994;112(9):1217–28. doi:10.1001/archoph.1994.01090210105023.
3. Nickla DL, Wallman J. The multifunctional choroid. *Prog Retin Eye Res*. 2010;29(2):144–68. doi:10.1016/j.preteyeres.2009.12.002.
4. Hidayat AA, Fine BS. Diabetic choroidopathy. Light and electron microscopic observations of seven cases. *Ophthalmology*. 1985;92(4):512–22.
5. Weinberger D, Kramer M, Priel E, Gatton DD, Axer-Siegel R, Yassur Y, et al. Indocyanine green angiographic findings in nonproliferative diabetic retinopathy. *Am J Ophthalmol*. 1998;126(2):238–47. doi:10.1016/s0002-9394(98)00148-2.
6. Shiragami C, Shiraga F, Matsuo T, Tsuchida Y, Ohtsuki H. Risk factors for diabetic choroidopathy in patients with diabetic retinopathy. *Graefes Arch Clin Exp Ophthalmol*. 2002;240(6):436–42.
7. Cao J, McLeod S, Merges CA. Choriocapillaris degeneration and related pathologic changes in human diabetic eyes. *Arch Ophthalmol*. 1998;116(5):589–97. doi:10.1001/archoph.116.5.589.
8. Fukushima I, McLeod DS, Luttj G. Intrachoroidal microvascular abnormality: a previously unrecognized form of choroidal neovascularization. *Am J Ophthalmol*. 1997;124(4):473–87. doi:10.1016/s0002-9394(14)70863-3.
9. Regatieri CV, Branchini L, Fujimoto JG, Duker JS. Choroidal imaging using spectral-domain optical coherence tomography. *Retina*. 2012;32(5):865–76. doi:10.1097/IAE.0b013e318251a3a8.
10. Nagaoka T, Kitaya N, Sugawara R, Yokota H, Mori F, Hikichi T, et al. Alteration of choroidal circulation in the foveal region in patients with type 2 diabetes. *Br J Ophthalmol*. 2004;88(8):1060–3.
11. Spaide RF, Koizumi H, Pozzoni MC. Enhanced depth imaging spectral-domain optical coherence tomography. *Am J Ophthalmol*. 2008;146(4):496–500.
12. Margolis R, Spaide RF. A pilot study of enhanced depth imaging optical coherence tomography of the choroid in normal eyes. *Am J Ophthalmol*. 2009;147(5):811–5.
13. Fujiwara T, Imamura Y, Margolis R. Enhanced depth imaging optical coherence tomography of the choroid in highly myopic eyes. *Am J Ophthalmol*. 2009;148(3):445–50. doi:10.1016/j.ajo.2009.04.029.
14. Imamura Y, Fujiwara T, Margolis R, Spaide RF. Enhanced depth imaging optical coherence tomography of the choroid in central serous chorioretinopathy. *Retina*. 2009;29(10):1469–73. doi:10.1097/IAE.0b013e3181be0a83.
15. Spaide RF. Age-related choroidal atrophy. *Am J Ophthalmol*. 2009;147(5):801–10. doi:10.1016/j.ajo.2008.12.010.
16. Spaide RF. Enhanced depth imaging optical coherence tomography of retinal pigment epithelial detachment in age-related macular degeneration. *Am J Ophthalmol*. 2009;147(4):644–52. doi:10.1016/j.ajo.2008.10.005.
17. Xu J, Xu L, Du K, Shao L, Chen C, Zhou J, et al. Subfoveal choroidal thickness in diabetes and diabetic retinopathy. *Ophthalmology*. 2013;120(10):2023–8.
18. Kim JT, Lee DH, Joe SG, Kim JG, Yoon YH. Changes in choroidal thickness in relation to the severity of retinopathy and macular edema in type 2 diabetic patients. *Invest Ophthalmol Vis Sci*. 2013;54(5):3378–84. doi:10.1167/iovs.12-11503.
19. Querques G, Lattanzio R, Querques L, Turco CD, Forte R, Pierro L. Enhanced depth imaging optical coherence tomography in type 2 diabetes. *Invest Ophthalmol Vis Sci*. 2012;53(10):6017–24. doi:10.1167/iovs.12-9692.
20. Vujosevic S, Martini F, Cavarzeran F, Pilotto E, Midena E. Macular and peripapillary choroidal thickness in diabetic patients. *Retina*. 2012;32(9):1781–90.
21. Kang HM, Lee NE, Choi JH, Koh HJ, Lee SC. Significant reduction of both peripapillary and subfoveal choroidal thickness after panretinal photocoagulation in patients with type 2 diabetes. *Retina*. 2018;38(10):1905–12.
22. Regatieri C, Branchini L, Carmody J, Fujimoto J, Duker J. Choroidal thickness in patients with diabetic retinopathy analyzed by spectral-domain optical coherence tomography. *Retina*. 2012;32(3):563–8.

23. Adhi M, Brewer E, Waheed N, Duker J. Analysis of morphological features and vascular layers of choroid in diabetic retinopathy using spectral-domain optical coherence tomography. *JAMA Ophthalmol.* 2013;131(10):1267–74.
24. Sudhalkar A, Chhablani JK, Venkata A, Raman R, Rao PS, Jonnadula GB, et al. Choroidal thickness in diabetic patients of Indian ethnicity. *Indian J Ophthalmol.* 2015;63(12):912–6.
25. Verma A, Nagpal M, Mehrotra N. In Vivo Assessment of Choroid in Diabetic Retinopathy by Enhanced Depth Imaging in Spectral Domain Optical Coherence Tomography. *Asia Pac J Ophthalmol (Phila).* 2016;5(5):319–23. doi:10.1097/APO.0000000000000204.
26. Wang X, Li S, Li W, Hua Y, Wu Q. Choroidal Variations in Diabetic Macular Edema: Fluorescein Angiography and Optical Coherence Tomography. *Curr Eye Res.* 2018;43(1):102–8. doi:10.1080/02713683.2017.1370115.
27. Wang H, Tao Y. Choroidal structural changes correlate with severity of diabetic retinopathy in diabetes mellitus. *BMC Ophthalmol.* 2019;19(1):186. doi:10.1186/s12886-019-1189-8.
28. Ambiya V, Kumar A, Baranwal VK, Kapoor G, Arora A, Kalra N, et al. Change in subfoveal choroidal thickness in diabetes and in various grades of diabetic retinopathy. *Int J Retina Vitreous.* 2018;4:34. doi:10.1186/s40942-018-0136-9.
29. Wang S, Lin S, Zheng Y, Di F, Cao X, Liu C, et al. Association of choroidal thickness with diabetic retinopathy at different stages. *Zhonghua Yi Xue Za Zhi.* 2015;95(32):2584–8.
30. Rewbury R, Want A, Varughese R, Chong V. Subfoveal choroidal thickness in patients with diabetic retinopathy and diabetic macular oedema. *Eye.* 2016;30(12):1568–72.

Author biography

Shashi Jain, Professor & Head

Shivani Gupta, Senior Resident

Anamika Dwivedi, Associate Professor

Aashi Jain, Associate Professor

Manoj Tyagi, Associate Professor

Cite this article: Jain S, Gupta S, Dwivedi A, Jain A, Tyagi M. Analysis of subfoveal choroidal thickness alteration in relation to presence and severity of diabetic retinopathy. *Indian J Clin Exp Ophthalmol* 2023;9(3):319-324.