

Content available at: <https://www.ipinnovative.com/open-access-journals>

Indian Journal of Clinical and Experimental Ophthalmology

Journal homepage: [www.ijceo.org](http://www.ijceo.org)

## Case Report

# Bilateral retinitis as the initial presentation of subacute sclerosing panencephalitis

Anu Jain<sup>1</sup>, Apoorva Jain<sup>2</sup>, Snigdha Sen<sup>1</sup>, Mahipal Singh Yadav<sup>1,\*</sup>,  
Rajendra Prakash Maurya<sup>3</sup>

<sup>1</sup>Dept. of Ophthalmology, Sarojini Naidu Medical College, Agra, Uttar Pradesh, India

<sup>2</sup>Dept. of Nephrology, Sarojini Naidu Medical College, Agra, Uttar Pradesh, India

<sup>3</sup>Regional Institute of Ophthalmology, IMS, Banaras Hindu University, Varanasi, Uttar Pradesh, India



### ARTICLE INFO

#### Article history:

Received 20-05-2023

Accepted 06-06-2023

Available online 30-06-2023

#### Keywords:

Retinitis

SSPE

Panencephalitis

### ABSTRACT

Subacute sclerosing panencephalitis (SSPE) is a ravaging disease of the central nervous system caused by persistent mutant measles virus. The diagnosis of SSPE is based on characteristic clinical and EEG findings and demonstration of elevated antibody titres against measles in cerebrospinal fluid. SSPE may have atypical clinical features at the onset. Herein, we report an atypical case of SSPE in an adolescent with bilateral retinitis as the initial presenting feature. The disease progressed with an appearance of cognitive worsening, myoclonic jerks, periodic high amplitude generalized complexes on EEG, and elevated titers of measles antibodies in cerebrospinal fluid leading to the final diagnosis of SSPE. The case warrants a high degree of suspicion on ophthalmologist's part to clinch the definitive diagnosis of not so common deadly disease.

This is an Open Access (OA) journal, and articles are distributed under the terms of the [Creative Commons Attribution-NonCommercial-ShareAlike 4.0 License](https://creativecommons.org/licenses/by-nc-sa/4.0/), which allows others to remix, tweak, and build upon the work non-commercially, as long as appropriate credit is given and the new creations are licensed under the identical terms.

For reprints contact: [reprint@ipinnovative.com](mailto:reprint@ipinnovative.com)

## 1. Introduction

Subacute sclerosing panencephalitis (SSPE) is a progressive neurodegenerative disorder of childhood and early adolescence caused by the persistent mutant measles virus.<sup>1</sup> SSPE, though rare, has been variably reported from all parts of the world. A recent study from the USA reported an incidence of 6.5 to 11 cases per 100,000 acute measles infections amounting to an SSPE risk of 1 in 9100 to 15400 cases of measles.<sup>2</sup> Miller calculated an annual incidence of 4 cases per 100,000 cases of measles in England and Wales.<sup>3</sup> The annual incidence of SSPE is still quite high in the developing countries. Serological studies from India have reported an annual incidence as high as 21 per million population.<sup>4,5</sup>

Cognitive impairment, as loss of memory and thinking skills, myoclonus, ataxia and changes in personality and behaviour are the usual initial features of SSPE seen in around 80-97% of cases.<sup>6</sup> Ocular changes may occur in up to 42-50% of cases of SSPE.<sup>1,7</sup> Only a few case have been reported in the literature, which have presented with visual complains ahead of neuronal involvement. After obtaining written informed consent from patient's guardians, we report a case that presented with acute vision loss and remained a diagnostic challenge, until he developed typical clinical manifestations of SSPE.

## 2. Case Report

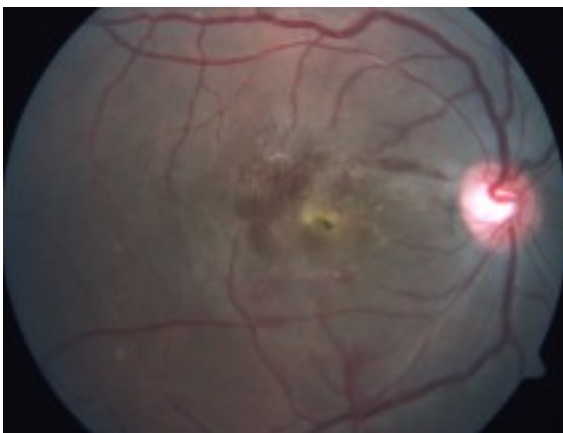
An immunocompetent 16-year old boy presented in our Ophthalmology OPD with complaint of blurred vision in his right eye for the past two days. There was no associated history of redness, pain or trauma. Neither was there any history of fever, abnormal movements, altered

\* Corresponding author.

E-mail address: [myadav.9758@gmail.com](mailto:myadav.9758@gmail.com) (M. S. Yadav).

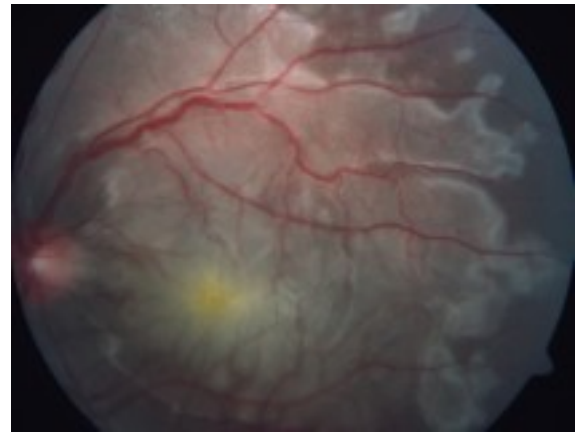
mentation or behavioral changes. Mother recalled infection with Measles at about 8 months of age. There was no history of any other chronic illness in the child or his family. His family belonged to low socio-economic strata and had non-vegetarian dietary habits.

He was afebrile, and general and neurologic examinations were normal. Best-corrected visual acuity was 10/200 in the right eye (RE) and 20/20 in the left eye (LE). Pupillary examination was normal with no anisocoria and no afferent pupillary defect. Slit lamp biomicroscopy and intraocular pressure in both eyes was normal. Fundus examination in the RE showed a patch of retinitis with subretinal haemorrhages and exudation in the macular area while the LE was normal. After six days, the child complained of further deterioration of vision in the RE and some vision loss in the LE as well. On examination, his visual acuity had decreased to perception of hand movements in the RE and 20/40 in the LE. Fundus examination of the RE showed necrotic changes in the existing lesion with macular hole formation and retinal pigment epithelium (RPE) atrophy. (Figure 1) In the LE, multiple fresh localized patches of chorioretinitis with sub retinal haemorrhages and exudates were seen at the posterior pole and mid-periphery (Figures 2 and 3). Early and mid phases of fluorescein angiography (FA) showed obscuration of choroid details due to retinal clouding secondary to retinitis. Late phase revealed multiple hyperfluorescent lesions in the area of retinitis and at the temporal margin of the disc in the LE. Late staining in the area of retinitis was noted. The dye was also seen entering and staining the venous wall signifying damage to the endothelium of the veins (Figure 4).

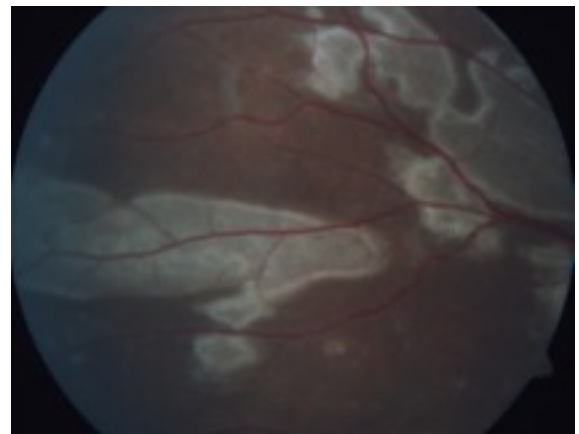


**Fig. 1:** Right eye, depicting resolving phase of retinitis with formation of macular hole, secondary RPE atrophy and subretinal hemorrhages

Clinical worsening continued despite the treatment with intravenous acyclovir and intravitreal gancyclovir. After about 25 days of initial presentation, patient developed left sided weakness and severe postural instability. Patient



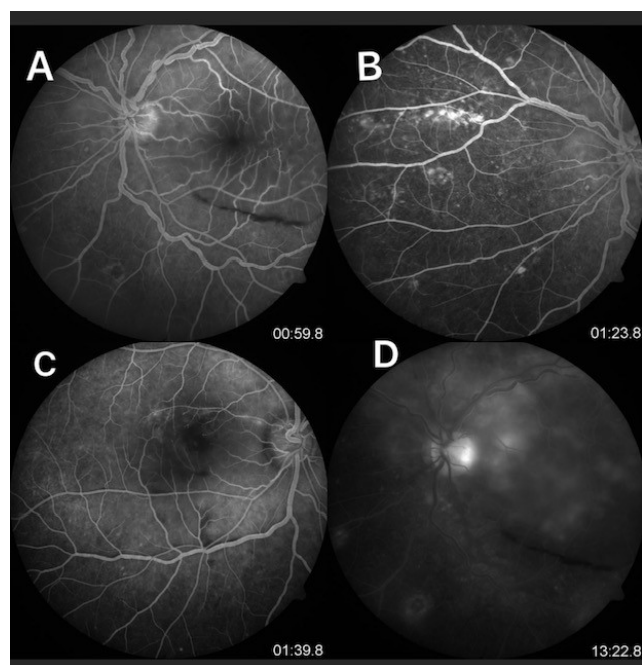
**Fig. 2:** Left eye, acute phase of geographic pattern retinitis with severe involvement of macula and engorgement of retinal veins



**Fig. 3:** Left eye, multiple isolated patches of retinitis with well defined margins visible up to far periphery in the nasal retina

became lethargic with decreased talkitiveness and low volume speech. Both eyes had no perception of light with fixed, dilated pupils as optic atrophy had set in. Myoclonic jerks were noticed in the left extremities. There was no bladder involvement and all other cranial nerves, except optic nerves, were intact.

Of the lab tests, the complete blood counts and Mantoux test were inconclusive while erythrocyte sedimentation rate and C - reactive protein were marginally high. Serum cytomegalovirus (CMV) IgG was positive. Angiotensin converting enzyme, c-antinuclear cytoplasmic antibody (ANCA), p-ANCA and antinuclear antibody (ANA) were negative. Vitreous tap polymerase chain reaction (PCR) for CMV/Varicella zoster virus (VZV)/ Herpes simplex virus (HSV) was negative. Serology for human immunodeficiency virus (HIV), Toxoplasma, CMV, Japanese Encephalitis (JE) virus and Scrub Typhus was also negative. Cerebrospinal fluid (CSF) showed 25 cells/mm<sup>3</sup>(100% lymphocytes), 79.70 mg/mL protein, and



**Fig. 4:** FA images: (A,B): Left eye, early and mid phases showing multiple hyper fluorescent lesions in the area of retinitis in central and nasal retina along with involvement of the temporal margin of the disc; C): Right eye, mid phase showing patchy sheathing of veins; D): Left eye, late phase showing patchy staining of retinitis lesions and veins

56.0 mg/dL glucose and negative results for Gram, acid-fast and India Ink stains and negative polymerase chain reaction (PCR) for HSV, VZV, CMV, JE and Mycobacterium tuberculosis. Repeat CSF for anti-measles IgG turned out positive. Serum anti-measles IgG antibodies were also positive.

Initial magnetic resonance imaging (MRI) head showed subtle hyperintensity in fluid-attenuated inversion recovery (FLAIR) images in right parieto-occipital region while an MRI orbit was inconclusive. Subsequent MRI depicted ill-margined areas of hyperintensity involving the cortex in both the frontal, right fronto-parietal and right temporo-occipital region on T2-weighted and turbo inversion recovery magnitude (TIRM) sequences. Involvement of white matter was seen in the right parieto-occipital region. Serial electroencephalography (EEG) showed periodic long interval and bilaterally synchronous discharges.

Initial management included posterior subtenon injection of Triamcinolone acetonide, intravenous Acyclovir and intravitreal Gancyclovir. Subacute Sclerosing Panencephalitis with atypical features was subsequently diagnosed and the patient was treated with intrathecal alpha interferon, Isoprinosine and antiepileptic medications. Patient eventually got confined to bed with loss of any vision, speech and cognitive functions.

### 3. Discussion

Most of the patients with SSPE have a history of primary measles infection at an early age. Children infected with measles under the age of one year carry a 16 times greater risk of SSPE, than those infected at age five years or later.<sup>3</sup> SSPE is clinically characterized by an insidious onset of intellectual deterioration and behavioral changes followed by myoclonus and ultimately complete neurologic decline. The diagnosis is based upon characteristic clinical manifestations, the presence of characteristic periodic EEG discharges, and demonstration of raised antibody titre against measles in the plasma and cerebrospinal fluid. Atypical form of SSPE occurs in about 10% of all patients.<sup>8</sup> Unusual age at onset, presentation with visual loss, seizures or other focal symptoms, rapid course and lack of SSPE-specific EEG pattern are all atypical features of the disease.

Of all the ocular findings of SSPE, cortical blindness, disc oedema (papilledema and papillitis), optic atrophy or temporal pallor and nystagmus readily imply a more detailed neurological work-up,<sup>9</sup> and the disease can be diagnosed timely. However, the most common fundus lesion is the retinal involvement which usually affects the macula or the perimacular region. A ground-glass whitening of the retina with ill-defined margins, and a mottling of the underlying retinal pigment epithelium has been described as the typical lesion. There is no marked vitreous reaction or involvement of the retinal vessels, or satellite lesions that might differentiate this from other inflammatory lesions.<sup>10</sup> The abnormalities in the macula in their minimal form may just consist of granular pigmentary changes or red-orange colour changes which are often bilaterally symmetrical.<sup>9</sup> Multifocal lesions have also been reported.<sup>10</sup> Such localized ophthalmoscopic findings may often suggest a primary ocular problem and remain a diagnostic dilemma, particularly when ophthalmic features precede the typical neurological signs, as in our case.

At present efficient measles vaccination appears to be the sole remedy to prevent this devastating neurological disorder. Widespread immunisation has produced greater than 90% reduction in the incidence of SSPE in developed nations.<sup>1</sup> Developing countries continue to have a higher prevalence of SSPE due to inadequate vaccine coverage. The present case stresses that the failure of immunization may lead to such devastating consequence. Further ophthalmologists need to be aware that necrotizing retinitis in a child could be the heralding feature of this condition in such countries. Although SSPE is a customarily fatal disease, recognition of this unusual presentation is valuable to allow earlier diagnosis and institution of palliative measures.

### 4. Source of Funding

None.


## 5. Conflict of Interest

None.


## References


- Garg RK. Subacute sclerosing panencephalitis. *J Neurol*. 2008;255:1861–71.
- Bellini WJ, Rota JS, Lowe LE, Katz RS, Dyken PR, Zaki SR, et al. Subacute sclerosing panencephalitis: more cases of this fatal disease are prevented by measles immunization than was previously recognized. *J Infect Dis*. 2005;192(10):1686–93.
- Miller C, Farrington CP, Harbert K. The epidemiology of subacute sclerosing panencephalitis in England and Wales 1970-1989. *Int J Epidemiol*. 1992;21(5):998–1006.
- Saha V, John TJ, Mukundan P, Gnanamuthu C, Prabhakar S, Arjundas G, et al. High incidence of subacute sclerosing panencephalitis in south India. *Epidemiol Infect*. 1990;104(1):151–6.
- Manayani DJ, Abraham M, Gnanamuthu C, Solomon T, Alexander M, Sridharan G. SSPE - The continuing challenge: A study based on serological evidence from a tertiary care centre in India. *Indian J Med Microbiol*. 2002;20(1):16–8.
- Praveen-Kumar S, Sinha S, Taly AB, Jayasree S, Ravi V, Vijayan J, et al. Electroencephalographic and imaging profile in a subacute sclerosing panencephalitis (SSPE) cohort: a correlative study. *Clin Neurophysiol*. 2007;118(9):1947–54.
- Yuksel D, Sonmez PA, Yilmaz D, Senbil N, Gurer Y. Ocular findings in subacute sclerosing panencephalitis. *Ocul Immunol Inflamm*. 2011;19(2):135–8.
- Kravljanac R, Jovic N, Djuric M, Nikolic L. Epilepsia partialis continua in children with fulminant subacute sclerosing panencephalitis. *Neurol Sci*. 2010;32(6):1007–12.
- Green SH, Wirtzchaffer JD. Ophthalmoscopic findings in subacute sclerosing panencephalitis. *Br J Ophthalmol*. 1973;57:780–87.
- Robb RM, Valter V. Ophthalmic manifestations of subacute sclerosing panencephalitis. *Arch Ophthalmol*. 1970;83(4):426–35.


## Author biography

**Anu Jain**, Assistant Professor  <https://orcid.org/0000-0003-1833-7528>

**Apoorva Jain**, Associate Professor

**Snigdha Sen**, Professor  <https://orcid.org/0000-0003-1437-5869>

**Mahipal Singh Yadav**, Junior Resident  <https://orcid.org/0009-0008-2491-5201>

**Rajendra Prakash Maurya**, Associate Professor & I/c Orbit  <https://orcid.org/0000-0001-9343-6003>

**Cite this article:** Jain A, Jain A, Sen S, Yadav MS, Maurya RP. Bilateral retinitis as the initial presentation of subacute sclerosing panencephalitis. *Indian J Clin Exp Ophthalmol* 2023;9(2):274-277.