

## Study of clinical significance of optical coherence tomography in diagnosis & management of diabetic macular edema

Neha Kantilal Desai<sup>1,\*</sup>, Somesh Vedprakash Aggarwal<sup>2</sup>, Sonali Satish Shah<sup>3</sup>,  
Puja Shubham Negi<sup>4</sup>

<sup>1</sup>Assistant Professor, <sup>2</sup>Professor, <sup>3</sup>Associate Professor, <sup>4</sup>Tutor  
Dept. of Ophthalmology, B.J Medical College, Ahmedabad, Gujarat

\*Corresponding Author

E-mail: dr.neha\_desai@yahoo.com

### Abstract

**Background:** 26 million people were estimated to be affected by diabetes in 2010 across the globe. Diabetic macular edema (DME) is the most important cause of visual impairment due to diabetic retinopathy. Optical Coherence Tomography (OCT) is a non-invasive modality which produces cross-sectional or three-dimensional, high-resolution images of the retinal layers and quantitative assessment of retinal thickness

Aim of study was to study the incidence of different patterns of diabetic macular edema on Optical coherence tomography (OCT), to decide treatment & follow-up protocol.


**Material & Methods:** 200 eyes of 167 patients attending the M & J Institute of Ophthalmology and having diabetic macular edema were enrolled in this study. Base line examination like best corrected visual acuity, anterior segment examination, indirect ophthalmoscopy, slit lamp biomicroscopy, OCT and fundus fluorescein angiography were done in all patients. The patients will be classified according to type of macular edema on OCT. Follow up visits will be scheduled one week, one month post procedure and every two monthly thereafter.

**Results:** In this non-randomized, prospective study, 200 eyes of 167 patients with diabetic macular edema were enrolled. Out of 167 patients 33 (19.7%) patients were having DME in both eyes. Single type of edema was present in 122 (61%) eyes, combination of two types of edema in 56 (28%) eyes & combination of three types of edema in 22 (11%) eyes. Grid laser treatment was given in 72 (36%) eyes. Intravitreal triamcinolone injection was given in 110 (55%) eyes. Parsplana vitrectomy was done in 18 (9%) eyes.

**Discussion:** Diabetic macular edema is the most important cause of visual impairment in patients with diabetes. OCT is a non-invasive and reproducible tool for obtaining high resolution, cross-sectional images of the retina. In our study spongy edema was most common type found (36%), followed by cystoid edema (14%), serous detachment (7%) & vitreomacular traction in 2%. OCT provides a better anatomical description of CSME for deciding treatment protocols.

**Conclusion:** Identifying the structural changes in eyes with DME using OCT may allow more effective management of these patients.

**Keywords:** Diabetes mellitus, Macular edema, Optical coherence tomography

Access this article online	
<b>Quick Response Code:</b> 	<b>Website:</b> www.innovativepublication.com
	<b>DOI:</b> 10.5958/2395-1451.2016.00003.2

### Introduction

In 2010, there were 26 million people who had diabetes & prevalence of diabetes is projected to increase significantly across the globe(1). Diabetic macular edema is the most common etiology of visual loss due to diabetic retinopathy. Diabetic macular edema may occur in either type 1 or type 2 diabetes but it is more common in type 2. The development of diabetic macular edema is associated with longer duration of disease, poor glycemic control & conversion to insulin therapy for type 2 diabetics(2). coherence tomography (OCT) has revolutionized the documentation & quantification of diabetic macular

edema. Optical coherence tomography (OCT) is a non-invasive modality which produces cross-sectional or three-dimensional, high-resolution images of the retinal layers and quantitative assessment of retinal thickness and other features of macular edema(3). OCT is based on a technique called low-coherence interferometry, which uses multiple axial scans to produce a retinal image(4). Due to the fast scanning process, it allows a raster scanning providing data from all locations of the retina. OCT is very precise & delineates each layer of the retina with an axial resolution of less than 10micron(5). Advantages of OCT include non-contact, non-invasive, fine detail with which retina is image & can be repeated at various visits with extreme accuracy. In our study we have included 200 eyes of 167 patients with diabetic macular edema & we have studied different patterns of diabetic macular edema on OCT & its usefulness in management.

### Aims of Study

1. To study the incidence of different patterns of diabetic macular edema on optical coherence tomography (OCT)
2. To decide the treatment protocol on basis of type of diabetic macular edema on OCT
3. To assess the effect of different treatment modalities on follow-up

### Material & Methods

200 eyes of 167 patients attending the OPD at M & J Institute Of Ophthalmology and having Diabetic macular edema were enrolled in this study. For our study inclusion & exclusion criteria were as follow:

#### Inclusion criteria were:

1. Patient of Diabetes Mellitus Type 2
2. Age >40 years
3. Diabetic macular Edema with any level of Diabetic retinopathy.

#### Following patients were excluded from this study–

1. Presence of any other posterior segment pathology affecting visual acuity.
2. Presence of any anterior segment pathology.
3. Patients with advanced cataractous changes, complicated pseudophakia and corneal opacities making fundus examination difficult.
4. Patients with previous history of any form of treatment taken for diabetic retinopathy.
5. Patients who found to have macular ischemia after doing FFA.
6. Pregnant, immunocompromised, known HIV and HbsAg positive patients were excluded.

Written informed consent was taken before recruiting the patients for the study. Base line examination like best corrected visual acuity, anterior segment examination, indirect ophthalmoscopy, slit lamp bio microscopy, OCT and Fundus fluorescein angiography were done in all patients. Before doing FFA, routine blood investigations like FBS, PPBS, blood urea, serum creatinine & urine sugar were done

The patients will be classified according to type of macular edema on Oct.

- 1 Spongy Edema (fig. 1)
- 2 Cystoid Edema (fig. 2)
- 3 Serous retinal detachment (fig. 3)
- 4 Taut posterior hyaloid membrane (fig. 4)
- 5 Foveal tractional retinal detachment (fig. 5)

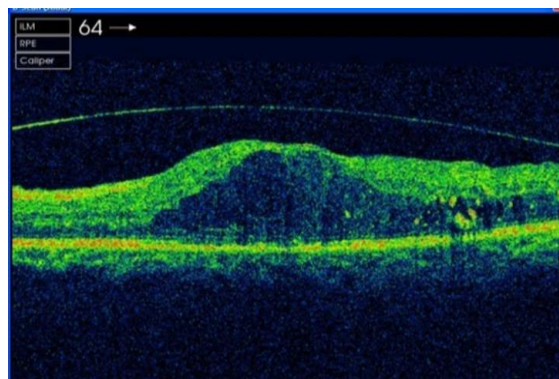


Fig. 1: Spongy Edema

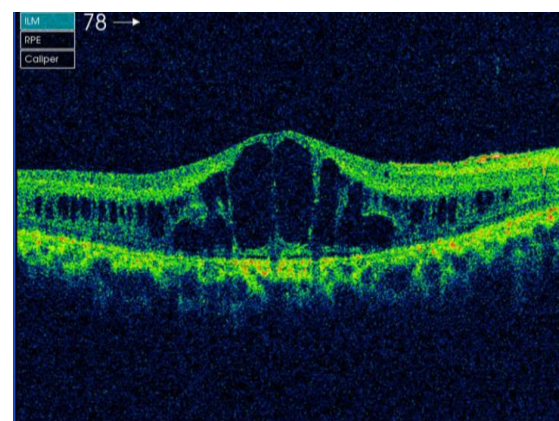


Fig. 2: Cystoid Edema

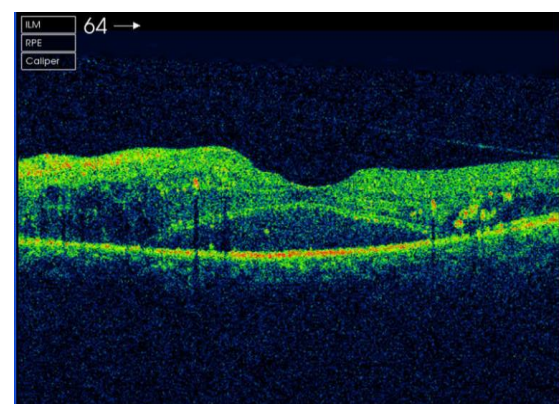


Fig. 3: Serous retinal detachment

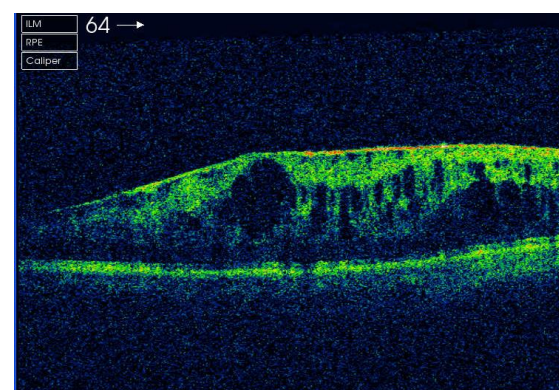
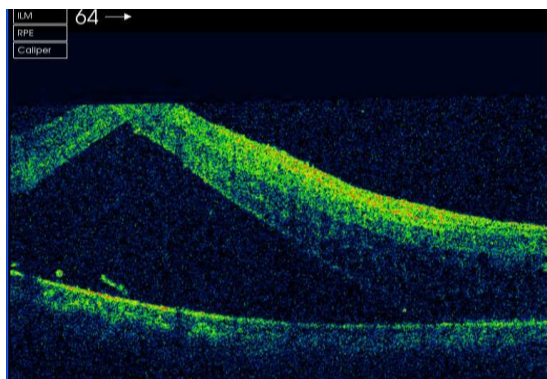


Fig. 4: Taut posterior hyaloid membrane



**Fig. 5: Foveal tractional retinal detachment**

Patients with diffuse macular edema were subjected to grid laser photocoagulation. Patients with serous retinal detachment and cystoid macular edema will be given intravitreal triamcinolone injection. Patients with taut posterior hyaloid and vitreomacular traction syndrome will be subjected to parsplana vitrectomy.

Follow up visits will be scheduled one week, one month post procedure and every two monthly thereafter. Best Corrected Visual acuity, IOP measurement, cataract assessment, indirect ophthalmoscopy, slit lamp bio microscopy, optical coherence tomography will be done at each visit. Retreatment assessment will be done every 3 months and patient will be treated as required.

**Results**

In this non-randomized, prospective study, 200 eyes of 167 patients with diabetic macular edema were included. Out of 167 patients 33 (19.7%) patients were having DME in both eyes.

**Table 1: Range of visual acuity**

Visual Acuity	No. of Eyes	Percentage
6/6 to 6/18	36	18%
6/24 to 6/60	96	48%
<6/60	68	34%

**Table 2: Types of single edema on OCT**

Type of edema	No. of Eyes
Spongy	72
Cystoid	28
Serous Detachment	14
Taut posterior hyaloid	4
Tractional RD	4
Total	122

Single type of edema was present in 122 (61%) eyes, combination of two types of edema in 56 (28%) eyes & combination of three types of edema in 22 (11%) eyes.

**Table 3: Combination of two types of edema on OCT**

Type of Edema	No. of Eyes
Cystoid + Spongy	36
Spongy + Serous	6
Cystoid + Serous	6
Spongy + TPH	4
Spongy + VMT	2
Cystoid + VMT	2
Total	56

**Table 4: Combination of three types of edema on OCT**

Type of edema	No. of Eyes
Cystoid + Spongy + Serous	20
Cystoid + Serous + tphm	2
Total	22

**Table 5: Central foveal thickness on OCT**

Central Foveal Thickness	No. of Eyes	Percentage
250-350 Microns	114	57%
350-450 Microns	50	25%
450-600 Microns	22	11%
>600 Microns	14	7%

Grid laser treatment was given in 72 (36%) eyes. Intravitreal triamcinolone was given in 110 (55%) eyes. Parsplana vitrectomy was done in 18 (9%) eyes.

**Table 6: Improvement in visual acuity at the end of 1 year**

Visual Acuity	No. of Eyes	Percentage
6/6 to 6/18	96	48%
6/24 to 6/60	76	38%
<6/60	28	14%

**Table 7: Reduction in central foveal thickness at the end of 1 year**

Central Foveal Thickness	No. of Eyes	Percentage
250-350 Microns	152	76%
350-450 Microns	36	18%
450-600 Microns	10	5%
>600 Microns	2	1%

The findings on fundus fluorescence angiography parallel those of visual acuity 16% of eyes treated with intravitreal triamcinolone injections had intraocular pressure >21 mm Hg and were treated topical anti-glaucoma medication. 8% of eyes had rapid progression of cataract after intravitreal triamcinolone injections. There were no other complications like vitritis, vitreous hemorrhage, retinal detachment and endophthalmitis in

patients treated with intravitreal triamcinolone injections.

### Discussion

Diabetic retinopathy is the sixth leading cause of blindness in the world. Diabetic macular edema remains the most frequent cause of vision loss among the diabetic population and is particularly prevalent among Insulin dependent type 2 diabetics.

Macular edema is clinically detected by slit-lamp biomicroscopy. The ETDRS (Early Treatment Diabetic Retinopathy Study) classified macular edema by its severity. It was defined as Clinically Significant Macular Edema (CSME) if any of the following features were present: 1) thickening of the retina at or within 500 micron of the center of macula 2) Hard exudates at or within 500 micron of the center of macula if associated with thickening of the adjacent retina. 3) A zone of retinal thickening one disc area or larger any part of which is within one disc diameter of the center of the macula(6).

The physiologic aspect of DME can be assessed by fluorescein angiography, that is a kind of functional evaluation, the anatomical features of DME such as extent of thickening, the retinal layers involved and associated aspects can be described with OCT offering a structural and quantitative analysis of DME. OCT is a non-invasive, rapid and repeatable tool for obtaining high resolution cross-sectional images of the retina.

In our study we have found five patterns of diabetic macular edema. In our study spongy edema was most common type found (36%), followed by cystoid edema (14%), serous detachment (7%) & vitreomacular traction in 2%. In the Alkuraya H et al study (1995), the spongy edema was the most common (45.4%), followed by the Cystoid edema (29.0%), serous retinal detachment (21.8%) and vitreofoveal traction (3.6%) patterns(7). In a study done by Otani T et al (1999), Spongy edema was the most common pattern (found in 88% of the patient)(8).

Yang et al have suggested that the OCT is more sensitive than a clinical examination in assessing diabetic macular edema and is a better for documenting changes in macular thickening. Spongy macular edema was seen in 58% of eyes without CSME in that series(9). Schaudig et al also had similar observations who & also showed a significant increase in macular thickening in diabetic patients without diabetic retinopathy compared to non-diabetic patients(10).

Ozdek et al had found spongy retinal thickening in 66%, Cystoid macular edema in 16% and serous retinal detachment in 10% of eyes with diabetic macular edema(11). Kim et al have reported spongy retinal thickening in 97%, Cystoid macular edema in 55%, Serous retinal detachment in 7%, VMT in 13% of eyes with diabetic macular edema(12).

As macular ischemia can be a cause of visual loss in patients with diabetic macular edema, the present

study excluded this group of patients during the analysis. 18% eyes have visual acuity better than 6/18, 48% have 6/24 to 6/60 & 34% had visual acuity less than 6/60. Alkuraya et al had reported that there was a positive correlation between the type of macular edema on OCT and best corrected visual acuity. Patients with CME and VMT had worse vision. Most of the other series had reported that the best corrected visual acuity correlated linearly with central foveal thickness. It is also found that the central foveal thickness increases with the different types of OCT presentations, being least for spongy thickening, moderate for CME/SRF and highest for VMT and thus visual loss correlate with these changes.

With the advent of newer treatment modalities such as intravitreal anti-vascular endothelial growth factor injection (anti-VEGF) intravitreal triamcinolone injection, posterior subtenon injection of triamcinolone and vitrectomy for diabetic macular edema, the laser therapy for diabetic macular edema is better reserved for selected groups of patients. OCT provides a better anatomical description of diabetic macular edema for identification of the medically and surgically treatable groups.

### Conclusion

Optical coherence tomography (OCT) is a newer & noninvasive tool to measure retinal thickness and other aspects associated with diabetic macular edema. Identifying the structural changes in eyes with DME using OCT may allow more effective management of these patients.

In our study we have found five patterns of diabetic macular edema. In our study spongy edema was most common type found (36%), followed by cystoid edema (14%), serous detachment (7%) & vitreomacular traction in 2%. In our study, Patients with only spongy macular thickening on OCT responded better to conventional laser treatment. Patients with cystoid macular edema/serous retinal detachment responded best to IVTA/PST with or without focal laser and patients with ERM/VMT responded best with vitrectomy.

**Conflicts of Interest: None**

**Source of Support: Nil**

### References

- Centers for Disease Control and Prevention. Diabetes in the United States. www.cdc.gov/diabetes/news/docs/diabetesmon th.htm. Accessed January 12, 2015.
- American Academy of ophthalmology Retina Panel: Preferred practice pattern guidelines. Diabetic retinopathy. San Francisco, American academy of ophthalmology, 2008.
- Hee MR et al, 1998; Otani T et al, 1999; Yamamoto S et al, 2001; Buabbud JC et al, 2010.
- Huang D, Swanson EA, Lin CP, et al. Optical coherence tomography. Science. 1991;254:1178-1181.

5. Gabriele ML, Wollstein G, Ishikawa H, et al. Optical coherence tomography: history, current status & laboratory work. *Invest Ophthalmol Vis Sci.*2011;14:2425-2436.
6. Early photocoagulation for diabetic retinopathy. ETDRS report number 9. Early treatment diabetic retinopathy study research group. *Ophthalmology.*1991;98(5 suppl):766-785.
7. Alkuraya H, Kangave D, Abu El-Asra AM. The correlation between optical coherence tomographic features and severity of retinopathy, macular thickness and visual acuity in diabetic macular edema. *Int Ophthalmol* 2005;26(3):93-99.
8. Otani T, Kishi S, Maruyama Y. Patterns of diabetic macular edema with optical coherence tomography. *Am J Ophthalmol* 1999;127:688-693.
9. Quantitative Assessment of Retinal Thickness in Diabetics with or without CSME using OCT, Yang CS, Cheng CY; *Acta Ophthalmol Scand* 2001;79(3):266-70.
10. Optical coherence tomography for retinal thickness measurement in diabetic patients without clinically significant macular edema; Schaudig et al; *Ophthal Surg Laser* 2000;31(3):182-6.
11. Optical Coherence Tomographic Assessment of Diabetic Macular Edema-Comparison with Fluorescein Angiographic and Clinical Findings; Sengui C Ozdek, Alper Erdinc, Gokhan Gurelik; *Ophthalmologica* 2005,219(2):86-92.
12. Optical Coherence tomographic patterns of diabetic macular edema; Kim BY et al, *Am J Ophthal*, 2006;142(3):405-12.