

Visual outcome of hydrophilic and hydrophobic foldable posterior chamber intraocular lenses in cataract surgery

Pavan V. Joshi^{1,*}, Ankita Gupta²

^{1,2}Resident, Dept. of Ophthalmology, VMMC and Safdarjung Hospital, New Delhi

*Corresponding Author

E-mail: ramspsm@yahoo.co.in

Abstract


Introduction: As there is no pharmacological treatment for cataract, the standard treatment is surgical removal of the opacified lens and implantation of an artificial intraocular lens (IOL). The standard method of cataract extraction today is phacoemulsification. In this method, the crystalline lens is emulsified and aspirated away through a hollow needle that vibrates at high (ultrasonic) frequency, which is inserted through a centrally placed opening in the anterior capsular sac.

Methodology: Patient will then undergo phacoemulsification with implantation of a foldable posterior chamber intraocular lens, which will be done by a single surgeon, using the same technique. Patients will be randomly assigned to either of the two groups, ie hydrophilic acrylic foldable IOL and hydrophobic acrylic foldable IOL, until the target sample size has been achieved. The type of lens (hydrophilic/hydrophobic) will be noted for further studies.

Results: The first day postoperative vision is comparable between the two groups, with Hydrophilic lenses having visual outcome of 6/12 in 15 cases out of 40, and visual outcome of 6/9 in 12 cases out of 40, and Hydrophobic lenses having visual outcome of 6/12 in 17 cases out of 40, and visual outcome of 6/9 in 14 cases out of 40. (p value = 0.328)

Conclusion: Both IOL are equally beneficial in the visual rehabilitation of the patient.

Keywords: Cataract surgery, Intraocular lenses, Visual outcome.

Access this article online	
Quick Response Code:	Website: www.innovativepublication.com
	DOI: 10.5958/2395-1451.2016.00012.3

Introduction

The eye forms the optical system of the human visual system. A variety of references provide a good general introduction to the essential components of the eye and their function.^{1,2} The eye consists of two separated lenses that ideally form an image on the retina, the array of photosensitive cells lining the back surface of the eyeball. The eye's first lens is the cornea, which is the clear membrane on the external portion of the eye. The cornea is a meniscus lens and has a power of about 43 diopters (D). The iris resides several millimeters behind the cornea. The iris is heavily pigmented to block light transmission and serves as the aperture stop of the eye. The diameter of the opening in the iris varies with light level, object proximity, and age. The crystalline lens is the second optical element of the eye. It lies immediately behind the iris and provides the focusing mechanism of the visual system. Together, the cornea and iris form images on the external environment onto the retina. At the retina, the light is converted to a neural signal and transmitted to the brain where the signals are interpreted into our perceived image of the surrounding scene.

Opacification of the natural lens of the eye (cataract) is the most common cause of blindness around the world. A cataract is a cloudiness or opacity in the normally transparent crystalline lens of the eye.

Lens transparency depends on the regular arrangement of the lens fibres and of the cytoplasm within the fibre. Disorganisation of the lens fibre, or disorganisation of the cytoplasm within the fibre, causes scattering and accounts for the development of cataract. In any particular morphological type of cataract, one or other mechanism may predominate.

As there is no pharmacological treatment for cataract, the standard treatment is surgical removal of the opacified lens and implantation of an artificial intraocular lens (IOL). The standard method of cataract extraction today is phacoemulsification^{3,4}. In this method, the crystalline lens is emulsified and aspirated away through a hollow needle that vibrates at high (ultrasonic) frequency, which is inserted through a centrally placed opening in the anterior capsular sac (capsulorrhexis).

There are mainly two types of Acrylic IOLs. Hydrophilic acrylic (hydrogel) is a soft hydrophilic material. The material used is polyhydroxyethylmethacrylate (PolyHema) with a water content varying from 18% to 30% and a refractive index of 1.47. Hydrophobic acrylics are polymers synthesised from esters of acrylic or methacrylic acid. It contains tiny amounts of water (less than 1%). Hydrophobic acrylic IOLs have a refractive index of 1.55. Both these materials are not without their lists of complications

Methodology

The study will be a randomized, parallel group study, conducted at a single centre on 80 eyes (40 eyes in each category) selected from patients attending the outpatient department, Department of Ophthalmology, Safdarjung Hospital, New Delhi.

Participants will be included in the study based on the following criteria-

1. Age more than 50 years
2. Presence of senile cataract in one or both eyes
3. Patient willing/wanting to undergo Phacoemulsification with implantation of an acrylic foldable hydrophilic/hydrophobic posterior chamber intraocular lens
4. Patient giving full and free consent for involvement in the study
5. Patient willing for follow up

Exclusion criteria:

1. Any central corneal pathology that could have impact on vision
2. Any documented glaucoma of any kind
3. Any macular pathology
4. Any diabetic retinopathy other than minimal background diabetic retinopathy felt unlikely to affect vision
5. Any other causes of central visual acuity loss
6. Any surgical complication felt to in any way impact upon the quality of visual outcome

Procedure and Data Collection

A preliminary screening patient assessment and examination will be conducted on patients consulting the outpatient department in the department of ophthalmology, Safdarjung Hospital. Patients fulfilling the above mentioned criteria will be enrolled in the study, after explaining pertinent details of the study and obtaining valid consent for the same. Recruitment will be on going for an approximate period of one year in order to collect the proposed target sample size.

Once patients are thus selected, baseline assessment will include a standard ophthalmic examination, including-

1. a review of medical history,
2. uncorrected visual acuity with Snellen's chart
3. best corrected visual acuity,
4. colour vision using Ishihara charts
5. contrast sensitivity using Pelli-Robson chart
6. basic ophthalmological examination with torch light
7. slit lamp examination of the anterior segment with undilated pupils,
8. random IOP measurement using NCT
9. syringing
10. dilated slit lamp examination,
11. dilated fundoscopic examination using direct ophthalmoscopy

The patient will then be subjected to a questionnaire to assess their visual disability and discomfort. The questionnaire will be interviewer-administered and will be conducted in the outpatient department, Department of Ophthalmology, Safdarjung Hospital. The questions will be translated into the patient's own language and the responses will be noted down.

Patient will then undergo phacoemulsification with implantation of a foldable posterior chamber intraocular lens, which will be done by a single surgeon, using the same technique. Patients will be randomly assigned to either of the two groups, ie hydrophilic acrylic foldable IOL and hydrophobic acrylic foldable IOL, until the target sample size has been achieved. The type of lens (hydrophilic/hydrophobic) will be noted for further studies.

On the first postoperative day, the following parameters will be assessed by the investigator-

1. Visual Acuity
2. Basic ophthalmological examination with torchlight
3. Colour Vision using Ishihara charts
4. Contrast Sensitivity using Pelli-Robson chart
5. Slit lamp examination (for visualization and grading of post-operative inflammation and glistening)

The patient will be asked to come for follow up after 1 week, 2 weeks, 4 weeks, and 6 weeks. On each of his/her visit, the following parameters will be noted-

1. Visual Acuity
2. Colour Vision using Ishihara charts
3. Contrast Sensitivity using Pelli-Robson chart
4. Intraocular Pressure
5. Any posterior capsular opacification (seen through slit lamp, and if present, grading will be done)
6. Presence of any glistening (seen through slit lamp, and if present, will be graded)
7. Any intraocular inflammation (seen through slit lamp, and graded accordingly)

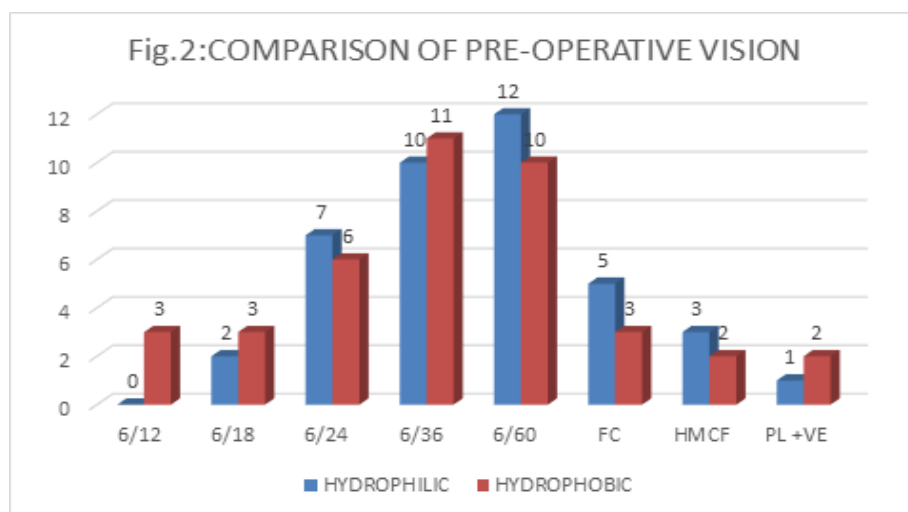
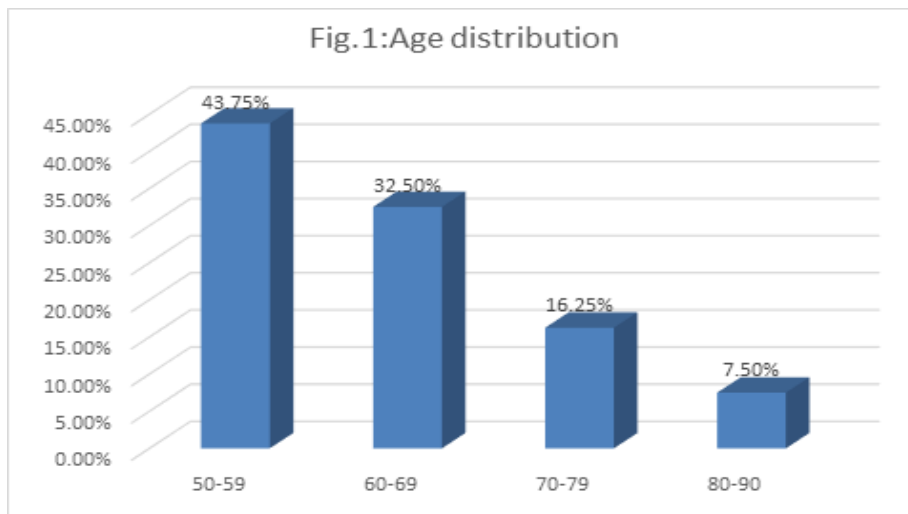
At 6 weeks, the patient's subjective feeling of satisfaction will be assessed by questionnaire.

Results

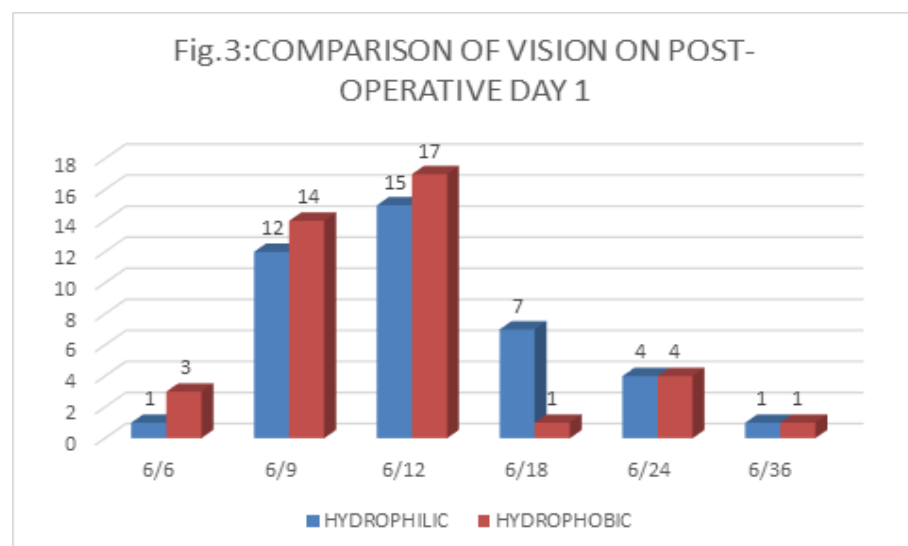
A total of 80 patients with cataract, attending the Ophthalmology OPD were enrolled in the study. They were divided into 2 groups, Group 1 being the patients with Hydrophilic Acrylic IOLs, and Group 2 being the patients with Hydrophobic Acrylic IOLs.

In Group 1, out of 40 patients, 26 were male and 14 were female.

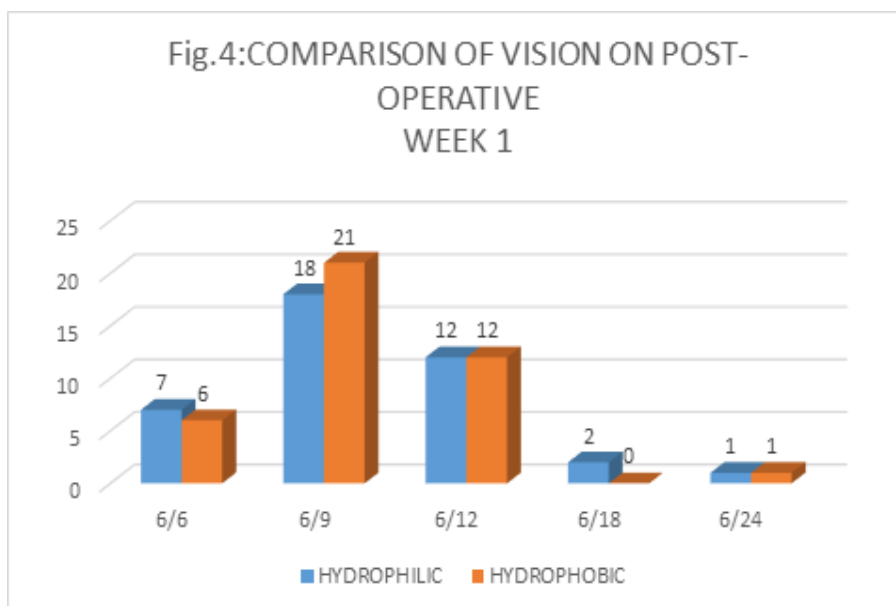
In Group 2, out of 40 patients, 23 were male and 17 were female.



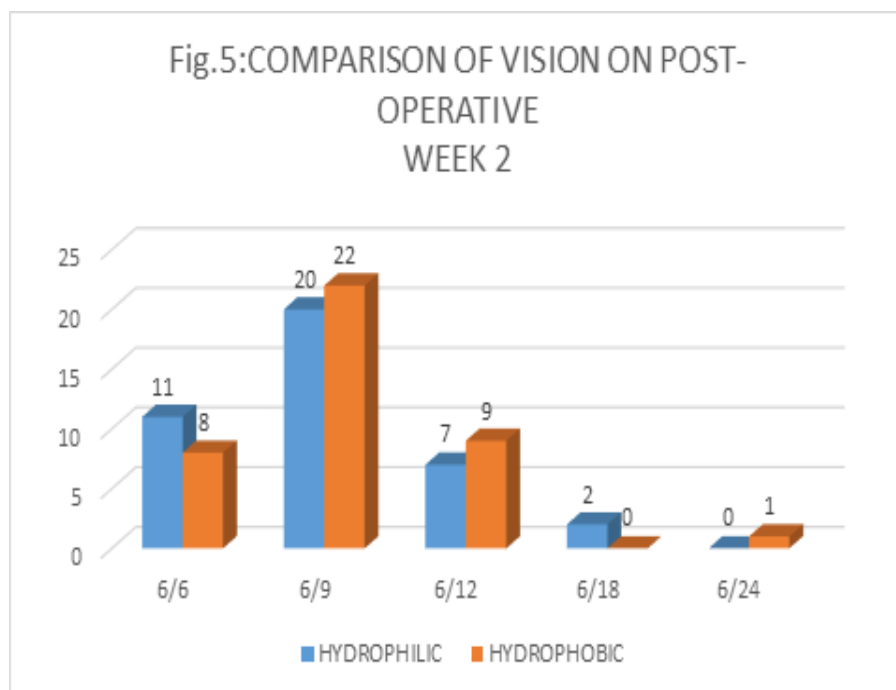
The pre-operative vision is comparable between the two groups, with the maximum cases falling in the group of 6/60 (22 cases out of 80, i.e. 27.5%), and 6/36 (21 out of 80 cases, i.e. 26.25%)



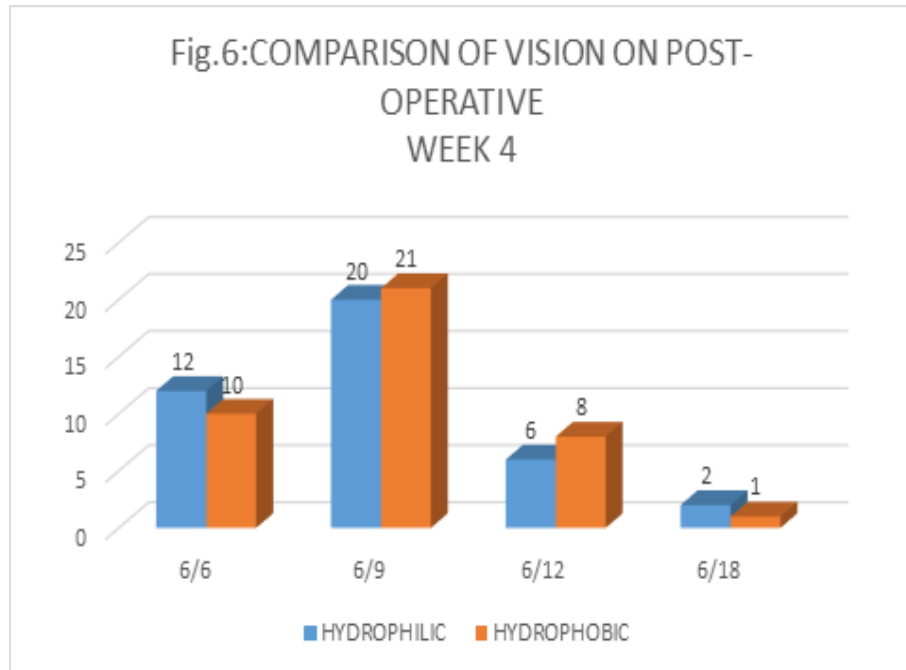
The first day post-operative vision is comparable between the two groups, with Hydrophilic lenses having visual outcome of 6/12 in 15 cases out of 40, and visual outcome of 6/9 in 12 cases out of 40, and Hydrophobic lenses having visual outcome of 6/12 in 17 cases out of 40, and visual outcome of 6/9 in 14 cases out of 40. (p value = 0.328)



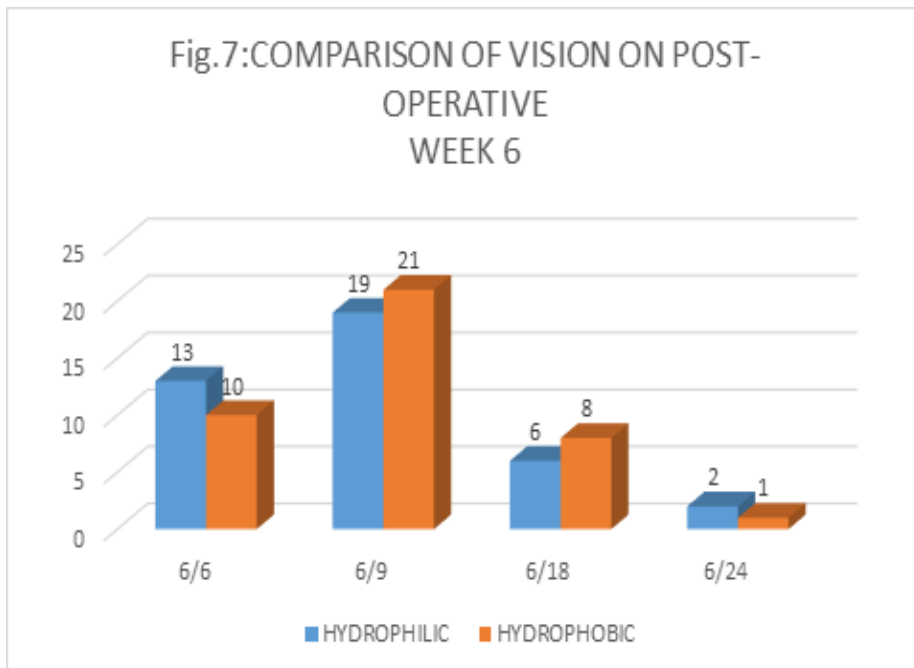
The first week post-operative vision is comparable between the two groups, with Hydrophilic lenses having visual outcome of 6/9 in 18 cases out of 40, and visual outcome of 6/12 in 12 cases out of 40, and Hydrophobic lenses having visual outcome of 6/9 in 21 cases out of 40, and visual outcome of 6/12 in 12 cases out of 40 (p value=0.679)



The week two post-operative vision is comparable between the two groups, with Hydrophilic lenses having visual outcome of 6/6 in 11 cases out of 40, visual outcome of 6/9 in 20 cases out of 40, and visual outcome of 6/12 in 7 cases out of 40, and similarly Hydrophobic lenses having visual outcome of 6/6 in 8 cases out of 40, visual outcome of 6/9 in 22 cases out of 40, and visual outcome of 6/12 in 9 cases out of 40 (p value= 0.431)



The week 4 post-operative vision is comparable between the two groups, with Hydrophilic lenses having visual outcome of 6/6 in 12 cases out of 40, visual outcome of 6/9 in 20 cases out of 40, and visual outcome of 6/12 in 6 cases out of 40, and similarly Hydrophobic lenses having visual outcome of 6/6 in 10 cases out of 40, visual outcome of 6/9 in 21 cases out of 40, and visual outcome of 6/12 in 8 cases out of 40 (p value=0.843)



The week 6 post-operative vision is comparable between the two groups, with Hydrophilic lenses having visual outcome of 6/6 in 13 cases out of 40, visual outcome of 6/9 in 19 cases out of 40, and visual outcome of 6/12 in 6 cases out of 40, and similarly Hydrophobic lenses having visual outcome of 6/6 in 10 cases out of 40, visual outcome of 6/9 in 21 cases out of 40, and visual outcome of 6/12 in 8 cases out of 40(p value= 0.775).

Discussion

The first intraocular lens was made of PMMA, inspired by the inertia this material had when found in pilot's eyes containing fragments of shattered cockpit canopies, and it was implanted by Sir Harold Ridley in November 1949(51). In 1962, Charles Kelman introduced the phacoemulsification technique. In this technique, the crystalline lens is shattered with ultrasound waves and removed through a small incision of approximately 3.0mm, decreasing the amount of surgically induced astigmatism^{5,6}, and surgical trauma. This surgical development initiated the development of foldable IOLs, since the use of IOLs made of PMMA required a much larger incision of typically 6.0mm. Foldable IOLs are made up of either silicon or acrylic. The design of intraocular lenses (IOLs) has evolved rapidly in recent years. Because of the significant advances that have been made, there are now numerous varieties of IOL on the market and in development; naturally, questions over which is the best model endure. In particular, there is discussion of whether hydrophilic or hydrophobic IOLs are the superior lenses.

We conducted a study on 80 patients with cataract attending the Ophthalmology OPD.

They were divided into 2 groups of 40 eyes each, Group 1 being the patients with Hydrophilic Acrylic IOLs, and Group 2 being the patients with Hydrophobic Acrylic IOLs.

The parameters compared were preoperative visual acuity, and post-operative visual acuity at 1st post-operative day, 1 week, 2 weeks, 4 weeks and 6 weeks following cataract surgery.

Other parameters which were similarly compared at the previously mentioned time intervals were PCO, AC cells, AC flare, and Glistenings.

A prepared questionnaire was asked to each of the patients at 6 weeks post cataract surgery, and their response recorded. The overall satisfaction after the surgery was recorded. The visual acuity was comparable between the two groups at each of the prementioned time intervals, i.e. on the first post-operative day, and at 1 week, 2 weeks, 4 weeks and 6 weeks post cataract surgery. This is comparable to the study conducted by Riaz Ahmed, Imran Ghayoor, M Mubassher Malik, Ghazala Tabssum, Furrakh Ahmed who noted that there was no significant difference between the two IOLs regarding Visual Acuity after one year follow up⁷.

Conclusion

After our study, we have concluded that the Hydrophilic Acrylic IOL and the Hydrophobic Acrylic IOL have no differences when compared as regarding the Visual Acuity and also the Uveal Biocompatibility. They are equally beneficial in the visual rehabilitation of the patient

Conflict of Interest: None

Source of Support: Nil

References

1. W. J. Smith, Modern Optical Engineering, 4th ed., McGraw-Hill, New York, 2000.
2. D. A. Atchison and G. Smith, Optics of the Human Eye, Butterworth-Heinemann, Oxford, 2000.
3. Alio y Sanz JL: Micro incision cataract surgery time has arrived. Arch Soc Esp Ophthalmol 2003;78(2):65-6.
4. Riaz Y, Mehta J, Wormald R, Evans JR, Foster A, Ravilla T, Snellingen T. Surgical interventions for age related cataract. Cochrane Database of Systematic Reviews 2006 Oct 18;(4):CD001323.
5. Brint SF, Ostrick DM, Bryan JE. Keratometric cylinder and visual performance following phacoemulsification and implantation with silicone small-incision or polymethyl methacrylate intraocular lenses. J Cataract Refract Surg 1991;17:32-36.
6. Steinert RF, Brint SF, White SM, Fine IH. Astigmatism after small incision cataract surgery. A prospective, randomized multicenter comparison of 4- and 6.5-mm incisions. Ophthalmology 1991;98:417-23.
7. Riaz Ahmed, Imran Ghayoor, M Mubassher Malik, Ghazala Tabssum, Furrakh Ahmed: Comparison between Acrylic Hydrophilic and Acrylic Hydrophobic Intraocular Lens after Phacoemulsification. Pak J Ophthalmol 2011;27(4):195-9.