

Congenital ocular deformities- leading cause of childhood blindness- A clinical profile study

Punita Garg^{1,*}, Shazia Qayum², Puneet Dhingra³, H.K Sidhu⁴

¹Associate Professor, ²Senior Resident, Dept. of Ophthalmology, MMIMSR, Mullana, Ambala

³Senior Resident, Dept. of Ophthalmology, BPS Govt. Medical College for Women Khanpur, Sonapat

⁴Professor & Head, Dept. of Ophthalmology, Adesh Institute of Medical Sciences and Research, Bathinda

***Corresponding Author**

E-mail: drpgargmmu@gmail.com

Abstract


Background: Congenital eye disorders, though rare, are important causes of childhood blindness. It can occur in isolation or in combination, or as part of a syndrome. This retrospective study was aimed at documenting the causes of congenital eye diseases in a rural medical college of north India.

Method: A review of the case notes of patients presenting at the eye clinic with congenital eye diseases between January 2011 and December 2014 was carried out.

Result: The common congenital disorders were cataract 38 (19%), congenital glaucoma 6 (3%), and corneal opacity 10 (5%) congenital strabismus 7 (3.5%), which are causes of preventable blindness. Other disorders were congenital disorders with autosomal recessive inheritance like, diseases of retina Retinitis Pigmentosa 34 (17%) and developmental anomalies like anophthalmos, microphthalmos, coloboma, aniridia, ectopia lentis seen in 46 (23%) which are congenital causes of irreversible childhood blindness.

Conclusion: Congenital anomalies are found to be the common cause of blindness in childhood. The majority of the cases were due to avoidable causes of blindness. It is necessary to identify important avoidable causes of severe visual impairment and blindness in order to develop control programs to prevent childhood blindness in the country.

Keywords: Congenital Ocular Anomalies, Childhood Blindness

Access this article online	
Quick Response Code: 	Website: www.innovativepublication.com
	DOI: 10.5958/2395-1451.2016.00005.6

Introduction

Congenital eye disorders, in isolation or in combination, or as part of a syndrome though rare are important causes of childhood blindness. In the human embryo, the eyes are formed by a delicate and complex process. Problems in this process can lead to congenital eye malformations. These conditions are relatively rare, occurring in approximately five per 10,000 live births⁽¹⁾. Genetic factors play a role in many kinds of eye disease, including those diseases that are the leading cause of blindness among infants, children and adults. The commonest cause of blindness among infants is inherited eye diseases such as congenital cataracts, congenital glaucoma, retinal degeneration, optic atrophy and eye malformations. The control of childhood blindness is a priority of 'VISION2020—The Right to SIGHT'⁽²⁾. Severe visual loss in early childhood adversely affects development, mobility, education, and social and employment opportunities. It has been earlier estimated that there were 1.5 million blind children in the world, of which Asia is home for a

million children⁽³⁾. The prevalence of blindness in children ranges from approximately 0.3/1000 (of total population) in affluent countries to 1.5/1000 in the poorest⁽⁴⁾. Various population-based studies have estimated the prevalence as follows: 0.65/1000 (95%) in children aged 0–15 years in urban and rural Andhra Pradesh⁽⁵⁾ 1.25/1000 in children aged 5–15 years in rural Andhra Pradesh⁽⁶⁾ and 0.53/1000 in children aged 5–15 years in Delhi⁽⁷⁾. Reliable population-based data on the causes of blindness in children are difficult to obtain, particularly in developing countries. Examination of children enrolled in special education is one source, but bias is inherent in all facility-based studies.

This retrospective study was carried out in a rural medical college of north India aimed at documenting the causes of congenital eye diseases.

Method

A review of the case notes of patients presenting at the eye clinic with congenital eye diseases between January 2011 and December 2014 was carried out. Total 200 patients were included in this study and were evaluated for congenital ocular disorders. Complete ophthalmological examination including visual acuity, slit lamp biomicroscopy and fundus examination was carried out in all patients. Investigations like A-Scan, B-Scan, CT Scan, MRI Scan were done wherever required.

Observations & Results

1. Total 200 patients in age group ranging from 2 days -18yr with congenital eye disorders were included in this study. Out of these 112 patients were male and 88 were females.
2. Most common congenital disorder causing preventable blindness was congenital and developmental cataract seen in 38 patients. (19%)
3. Other disorders which cause preventable blindness found were congenital glaucoma seen in 7 patients. (3.5%), and corneal opacity seen in 10 patients. (5%), congenital ptosis in 12 patients (6%) and congenital strabismus in 7 patients (3.5%).
4. Congenital causes of irreversible childhood blindness found were developmental anomalies of eyeball/cornea, iris and lens, retinal dystrophies and optic nerve anomalies.
5. Developmental anomalies of cornea, iris and lens causing irreversible blindness were seen in 46 patients (23%). These included microcornea seen in 4 patients (2%) out of which 2 patients had microcornea with iris coloboma (1%). Sclerocornea was seen in 1 patient (0.5%). Iris coloboma was present in 14 patients (7%) out of which 6 patients had iris coloboma with choroidal coloboma (%). Aniridia was detected in 13 patients (6.5%). In one family mother and her two sons had aniridia with subluxated lens. Ectopia lentis was seen in 8 (4%) patients out of whom 2 patients (1%) had typical signs and symptoms of Marfan's syndrome. Coloboma of lens an uncommon disorder was seen in 2 patients (1%) out of which one patient had atypical lens coloboma with iris coloboma and other patient had bilateral lens coloboma. One child (0.5%) presented with anophthalmos and 3 patients (1.5%) had microphthalmos.
6. Retinal disorders were seen in 25.5% patients. **Retinitis pigmentosa** was present in 34 patients (17%).
7. A very rare variant of RP, **Bardet-Biedl syndrome** was seen in an eight year old female child (0.5%). Retinal examination revealed Bulls eye maculopathy. She had polydactyly, obesity and renal disorder. In 2 patients **Usher,s syndrome (1%)** was present i.e. retinitis pigmentosa with deafness. Retinitis pigmentosa was found to have familial tendency. In few families 2 or more siblings were found to have this disease. Other retinal dystrophies were found in 14 patients (7%). Retinoblastoma commonest tumour of childhood was seen in 3 patients (1.5%). Optic nerve anomalies were seen in 4 patients (2%). Optic nerve pit with typical maculopathy associated with it was found in 1 patient (0.5%), and in 3 patients optic nerve hypoplasia was seen (1.5%).

8. Nystagmus (constant jerky movement of the eyes) and decreased visual acuity was detected in 13(6.5%) patients
9. Other miscellaneous disorders seen were- Phacomatosis involving the eye i.e Sturge-Weber syndrome seen in 2 patients (1%) Neurofibromatosis seen in 1 patient and teratomas like limbal dermoid present in 5 patients and orbital dermoid cyst seen in 6 patients.

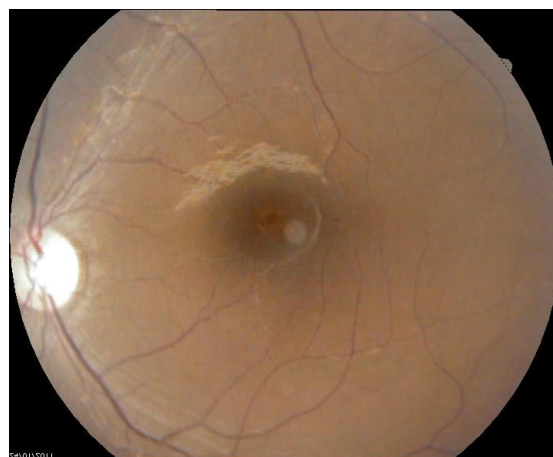
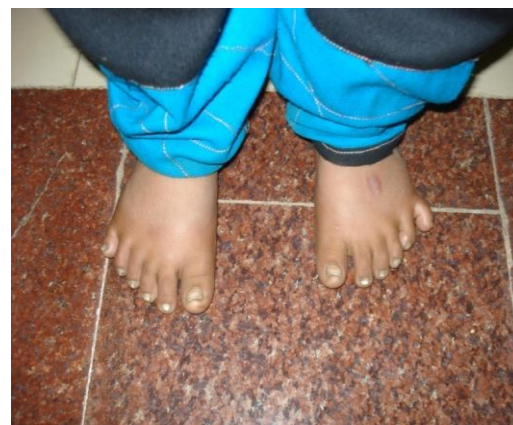
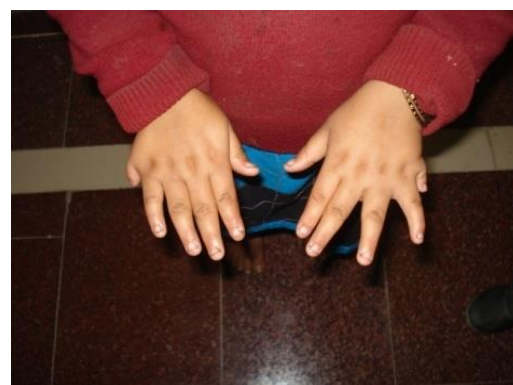
Fig. 1 (a): Fundus photograph showing bulls eye maculopathy



(b), (c): Polydactyly in hands and feet
Fig.1: Bardet-Biedl syndrome showing Bulls eye maculopathy (a) & polydactyly (b,c)

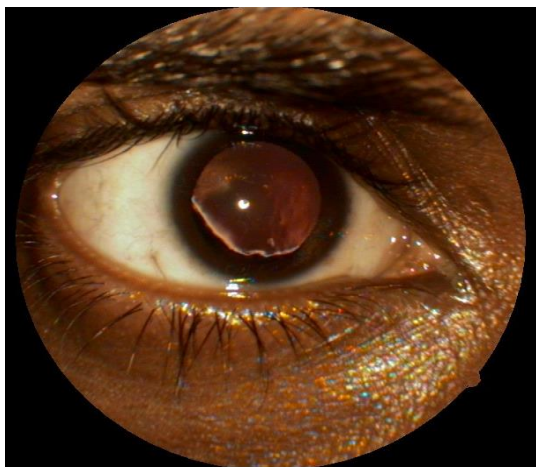


Fig. 2: Clinical photograph showing Subluxated lens with coloboma

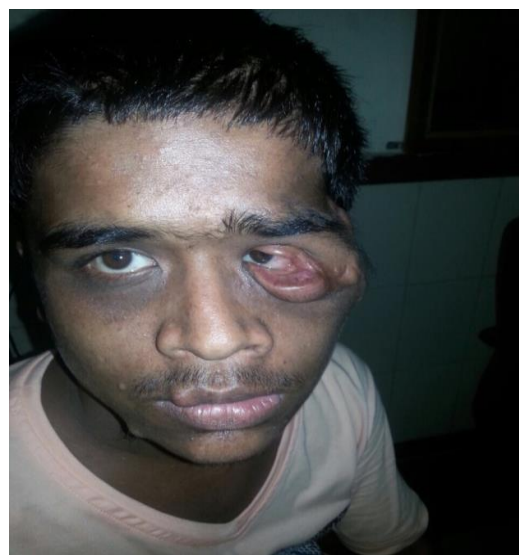
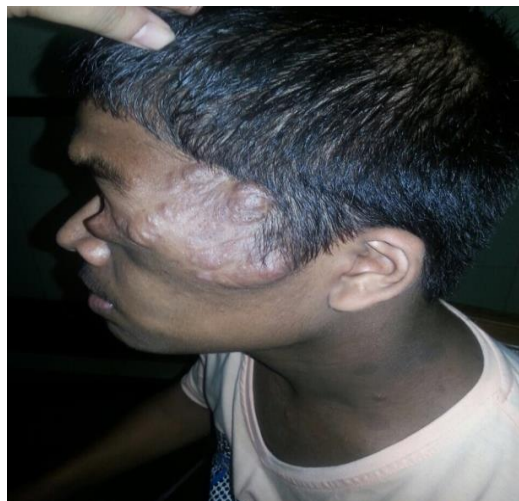
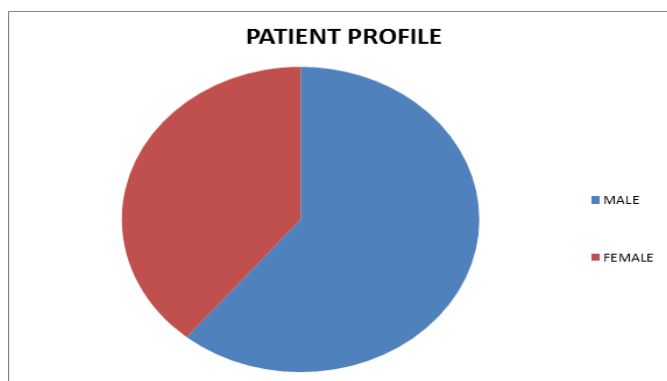
Fig. 4: Clinical photograph of Neurofibromatosis

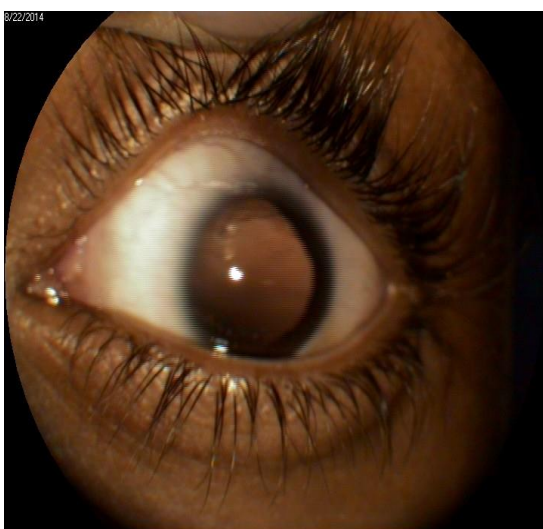
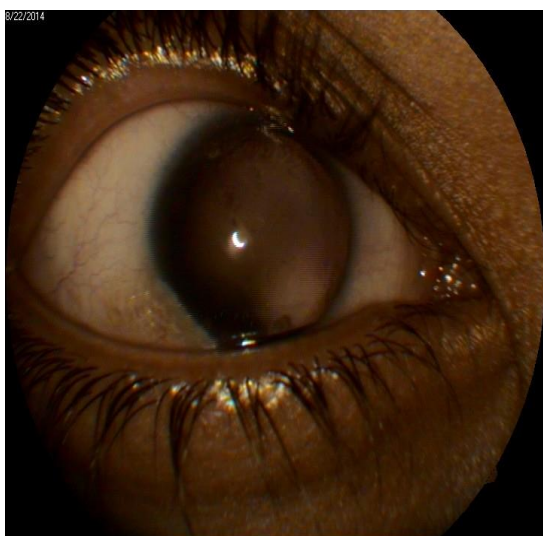
Fig. 3: Clinical photograph of Aniridia

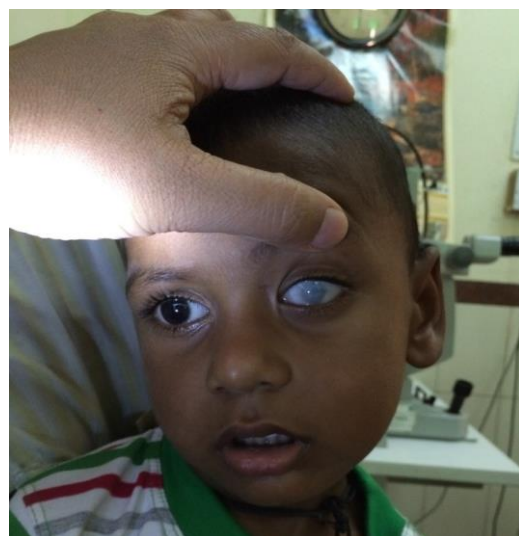

Fig. 5: Clinical photograph of Sclerocornea

**Table 1: showing anatomical sites of congenital anomalies**

Anamoly	No.	Percentage
Anophthalmos	1	0.5%
Microphthalmos	3	1.5%
Diseases of Cornea		
Corneal Opacity	10	5%
Microcornea	4	2%
Sclerocornea	1	0.5%
Diseases of Lens		
Congenital Cataract	38	19%
Congenital Ectopia Lentis	8	4%
Lens Coloboma	2	1%
Diseases of Uvea		
Coloboma	14	7%
Aniridia	13	6.55%
Diseases of Retina		
Retinitis Pigmentosa	34	17%
Other Dystrophies	14	7%
Retinoblastoma	3	1.5%
Diseases of Optic nerve		
Optic nerve pit	1	0.5%
Optic nerve hypoplasia	3	1.5%
Congenital Glaucoma	6	3%
Other Causes		
Idiopathic Nystagmus	13	6.5%
Congenital Strabismus	7	3.5%
Congenital Ptosis	12	6%
Orbital Teratomas	11	5.5%
Phacomatosis	2	1%
Total	200	

Discussion

Childhood blindness remains a significant global health problem. The control of childhood blindness is a priority of 'VISION 2020—The Right to Sight' programme, which is a global initiative that aims to eliminate avoidable blindness by the year 2020⁽²⁾ The problem of childhood blindness is greatest in the developing nations of Asia and Africa where the prevalence of blindness in children (under 16 years) is estimated to be 5 times as high as in the United Kingdom⁽⁸⁾. In order to develop control programs to

prevent childhood blindness in the country, it is necessary to identify important avoidable causes of severe visual impairment and blindness, and monitor changing patterns from time to time. Congenital eye disorders, though rare are important causes of childhood blindness.

Commonest congenital disorder causing blindness in our study was found to be the cataract (19%). S. RAHI et al in a study (1995) concluded that disorders of the lens were seen in 162 children (12.3%). Sixty three had unoperated cataract, 67 children were aphakic

and/or amblyopic and the remaining 32 children had visual loss from postoperative complications⁽⁹⁾ Rogers NK et al in (1995) found congenital cataract is the leading cause of surgically correctable blindness in most developing countries⁽¹⁰⁾. In a study in China it was found that 19% of children had visual impairment from disorders of the lens. Of these 65% were aphakic and/or amblyopic probably as a result of late surgery or inadequate refractive correction with 32% having unoperated cataracts.⁽¹¹⁾ In our study Retinitis pigmentosa and other retinal dystrophies were present in 17% and 7% respectively.

S. RAHI et al (1995) in a study found retinal dystrophies (Leber's amaurosis, retinitis pigmentosa and achromatopsia) and albinism accounted for 19% of cases⁽⁹⁾.

S. Krishnaiah et al. (2012) concluded that retinal blindness was the second most common cause of severe visual impairment/blindness (SVI/BL) (18.9%; n/421) identified in this population⁽¹²⁾The major cause was retinal dystrophy (17.1%; n/419), the finding approximately close to the estimate reported previously from the same population by Hornby SJ et al (2008)⁽¹³⁾W. Min et al (1999) found that retinal causes were responsible for SVI/BL in 282 (24.9%) children. The majority were retinal dystrophies (179, 15.8%) and albinism (15, 1.3%). Retinopathy of prematurity was diagnosed in 22 cases (1.9%). Other retinal disorders, including retinal detachment and retinoblastoma, accounted for the remainder (5.9%)⁽¹¹⁾In our study congenital disorders with autosomal recessive inheritance like, anophthalmos, microphthalmos, coloboma, aniridia, ectopia lentis were seen in 23%. Proper history revealed that most of these patients belonged to rural area with a strong tradition of consanguineous marriages suggesting a genetic recessive aetiology of these autosomal recessive syndromes in these patients due to high consanguinity rate.

S. Rahi et al in a study (1995, 1999) concluded that 23 % of children had SVI/BL definitely attributable to genetic disease. The mode of inheritance in the majority of these children was autosomal recessive. Cataract and optic nerve disease were also important and accounted for approximately half of the autosomally dominant inherited diseases. Consanguineous marriages, which increase the likelihood of autosomal recessive diseases, are common in certain communities in India. First-cousin marriages occur throughout the country and maternal uncle/niece marriages are common in South India. Congenital ocular anomalies (anophthalmos, microphthalmos, coloboma and aniridia) accounted for 22% of children with SVI/BL. These conditions appear to be relatively more important in India than in other developing countries^(4,9).

The highest combined prevalence of microphthalmos and coloboma reported in blind school surveys is 11.2 % in Japan⁽¹⁴⁾Known causes of these congenital anomalies include chromosomal and genetic

disorders, viral infections during pregnancy and certain teratogenic drugs⁽¹⁵⁾

S Krishnaiah et al (2012) found that congenital ocular anomalies (mainly micro ophthalmos, anophthalmos, and phthisis) accounted for 41.4% of severe visual impairment and blindness (SVI/BL) in coastal district population of AP. It can be speculated that congenital anomalies may be due to a genetic disorder, especially due to the fact that the majority of children were born to couples with a history of consanguineous marriage, which is common in this population⁽¹²⁾.

The finding of higher rates of microphthalmos and anophthalmos has been found to be a common finding in many studies conducted earlier on blind children in India⁽⁴⁾, congenital ocular anomalies were responsible for major causes of blindness in 41.3% and 27.4% of children in Maharashtra and Delhi, respectively⁽¹⁶⁾.

Retinal blindness was the second most common cause of SVI/BL (18.9%) identified in this population. The major cause was retinal dystrophy (17.1%)⁽¹⁷⁾. Similar findings were reported by Sil AK, et al in a study "Childhood blindness in India"⁽¹⁸⁾.

Despite adverse effects caused by consanguineous unions, such relationships still occur in many countries. Previous studies have reported that 20–50% of marriages in central and southern Asia are usually consanguineous and it was 10–50% especially in South India⁽¹⁹⁾.The high rates of such marriages in South India is mainly because consanguinity is a deeply rooted cultural tradition in this population. Besides the common perception in favour of consanguineous marriages, there is also a lack of awareness about the definite risks and possibilities for prevention of genetic disorders that is related to consanguinity. A few previous studies conducted in South India have also reported a very high prevalence of consanguinity (36%) and a very low level of awareness (7.6%), with regard to the hazards of consanguineous marriages⁽²⁰⁾.Hence, there is a need for screening, especially in families with consanguineous marriages. Education and counseling in primary health care settings on the effects of consanguineous marriages will also help to address the problem. Therefore, counseling for couples with affected children, by giving reproductive options such as prenatal diagnosis wherever feasible is especially beneficial.

Conclusion

Congenital anomalies are found to be the common cause of blindness in childhood. In common with other developing countries, a large proportion of the childhood blindness in India is avoidable. It would be useful to document the causes of childhood blindness to allow early action against emerging avoidable causes. This study advocates the need of instituting screening programmes at the maternity centers before babies are discharged for early detection of congenital eye

diseases and treatment of those that can cause preventable blindness and the need for premarital counseling to avoid congenital ophthalmic disorders.

Conflict of Interest: None

Source of Support: Nil

References

1. Bodunde OT, Ajibode H (2006). Congenital eye diseases at Olabisi Onabanjo University Teaching Hospital, Sagamu, Nigeria Niger J Med Jul-Sep;15(3):291-4.
2. World Health Organization (1997). Global Initiative for the Elimination of Avoidable Blindness, WHO Publication Number WHO/PBL/97 61. Geneva: WHO.
3. World Health Organization (2009). Fact Sheet No 282.
4. Rahi JS, Gilbert CE, Foster A, Minassian D (1999). Measuring the burden of childhood blindness. Br J Ophthalmol 1999;83:387-388.
5. Dandona L, Williams JD, Williams BC, Rao GN (1998). Population based assessment of childhood blindness in southern India. Arch Ophthalmol;116:545-546.
6. Dandona R, Dandona L, Srinivas M, Sahare P, Narsaiah S, Mun oz SR et al. Refractive errors in children in a rural population in India. Invest Ophthalmol Vis Sci 2002;43: 615-622.
7. Murthy GVS, Gupta SK, Elloveia LB, Mun~oz SR, Pokharel GP, Sanga L et al. Refractive errors in children in an urban population in New Delhi. Invest Ophthalmol Vis Sci 2002;43:623-631.
8. Foster A, Gilbert C (1992). Epidemiology of childhood blindness. Eye;6:173-6.
9. Rahi JS, Sripathi S, Gilbert CE, Foster A (1995). Childhood blindness in India: causes in 1318 blind school students in nine states. Eye;9:545-550.
10. Rogers NK, Strachan IM. Pierre Robin anomalad, maculopathy and autolytic cataract. J Pediatr Ophthalmol Strabismus 1995;32:391-2.
11. W Min, Y Shi and Y Li S J Hornby, Y Xiao, C E Gilbert, A Foster, X Wang, X Liang, H Jing, L Wang (1999), Causes of childhood blindness in the People's. Republic of China: results from 1131 blind school students in 18 provinces doi: 10.1136/bjo.83.8.929
12. Br J Ophthalmol 83: 929-932.
13. S Krishnaiah, B Subba Rao, K Lakshmi Narasamma and G Amit (2012). A survey of severe visual impairment in children attending schools for the blind in a coastal district of Andhra Pradesh in South India Eye 26, 1065-1070.
14. Hornby SJ, Adolph S, Gothwal VK, Gilbert CE, Dandona L, Foster A (2000). Evaluation of children in six blind schools in Andhra Pradesh. Ind J Ophthalmol;48:195-200.
15. Fujiki K, Nakajima A. Yasuda N, Tanabe U, Kabasawa K(1982). Genetic analysis of microphthalmos. Ophthalmic Paediatr Genet;1:139-49.
16. Warburg M (1991). An update on microphthalmos and coloboma. Ophthalmic Paediatr Genet;12:57-6315.
17. Gogate P, Deshpande M, Sudrik S, Taras S, Kishore H, Gilbert C et al (2007). Changing pattern of childhood blindness in Maharashtra, India. Br J Ophthalmol;91:8-12.
18. Sil AK, Gilbert CE (2001). Childhood blindness in India. J Ind Med Assoc;99:10-15.
19. Yunis K, Rafei RE, Mumtaz G (2008). Consanguinity perinatal outcomes and prevention – A view from the Middle East. Neo reviews;9:e59-e65.
20. Nath A, Patil C, Naik VA (2004). Prevalence of consanguineous marriages in a rural community and its effects on pregnancy outcome. Indian J Com Med;29(1):41-43.