

Content available at: <https://www.ipinnovative.com/open-access-journals>

Indian Journal of Clinical and Experimental Ophthalmology

Journal homepage: [www.ijceo.org](http://www.ijceo.org)

## Case Report

# Headache as presenting complaint in choroidal osteoma, a rare association

Alka Tripathi <sup>1,\*</sup><sup>1</sup>Dept. of Ophthalmology, All India Institute of Medical Sciences, Gorakhpur, Uttar Pradesh, India

### ARTICLE INFO

#### Article history:

Received 14-08-2021

Accepted 13-01-2022

Available online 31-03-2022

#### Keywords:

Yellow white tumour

Flat choroidal lesion

Choroidal osteoma

Headache

Nasal field defect

### ABSTRACT

Ophthalmologists play an important role in the evaluation of headache as there is inseparable association between eye and headache. The headache may include facial pain, migraine or neurological pain. Headache may present as a medical emergency or as a routine case in outpatient department. Ophthalmologist play as front line physicians in diagnosing and managing such cases with proper referral if required. Few cases of headache as the presenting symptom in choroidal osteoma have been reported. Cause of headache may be due to blurred vision, sinus involvement, mechanical pressure effect, ischemic damage or an incidental association. The diagnosis of choroidal osteoma is mainly clinical. Majority of the cases remain asymptomatic and choroidal osteoma may be an incidental finding in a patient presenting with other complaints. This case report throws light on complete ophthalmic evaluation of every case of headache to ensure no important findings are missed.

This is an Open Access (OA) journal, and articles are distributed under the terms of the [Creative Commons Attribution-NonCommercial-ShareAlike 4.0 License](https://creativecommons.org/licenses/by-nc-sa/4.0/), which allows others to remix, tweak, and build upon the work non-commercially, as long as appropriate credit is given and the new creations are licensed under the identical terms.

For reprints contact: [reprint@ipinnovative.com](mailto:reprint@ipinnovative.com)

## 1. Introduction

Ophthalmologists play an important role in the evaluation of headache as there is inseparable association between eye and headache.<sup>1</sup> The headache may include facial pain, migraine or neurological pain. There are several cause of primary and secondary headache, secondary headache being more common in >40 yrs age group. Migraines with or without aura are a very common cause of primary headache especially in females and have a prevalence of 5-25%.<sup>2</sup> Other secondary causes of headache associated with visual disturbance are refractory error, papilloedema, optic neuritis and many more. Headache may present as a medical emergency or as a routine case in outpatient department. Ophthalmologist play an important role in diagnosing and managing such cases with proper referral if required. Thorough ophthalmic evaluation, which includes proper refraction assessment, is important as it can identify a

treatable headache etiology. Very few cases of headache as a presenting feature in choroidal osteoma have been reported in the literature. This case report throws light on complete ophthalmic evaluation of every case of headache to ensure no important or incidental findings are missed.

## 2. Case Report

A 16-year-old female presented with complain of off and on frontal headache for 3 months. The headache was dull, around the forehead, continuous and relieved with painkillers or sometimes rest. Headache was more during the evening hours after long hours of studying or routine work. Headache was not associated with vomiting, nausea, photophobia, dizziness, scintillating scotomas or atypical aura. She had no history of ocular trauma, head trauma, redness or pain in eye, glare and colored halos. There was no history of headache triggered by exercise, cough/sneezing and valsalva. Headache was not associated with change in personality, new-onset neurological deficit or cognitive

\* Corresponding author.

E-mail address: [tripathyalka21@gmail.com](mailto:tripathyalka21@gmail.com) (A. Tripathi).

dysfunction and altered consciousness. Change in posture, onset of menstruation had no relation with headache. Birth and sibling history was normal. On examination VA was 20/60OD and 20/20 OS. BCVA was 20/40 OD (+0.75DC 10\*) and 20/20 OS. IOP was 14 OD and 16 OS. Anterior segment examination was normal. Field tested by confrontation revealed a nasal field defect in the right eye, left eye field was normal.

### 2.1. Fundus examination

Ophthalmoscopic examination revealed an oval, irregularly elevated, yellow white tumor between the optic disc and the macula of right eye. There were also irregular orange pigment clumps on the tumor surface. The borders were well demarcated with an irregular scalloped outline. Size of the lesion was 2\*6 disc diameters. (Figure 1)

### 2.2. Optical coherence tomography

Time-domain optical coherence tomography (OCT) showed marked thinning to absence of the inner segment/outer segment photoreceptor junction with normal foveal contour and RPE irregularity nasally.(Figure 2)

### 2.3. Fundus Fluorescein Angiography

Early, patchy hyperfluorescence with intense late staining.

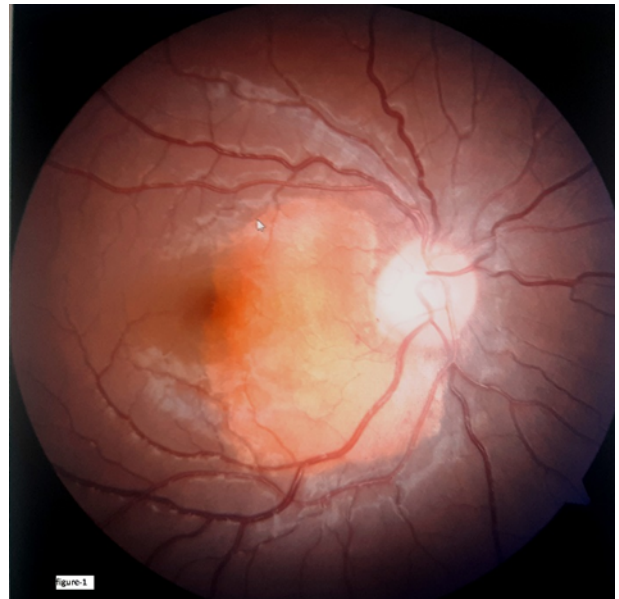### 2.4. Ultrasonography

B-scan ultrasonography was performed, demonstrating a relatively echolucent vitreous. In the posterior pole, a flat choroidal lesion with very high reflectivity was observed in right eye. (Figure 3)

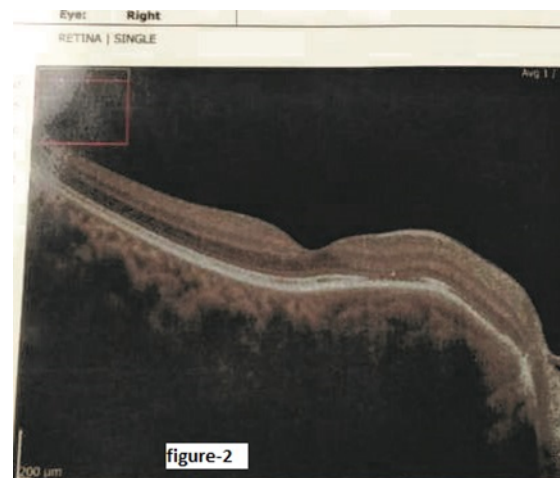
Based on the clinical examination and investigations a provisional diagnosis of choroidal osteoma right eye was made. No treatment was advised (symptomatic treatment and assurance given). Patient was asked to remain in follow up and review after 6 months. She was also told about the dangerous signs (metamorphopsia, sudden decrease in vision) and to consult immediately if she experiences any.

## 3. Discussion

Choroidal osteoma is a benign ocular tumour of unknown aetiology. Its first case was presented by Van Dyk at the Verhoeff society meeting in 1975 and reported by Gass<sup>3</sup> et al. The diagnosis of choroidal osteoma is mainly clinical. Majority of the cases remain asymptomatic and choroidal osteoma may be an incidental finding in a patient presenting with other complaints. Patients usually present with symptoms of blurred vision, metamorphopsia,<sup>4</sup> photophobia and visual field defects corresponding to the location of the tumor. It is usually unilateral in 75% of cases.<sup>5</sup> The most common age of presentation is in second or third decades of life and has predilection for young

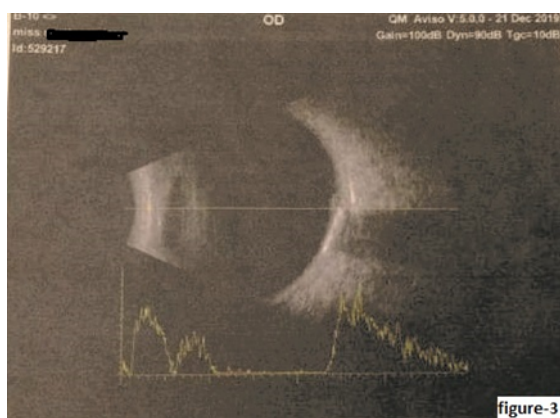


**Fig. 1:** Fundus photograph shows oval, irregularly elevated, yellow-white tumor between the optic disc and the macula of the right eye with irregular orange pigment clumps on the tumor surface. The size of the lesion was 2\*6 disc diameters



**Fig. 2:** (Optical coherence tomography) - Time-domain optical coherence tomography(OCT) showed marked thinning to absence of the inner segment/outer segment photoreceptor junction with normal foveal contour and RPE irregularity nasally

healthy females with no history of systemic or ocular disease. Few cases of headache as the presenting symptom have been reported. Cause of headache may be due to blurred vision or sinus involvement.<sup>6</sup> The frontal sinus is the most common site of origin of paranasal sinus osteomas, followed in frequency by the ethmoid and maxillary sinuses. A rare case report of 15-year-old girl with bilateral choroidal osteoma associated with advanced bilateral optic atrophy was reported.<sup>7</sup> Probable cause include mechanical pressure



**Fig. 3:** Ultrasonography- B-scan demonstrated a relatively echolucent vitreous and a flat elevated choroidal lesion

effect and ischemic damage. A case of a female with decrease in vision and migraine was reported which was found to be associated with choroidal osteoma. In the reported case headache might be due to refractory error as patient mentioned some improvement after using glasses and choroidal osteoma was an incidental finding.

Choroidal osteoma is characterised by the presence of spongy mature cancellous bone within the choroid. On dilated fundus examination tumor is commonly located in the juxtapapillary or peripapillary region but rarely it may extend into the macular area. Tumor colour varies from yellow-white to orange-red with or without overlying clumps of pigment. Colour variations are due to grades of calcification. Orange-red colour denotes areas of calcification and white-yellow decalcification.<sup>4</sup> The shape is typically round or oval with well circumscribed borders. Decalcification of a choroidal osteoma leads to gradual atrophy of the tumor and poor visual acuity. Optical coherence tomography (OCT) show areas of varying reflectivity which depends on the calcification of the mass. Multiple hyperreflective dots surrounding hyporeflexive spaces can be found on OCT. OCT also excludes the presence of SRF which is indicative of underlying CNVM.<sup>8</sup> FFA in typical cases shows an early hyperfluorescence with a mottled appearance which is followed by late and persisting diffuse hyperfluorescence. Leakage of the fluorescein indicates neovascularisation. The bony areas of the tumour show variable blockage of the choroidal vasculature. Ultrasonography is usually confirmatory; a B-scan typically exhibits a slightly elevated choroidal mass with high reflectivity and acoustic shadowing.<sup>9</sup>

For asymptomatic cases of choroidal osteoma observation is mandatory, with fundus examination at regular intervals and monitoring of signs of CNV. Treatment for symptomatic cases include anti-vascular endothelial growth factor (anti-VEGF) drugs that have been used to treat CNV secondary to choroidal osteoma with promising result.<sup>10</sup> PDT (photodynamic therapy) and anti-VEGF when

used in combination have good results. Recent studies have demonstrated that anti-vascular endothelial growth factor treatment alone or with PDT had a satisfactory outcome in terms of improvement in the anatomy of the area and visual acuity

#### 4. Conclusion

Choroidal osteoma is a benign ossifying tumor of the choroid of unknown aetiology. It may result in CNVM, hemorrhagic detachment or decalcification leading to impaired vision. Headache is an uncommon presentation of choroidal osteoma. However this case warrants complete ophthalmological check up including field and detailed fundus examination so that asymptomatic cases of such rare entity can not be missed.

#### 5. Source of Funding

None.

#### 6. Conflict of Interest

The authors declare no conflict of interest.

#### References

1. Friedman DI. Headache and the eye. *Curr Pain Headache Rep.* 2008;12(4):296–304.
2. Yeh WZ, Blizzard L, Taylor BV. What is the actual prevalence of migraine. *Brain Behav.* 2018;8(6):e00950.
3. Gass JD, Guerry RK, Jack RL, Harris G. Choroidal Osteoma. *Arch Ophthalmol.* 1978;96(3):428–35.
4. Ryan SJ, Ryan. *Retina.* vol. Vol 1. 4th ed. Los Angeles: Mosby; 2006. p. 819–28.
5. Empeslidis T, Imrani U, Konidaris V, Mushtaq F, Fotiou P, Kumar P, et al. Diagnosis and Monitoring of Choroidal Osteoma through Multimodal Imaging. *Case Rep Med.* 2014;2014:393804. doi:10.1155/2014/393804.
6. Lanning LB, Klinem HW, Davidson JD, Wilmes FJ. Bilateral choroidal osteomas associated with fatal systemic illness. *Am J Ophthalmol.* 1982;93(2):192–7.
7. Murthy R, Das T, Gupta A. Bilateral choroidal osteoma with optic atrophy. *J AAPOS.* 2010;14(5):438–40.
8. González-Guijarro J, García M, Casas AP. Choroidal osteoma and choroidal neovascularization. *Arch Soc Esp Ophthalmol.* 2003;78(10):571–4.
9. Lehto K, Tommila PV, Karma A. Choroidal osteoma: clues to diagnosis. *Acta Ophthalmol Scand.* 2007;85(2):218–20.
10. Pandey N, Guruprasad A. Choroidal osteoma with choroidal neovascular membrane: successful treatment with intravitreal bevacizumab. *Clin Ophthalmol.* 2010;4:1081–4.

#### Author biography

Alka Tripathi, Assistant Professor  <https://orcid.org/0000-0002-8103-926X>

**Cite this article:** Tripathi A. Headache as presenting complaint in choroidal osteoma, a rare association. *Indian J Clin Exp Ophthalmol* 2022;8(1):169-171.