

Content available at: <https://www.ipinnovative.com/open-access-journals>

Indian Journal of Clinical and Experimental Ophthalmology

Journal homepage: [www.ijceo.org](http://www.ijceo.org)

## Case Report

# Mixed infection of rhino-orbito-cerebral mucormycosis and aspergillosis with culture proven aspergillus endophthalmitis in a post covid patient- A case report

Rahna P<sup>1</sup>, Silni Chandra<sup>1,\*</sup>, Padma B Prabhu<sup>1</sup>, Ranjini K<sup>1</sup>

<sup>1</sup>Dept. of Ophthalmology, Government Medical College, Kozhikode, Kerala, India



## ARTICLE INFO

### Article history:

Received 07-06-2021

Accepted 24-09-2021

Available online 31-03-2022

### Keywords:

Rhino orbito cerebral aspergillosis

Mucormycosis

Covid and eye

Retrolbulbar amphotericin

Fungal endophthalmitis

## ABSTRACT

Rhino orbito cerebral mucormycosis has become very common in this covid pandemic. Fungal endophthalmitis is also being increasingly reported. All fungal infections may not be just mucor. This is to report a case of rhino orbito cerebral mucormycosis and aspergillosis with aspergillus endophthalmitis, in a post covid patient who had required intensive care during covid illness. A post covid 73 years old female with type 2 diabetes mellitus and hypertension presented with sudden onset painful loss of vision in right eye with right sided headache. Anterior segment examination showed a streak hypopyon with fundus showing severe vitritis. Diagnostic nasal endoscopy and radiological features were suggestive of probable rhino orbital mucor mycosis, Patient was started on systemic amphotericin B with intravitreal and retro orbital amphotericin. The KOH mount and culture of the vitreous aspirate showed aspergillus while the histopathology of the sinus tissue revealed mucor along with aspergillus. Fungal endophthalmitis is making an appearance in a big way in this covid pandemic Early diagnosis and proper treatment is the only way to defend against these life-threatening fungi. Diagnostic nasal endoscopy with biopsy and vitreous tap for culture as well as histopathology taken before initiating treatment will go a long way in making a correct diagnosis.

This is an Open Access (OA) journal, and articles are distributed under the terms of the [Creative Commons Attribution-NonCommercial-ShareAlike 4.0 License](https://creativecommons.org/licenses/by-nc-sa/4.0/), which allows others to remix, tweak, and build upon the work non-commercially, as long as appropriate credit is given and the new creations are licensed under the identical terms.

For reprints contact: [reprint@ipinnovative.com](mailto:reprint@ipinnovative.com)

## 1. Introduction

Novel corona virus has taken a heavy toll all over the world, with a huge number of mortalities and many more morbidities. This pandemic has put many patients on prolonged intensive care, on systemic steroid and oxygen therapy with deranged blood sugar values which has brought different types of opportunistic infections to the fore.<sup>1</sup>

The ophthalmic manifestation in these patients varies from simple conjunctivitis to life threatening rhino orbital cerebral involvement.<sup>2</sup> Now the sight and life threatening mucor has took the attention of common people in the name “black fungus”.

Mucormycosis is a filamentous fungus which can cause life-threatening infections in human. It is seen increasing in number now, in this covid pandemic which can be attributed to usage of corticosteroids and also decrease in regular health check-up in diabetics which has resulted in an uncontrolled blood sugar level which predisposes to mucormycosis. The clinical manifestation of mucormycosis include rhino orbito cerebral, cutaneous, gastrointestinal, pulmonary and disseminated infections, hallmark being its invasive nature and rapid progression to tissue necrosis, and causing infarction due to angioinvasion.

Aspergillus is much more common opportunistic mould reported to be the most common systemic fungal infection seen in the covid patients which include pulmonary aspergillosis. As mucor, this fungus is also angioinvasive, causing tissue necrosis and dreadful invasive rhino orbito

\* Corresponding author.

E-mail address: [drsilni@gmail.com](mailto:drsilni@gmail.com) (S. Chandra).

cerebral aspergillosis in immunocompromised. There are reports of the same in immunocompetent.

This is a case report of rhino orbito cerebral mucormycosis and aspergillosis with endogenous culture proven aspergillus endophthalmitis in a post covid patient.

## 2. Case Report

A 73 years old female, known diabetic and hypertensive for 6 years presented with sudden onset painful loss of vision in right eye for 2 days. She developed loss of vision 5 days after she was discharged from a private hospital after taking treatment for covid pneumonia and post covid cerebrovascular accident. During the hospital stay she had severe headache for which an MRI of the brain was done which showed bilateral sinusitis with acute infarct in right occipitotemporal region. She was in intensive care on oxygen support along with parenteral antibiotics and steroids for 20 days. On review, diagnostic nasal endoscopy was done which showed black eschar in right middle meatus and KOH mount showed fungal filaments suggestive of mucor and was referred here as rhino orbital mucormycosis.

On presentation her extra ocular movements were full, there was no proptosis or periorbital edema. Her BCVA in the right eye was HM+ with PR accurate in all quadrants and BCVA in the left eye was 6/12 N6. Intraocular pressure was digitally comparable in both the eyes, field by confrontation was full in the left eye and pupillary reaction was sluggish in both the eyes.

In the right eye cornea had minimal folds in the descemet's membrane and anterior chamber had a streak of hypopyon, fundus showed severe vitritis and haemorrhage in the posterior pole. Left eye was within normal limits. B scan of the right eye showed high intensity echoes in the posterior vitreous with partial detachment of the posterior vitreous with thickening of the retinochoroidal complex. (Figure 1)

With a provisional diagnosis of rhino orbital mucormycosis with fungal endophthalmitis she was started on Inj. amphotericin B, Inj. cefotaxime and topical fortified vancomycin, amikacin and amphotericin B eye drops. In the next 2 days her ocular signs and symptoms increased, there was mild proptosis and restricted depression, anterior segment examination showed conjunctival congestion and chemosis, and vision decreased to perception of light with accurate projection of rays in all quadrants.

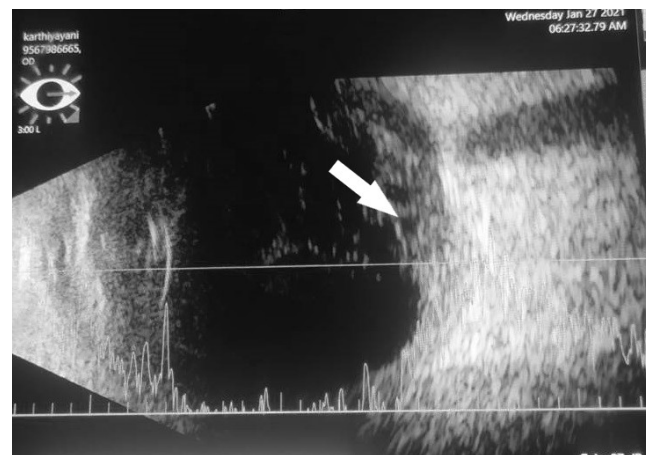MRI of the brain with contrast was done which showed signs suggestive of infectious optic neuritis with endophthalmitis. Polypoidal mucosal thickening of all sinuses bilaterally suggestive of fungal sinusitis was also seen along with sub-acute infarct involving right Inferomedial, temporal lobe and hippocampus (Figure 2)

In keeping with the probable diagnosis of fungal endophthalmitis with rhino orbital mucormycosis, intravitreal amphotericin B 0.005mg/0.1ml and vancomycin

1 mg/0.1ml was given. Retrobulbar injection of 1ml amphotericin B 3.5 mg/ml was also given. Vitreous tap was sent for KOH, gram stain and culture.

Blood agar culture of the vitreous tap yielded *Aspergillus* sp. (Figure 3 a, b) and Sabouraud's dextrose agar culture of the sinus aspirate also showed aspergillus colonies. Blood culture and urine culture yielded no organisms.

Patient underwent endoscopic sinus debridement with removal of the blackish middle turbinate, and specimen was sent for culture and histopathological examination. Culture of this tissue yielded aspergillus species. Histopathological examination of the debrided tissue from the sinus and nasal cavity revealed mixed growth of mucor and aspergillus. So, the patient is still continuing on systemic amphotericin B and a repeat intravitreal injection of amphotericin B and vancomycin was administered after a gap of 5 days. Systemically the patient is improving and her ocular status is also under control.

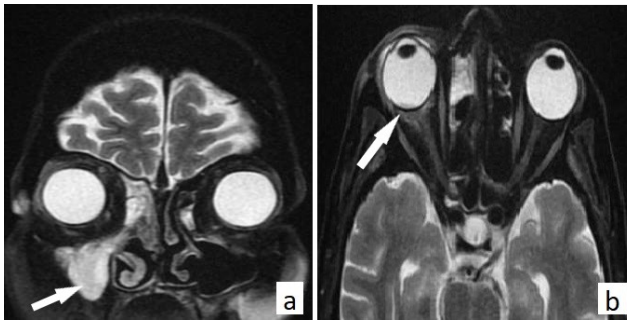


**Fig. 1:** B scan showing high intensity echoes in the posterior vitreous with thickening of the retinochoroidal complex

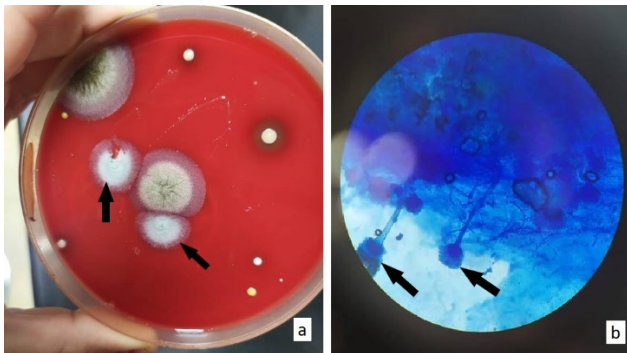
## 3. Discussion

The increased host immune reaction and hypercoagulable state are the main causes of morbidities and mortalities in COVID 19 pandemic. So, most of the covid patients are treated with steroids and anticoagulants for a long duration. The mucor, aspergillus and candida cases reported are attributed to this extensive use of corticosteroids.

Endogenous endophthalmitis is a rare entity and has been very infrequently reported in covid cases. It has a very poor prognosis particularly in cases of fungal endogenous endophthalmitis. Shah et al. reported 4 cases of presumed fungal endogenous endophthalmitis in post COVID 19 patients. But they couldn't make a microbiological diagnosis.<sup>3</sup> Intravenous line related candidemia has increased fivefold in covid pandemic.



**Fig. 2:** a: MRI brain with contrast- coronal T2w image showing mucosal thickening in right maxillary, ethmoid and frontal sinus; b- Axial T2 fat suppressed image showing mild inflammatory thickening of retrobulbar portion of right optic nerve with thickening of posterior globe layer, irregular enhancing soft tissue phlegmon in retro orbital region in keeping with Infectious optic neuritis and endophthalmitis. Polypoidal mucosal thickening of maxillary, ethmoid, sphenoid s/o fungal sinusitis



**Fig. 3:** a: Blood agar showing colonies of aspergillus sp. b: Image under microscope showing aspergillus conidiophore with septate hyphae

Darius et al reported 7 cases of endogenous endophthalmitis in post covid, fungal pathogens identified in 5 of them, 4 was candida and 1 was aspergillus.<sup>4</sup>

This case showed mixed growth of aspergillus and mucor. The antifungal of choice for mucormycosis is amphotericin B, retrobulbar injection of amphotericin also has shown good response in orbital mucor mycosis. The treatment of choice for aspergillus is voriconazole. In case of rhino orbital aspergillosis voriconazole has shown much more intravitreal penetration and less systemic toxicity compared to amphotericin B.<sup>5</sup> Aspergillus is also sensitive to amphotericin so we persisted with systemic and local amphotericin in our case. Histopathology is the mainstay in the diagnosis of fungal infection but a negative histopathology may arise secondary to lack of proper tissue sampling or sparse fungal forms if sample is taken after the treatment is initiated.<sup>6</sup>

#### 4. Conclusion

All fungal rhino orbital lesions are not mucormycosis; aspergillus is also a devastating fungus though not as dreadful as mucor. Chance of a mixed infection should be kept in mind while treating these cases. Fungal endogenous endophthalmitis is also making an appearance in a big way in this covid pandemic. Early diagnosis and proper treatment is the only way to defend against these life-threatening fungi. Diagnostic nasal endoscopy with biopsy and vitreous tap for culture as well as histopathology will go a long way in making a correct diagnosis.

#### 5. Source of Funding

None.

#### 6. Conflict of Interest

The authors declare no conflict of interest.

#### References

1. Ting DSJ, Deshmukh R, Said DG, Dua H. Care for critically ill patients with COVID-19: don't forget the eyes. *Eye (Lond)*. 2020;34(7):1253–4.
2. Bertoli F, Veritti D, Danese C, Samassa F, Sarao V, Rassu N, et al. Ocular Findings in COVID-19 Patients: A Review of Direct Manifestations and Indirect Effects on the Eye. *J Ophthalmol*. 2020;p. 9. doi:10.1155/2020/4827304.
3. Shah KK, Venkatramani D, Majumder PD, Indian J Ophthalmol. A case series of presumed fungal endogenous endophthalmitis in post COVID-19 patients. *Indian J Ophthalmol*. 2021;69(5):1322–5.
4. Shroff D, Narula R, Atri N, Chakravarti A, Gandhi A, Neelam S, et al. Endogenous fungal endophthalmitis following intensive corticosteroid therapy in severe COVID-19 disease. *Indian J Ophthalmol*. 2021;69(7):1909–14.
5. Peral-Cagigal B, Redondo-González LM, Verrier-Hernández A. Invasive maxillary sinus aspergillosis: A case report successfully treated with voriconazole and surgical debridement. *J Clin Exp Dent*. 2014;6(4):e448–51.
6. Ning A, Kocharyan A, Brown WC, D'Anza B. Chronic Invasive Fungal Sinusitis With Negative Histopathology: A Diagnostic Challenge. *Ear Nose Throat J*. 2021;doi:10.1177/0145561320973773.

#### Author biography

**Rahna P**, Junior Resident

**Silni Chandra**, Assistant Professor

**Padma B Prabhu**, Additional Professor

**Ranjini K**, Additional Professor

**Cite this article:** Rahna P, Chandra S, Prabhu PB, Ranjini K. Mixed infection of rhino-orbito-cerebral mucormycosis and aspergillosis with culture proven aspergillus endophthalmitis in a post covid patient- A case report. *Indian J Clin Exp Ophthalmol* 2022;8(1):163-165.