

Content available at: <https://www.ipinnovative.com/open-access-journals>

Indian Journal of Clinical and Experimental Ophthalmology

Journal homepage: [www.ijceo.org](http://www.ijceo.org)

## Original Research Article

## Current scenario of ocular morbidity in severe acute childhood malnutrition in central part of India

Divya Raichandani<sup>1,\*</sup>, Kavita Kumar<sup>1</sup>, Aditi Dubey<sup>1</sup>, Sheetal Morskole<sup>1</sup>, Shreya Tyagi<sup>1</sup><sup>1</sup>Dept. of Ophthalmology, Gandhi Medical College, Bhopal, Madhya Pradesh, India

## ARTICLE INFO

## Article history:

Received 24-09-2021

Accepted 09-10-2021

Available online 31-03-2022

## Keywords:

Anterior segment

Ocular morbidity

Prevalence

Sam

Vitamin a deficiency

## ABSTRACT

**Introduction:** The study aimed to assess the prevalence of ocular involvement in children 6 months to 5 years attending tertiary care centre with Severe Acute Malnutrition and to detect the associated risk factors for ocular morbidity in severe acute malnutrition.

**Methodology:** This hospital based observational study was carried out at Gandhi Medical College, during the study period of 2 years on children diagnosed with SAM belonging to 6 months to 5 years of age. Detailed history was obtained and physical, systemic and ocular examination was done.

**Results:** A total of 100 severe acute malnourished children were included. Prevalence of ocular involvement in severe acute malnourished children was 72%. Conjunctival pallor was observed in 71.5% eyes and retinal hemorrhages were most common posterior segment finding. Vitamin A deficiency signs were observed in 17 eyes (8.5%). Higher birth order and number of sibling was significantly associated with higher incidence of ocular manifestations ( $p < 0.05$ ). However, other variables showed no significant association between other variables and ocular manifestations ( $p > 0.05$ ).

**Conclusion:** Training should be given to health workers at the primary health care level and health centers on counseling mothers on feeding, growth monitoring, the preventable eye blinding diseases and hygiene during the vaccination sessions and early referral of children with eye signs to hospitals. Also education of couple regarding proper nutrition of mother and child should be encouraged and couples should be insisted to have not more than two children.

This is an Open Access (OA) journal, and articles are distributed under the terms of the [Creative Commons Attribution-NonCommercial-ShareAlike 4.0 License](https://creativecommons.org/licenses/by-nc-sa/4.0/), which allows others to remix, tweak, and build upon the work non-commercially, as long as appropriate credit is given and the new creations are licensed under the identical terms.

For reprints contact: [reprint@ipinnovative.com](mailto:reprint@ipinnovative.com)

## 1. Introduction

Childhood malnutrition is a major public health problem in India. It is one of the biggest contributor to under-five mortality due to increased susceptibility to infections and slow recovery from illness.<sup>1</sup> Children are in the process of growth and development, therefore are more prone to develop nutritional deficiencies.

As per WHO<sup>2</sup> malnutrition is a cellular imbalance between supply of nutrients and energy and body demand for them to ensure growth maintenance and specific

functions. In 2019, globally one hundred forty four million under five children were stunted and 47 million were wasted.<sup>3</sup>

Severe Acute Malnutrition is the most severe and visible form of undernutrition. In 2017, globally around 50 million under 5 children were acutely malnourished.<sup>4</sup> As nutrients are required for maintenance of ocular health therefore ocular involvement in malnourished children is quite common and more serious during early childhood. It has varied presentation ranging from asymptomatic cases to permanent blindness, thus is an important cause of preventable blindness and is to be taken care of. Deficiencies of retinol, folate, and minerals like iron,

\* Corresponding author.

E-mail address: [docrai07@gmail.com](mailto:docrai07@gmail.com) (D. Raichandani).

magnesium and potassium are usually seen in SAM. Among these, deficiency of retinol is most important as it may lead to keratomalacia and permanent blindness. It has been estimated that approximately 250,000 to 500,000 malnourished children go blind each year from a deficiency of vitamin A.<sup>5</sup>

Prevention of xerophthalmia is of utmost importance in preventing early childhood blindness. Vitamin A deficiency is one of the most important cause of preventable blindness in children. It has been a nutritional problem of public health significance in India. Besides vitamin A deficiency, which has major ocular features, other vitamin deficiencies also effect the eye.<sup>6</sup> By looking at these facts, there is a need of this study to know the nature, magnitude and severity of ocular morbidity in SAM and to assess its institutional prevalence, also to detect the associated risk factors with nutritional deficiencies in younger vulnerable group of children with the hope, that it would provide useful information regarding magnitude of the problem and would lead to a better understanding of related factors, enabling us to tackle it more effectively and help us to improve parameters of nutrition, by increasing awareness, education and information regarding nutrition and vaccination.

Aims of this study were

1. To study the ocular morbidity in children 6 month-5 years with Severe Acute Malnutrition.
2. To assess the prevalence of ocular involvement in children 6 month-5 years attending tertiary care centre with Severe Acute Malnutrition.
3. To detect the associated risk factors for ocular morbidity in Severe Acute Malnutrition.

## 2. Materials and Methods

This hospital based observational study was carried out at tertiary care centre in Department of Ophthalmology in collaboration with Department of Pediatrics, during the study period of 2 years i.e. from 1<sup>st</sup> November 2018 to 30<sup>th</sup> September 2020. Children were diagnosed to be SAM by Pediatricians according to criteria defined by WHO and UNICEF as any of the following

1. Weight-for-height < -3SD (or z scores) and/ or
2. Visible severe wasting and/or
3. Presence of bipedal edema and/or
4. Mid-upper arm circumference < 11.5cm

All children in age group of 6 months to 5 years, either admitted in pediatric ward or attending ophthalmic OPD and whose parents were willing to participate in the study were included. Children less than 6months and more than 5 years were excluded.

Before commencing the study, Ethics committee approval was obtained. Written consent was obtained from all the parents/care givers.

Socio-demographic profile of the cases were recorded such as age, sex, socio economic status etc. Detailed history including regarding birth history (birth order, birth weight, mode of delivery, any birth complications, history of Exclusive Breast Feed), present ocular, medical and surgical history of child, history of vitamin A intake, treatment history. Immunization status was recorded based on immunization cards and verbal record from mothers.

The chief ocular and other complaints with their duration were noted. The history of presenting illness was enquired in detail including the mode of onset of symptoms with duration from mother/care taker. A detailed history of diet and dietary habits of each patient was noted. A past history of general and ocular illness was noted to know whether the patient was chronically ill and/ or suffered from any eye disease of significance.

Detailed family history including parents occupation, family per capita income, parents educational status, number of siblings and any similar complaint in any of them was noted.

All the patients were subjected to detailed general and physical examination and height, weight, skin/hair changes, pitting edema over extremities of every child was noted. Anthropometric measurements were taken using standard technique and instruments. All the systems were examined with emphasis on GIT and respiratory tract. The cases were subjected to through ocular examination. Recording of visual acuity in severely comorbid infants and younger age group children was not possible. Wherever possible, visual acuity measurement was done, i.e. for children under 2 years, Binocular Fixation Method and 2-3 years the preferential gaze method (Teller visual acuity cards at 55 cm) was used, making the correlation with the Snellen chart. And for children aged 3 to 5 years visual acuity was measured using the table of figures and Snellen at 6 meters. Ocular adnexa as well as anterior segment of the eye, including conjunctiva, sclera, cornea, anterior chamber, pupil and lens were examined in a good diffuse light using a pen torch and a binocular hand held loupe. Signs of protein-energy malnutrition (lid oedema, chemosis, external infections) and vitamin-A deficiencies (conjunctival and corneal xerosis, Bitot's spots, corneal scars or xerophthalmia) were looked.

The cornea was examined using the hand held binocular loupe; and stained with fluorescein after application of topical anaesthesia, if the normal luster of the cornea was lost. Full mydriasis was obtained for every patient using 1% Tropicamide eye drops and the posterior segment was examined using direct and indirect ophthalmoscope using lid speculum. Particular attention was offered for optic atrophy, optic neuritis, xerophthalmic fundus, macular pigmentation and retinal haemorrhages. Further, investigations such as CBC, LFT, RFT, serum proteins and serum electrolytes were done.

### 2.1. Statistical analysis

The collected data was compiled in MS excel sheet and a master sheet was constructed to arrange the data, and the data was analysed using IBM SPSS software 20. Table of frequencies was drawn and percentage was calculated for relevant variables. On categorical data, chi-square test was used for categorized variables at 95% confidence level ( $P= 0.05$ ).  $P$  value  $\leq 0.05$  was considered to indicate significance.

### 3. Results

A total of 100 severe acute malnourished children belonging to age range of 6 months to 5 years (60 months) were enrolled and screened for presence of ocular manifestation.

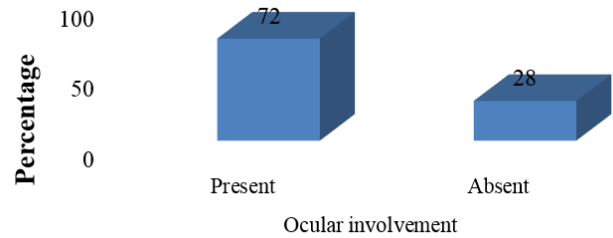
**Table 1:** Distribution according to socio-demographic profile of cases

Gender	No. of cases	Percentage
Females	52	52
Males	48	48
<b>Age (months)</b>		
6-12	58	58
13-24	31	31
25-36	07	07
37-48	04	04
<b>Birth weight</b>		
<2.5 kg	43	43
2.5-3.0kg	31	31
>3.0 kg	07	07
Don't know	19	19
<b>Immunization status</b>		
Fully Immunized	73	73
Partially Immunized	19	19
Not Immunized	08	08
<b>Exclusive Breast Feeding</b>		
Present	32	32
Absent	68	68
<b>Socioeconomic status</b>		
Upper	01	01
Upper Middle	02	02
Lower Middle	20	20
Upper Lower	55	55
Lower	22	22
<b>Comorbidities</b>		
Anemia	78	78
Others	22	22

Table 1 reveal sociodemographic details of the children diagnosed as SAM. Slight female preponderance for severe acute malnutrition was observed with male:female ratio of 1:1.1. Majority of children belonged to 6 months to 12 months of age group (58%). Majority of children diagnosed as SAM had low birth weight i.e. <2.5 kg (43%). About 73% children were fully immunized and history of exclusive

breast feeding was absent in majority i.e. 68% cases.

Among children with severe acute malnutrition, most common comorbidity was anemia (78%).



**Fig. 1:** Ocular involvement in cases

In present study, prevalence of ocular involvement in severe acute malnourished children was 72%.

Out of 72 cases with ocular involvement, bilateral involvement was observed in 68 (94.4%) cases whereas unilateral involvement was observed in 2 (2.8%) cases. However in 2 (2.8%) cases both unilateral as well as bilateral involvement was noted due to multiple manifestations. Conjunctival pallor was most common ocular manifestation in 48 (70.6%) cases in cases with bilateral involvement.

Anterior segment findings were observed in 179 eyes, most common was conjunctival pallor (71.5% eyes). Posterior segment findings were observed in 19 eyes, and retinal hemorrhages was most common (36.8%). Vitamin A deficiency signs were observed in 17 eyes (8.5%). Of them, conjunctival xerosis was most common finding observed in 10 (58.9%) eyes.

Higher birth order and number of sibling was significantly associated with higher incidence of ocular manifestations ( $p<0.05$ ). However, other variables showed no significant association between other variables and ocular manifestations ( $p>0.05$ ).

### 4. Discussion

Severe Acute Malnutrition is one of the important cause of under 5 morbidity in our country, since severe ocular involvement is associated with SAM, therefore an institutional based observational study was undertaken to study the ocular manifestations in SAM and its correlation with risk factors associated with ocular manifestations.

Our study population included 100 cases of SAM. There was slight female preponderance observed with male:female ratio of 1:1.1. Majority of children belonged to 6 months to 12 months of age group (58%) whereas only 4% children belonged to age group 37 to 48 months. Majority of them had low birth weight i.e. <2.5 kg (43%). While it was within normal range (2.5 to 3 kg) in 31% children

**Table 2:** Ocular involvement in SAM

<b>Bilateral Involvement</b>	<b>Cases</b>	<b>Unilateral Involvement</b>	<b>Cases</b>	<b>Both</b>	<b>Cases</b>
Blepharitis+ conjunctivitis+ exposure keratopathy	02	Corneal opacity	01	B/L Conjunctival pallor+U/Lsub conjunctival haemorrhage+ U/L Anaemic Retinopathy	01
Blepharitis+ Conjunctivitis	01				
Blepharitis+ Conjunctival pallor+ Exposure keratopathy	03				
Blepharitis+ Conjunctival pallor+ Xerophthalmia	01				
Xerophthalmia+ Conjunctival pallor	04	Sub conjunctival haemorrhage	01	B/L Conjunctival pallor+U/L Sub conj Haemorrhage	01
Conjunctival pallor	48				
Yellowish discolouration of sclera	02				
Conjunctival pallor+ Optic atrophy	01				
Conjunctival pallor+ Papilloedema	02				
Papilloedema	01				
Conjunctival pallor+ Anaemic Retinopathy	03				
<b>Total</b>	<b>68</b>	<b>Total</b>	<b>02</b>	<b>Total</b>	<b>02</b>

**Table 3:** Distribution according to findings

<b>Findings</b>	<b>No of eyes</b>	
	Lid edema	14
	Discharge	14
	Conjunctival congestion	06
Anterior Segment	Conjunctival pallor	128
	Sub Conjunctival haemorrhage	03
	Yellowish Discolouration of sclera	04
	Exposure keratopathy	10
	Optic Atrophy	02
	Disc edema	06
Posterior segment	Venous dilatation and tortousity	02
	Retinal haemorrhages	07
	Roth spots	02
	Conjunctival Xerosis	10
	Corneal Xerosis	02
Vitamin A deficiency sign	Keratomalacia	02
	Corneal perforation	02
	Corneal opacity	01

and it was not known in 19% cases. About 73% children were fully immunized whereas 19% and 8% children were partially immunized and not immunized respectively.

Similar findings were observed by Ahmed et al,<sup>7</sup> male to female ratio was found to be evenly distributed, males (48%) and females (52%). This is because younger children are rapidly growing with high energy requirements and are prone to recurrent infections, therefore are at increased risk of SAM. About 40% were fully immunized, (50.67%) were partially and (9.39%) were not immunized at all.<sup>7</sup>

This suggest that there is better utilization of immunization service in our country as suggested by our study.

As per recommendations from World Health Assembly Resolution. Infant and young child nutrition in 2001, infants should be EBF for the first 6 months of life to achieve optimal growth, development and health. Thereafter to meet their evolving nutritional requirements, they should receive nutritionally adequate and safe complementary foods. The effect of diet, early weaning increases the risk for infections and thus increases the risk of SAM. Majority of cases(68%)

**Table 4:** Association of ocular involvement with sociodemographic and maternal variables

Variables	No. of Cases (n=100)	Ocular involvement (n=72)	P value	
Gender	Females	52	38(73.1%)	0.80
	Males	48	34(70.8%)	
Age (months)	6-12	58	43(74.13%)	0.47
	13-24	31	20(64.51%)	
	25-36	7	5(71.42%)	
	37-48	4	4(100%)	
Residence	Rural	71	50 (70.4%)	0.59
	Urban	29	22 (75.9%)	
	<2.5 kg	46	31 (67.4%)	
Birth weight	2.5-3.0kg	33	25(75.8%)	0.65
	>3.0 kg	02	01(50%)	
	Don't know	19	15(78.9%)	
Immunization	Full	73	56(76.7%)	0.22
	Partial	19	11(57.9%)	
	Not Immunized	08	5(62.5%)	
EBF	Present	32	21(65.6%)	0.33
	Absent	68	51(75%)	
Socioeconomic status	Upper	01	0 (0%)	0.13
	Upper Middle	02	0 (0%)	
	Lower Middle	20	15(75%)	
	Upper Lower	55	44(80%)	
	Lower	22	13(59%)	
Birth order	1	24	10(41.7%)	<b>0.01</b>
	2	46	33(71.7%)	
	3 or more	30	29(96.7%)	
No. of siblings	1	58	35 (60.3%)	<b>0.001</b>
	2	30	26(86.7%)	
	3 or more	12	11(91.7%)	
Maternal education	Illiterate	55	39(70.9%)	0.96
	Primary	37	27(72.97%)	
Maternal occupation	Higher	08	06(75%)	0.87
	Unemployed	62	45(72.58%)	
	Employed	38	27(71.05%)	

were not given exclusive breast feeding until six months as they were started with complementary diet too early, also due to cultural and social reasons, children are more likely to be subjected to inadequate feeding practices and low nutritive foods.

Prevalence of ocular involvement noted was 72%. Singh et al<sup>8</sup> documented 16.6% prevalence of ocular manifestations in malnourished children attending anganwadi centers. In present study, prevalence was very high compared to reference study. This could be due to the fact that our study included only children with SAM, having severe comorbidities whereas their study included total malnourished children, both acute and chronic.

Out of 72 cases with ocular involvement, bilateral involvement was observed in 68 (94.4%) cases whereas unilateral involvement was observed in 2 (2.8%) cases. Overall, conjunctival pallor was most common ocular manifestation. Blepharitis was observed in 7(10.29%) cases, and conjunctivitis in 3(4.41%) cases with bilateral involvement. These infections may be due to the secondary

immunodeficiency caused by malnutrition leading to predisposition to external infections and also bad hygiene.

Ahmed et al<sup>7</sup> also documented conjunctival palor as the most common ocular manifestation observed in (96%), this suggest that almost all children were anaemic and conjunctivitis was found in (46.67%) cases, whereas Blepharitis was not found in any patient.

Anterior segment findings were observed in 179 eyes out of 200 eyes. Of them, conjunctival pallor was the most common finding observed in 128 (71.5%) eyes. This was followed by lid edema and discharge in 14 (7.8%) eyes each. Posterior segment findings were observed in 19 eyes. Most common posterior segment finding observed in children with severe acute malnutrition was retinal hemorrhages followed by disc edema in 36.8% and 31.6% eyes respectively. Vitamin A deficiency signs were observed in 17 eyes (8.5%). Of them, conjunctival xerosis was the most common finding observed in 10 (58.9%) eyes. Apart from this, corneal xerosis, keratomalacia, and corneal perforation were documented in 2 (11.8%) eyes each. No

case presented with Bitot spots were reported.

Similar findings were noted by Ahmed et al<sup>7</sup> in which discharge (28%) and lid oedema was found in (46.67%) cases. Corneal opacity and subconjunctival haemorrhage in 1.33% cases. Retinal haemorrhages were also the most common posterior segment finding detected in (4%) cases.

Anandakumar et al<sup>9</sup> documented conjunctival xerosis in 36% cases of SAM. However, Bitot spots were seen in 24% of cases. Corneal scar was seen in one case. Night blindness was not noted in any children.<sup>9</sup> Ferdousi et al<sup>10</sup> in their study observed signs of vitamin A deficiency in 10% cases. Of them, xerosis was present in 4 cases and corneal ulcer in 1 case. No case presented with Bitot spots, this is similar with our study.<sup>10</sup> Since in our study xerophthalmia was present in 5% cases when comparing with above studies, we notice that there is a reduction in vitamin-A deficiency signs this could be attributed to better utilization of the national policy of giving vitamin-A supplementation.

While observing the risk factors associated with ocular involvement in severe acute malnutrition it, was found that among gender, age, birth weight, birth order, immunization status, exclusive breast feeding, no of siblings, residence, mother education, mother occupation and socioeconomic status, only birth order and no of siblings were significantly associated. This could be due to reason that general condition of mother also deteriorates after multiple pregnancies and also because of increase in number of children, mother is unable to give them attention properly.

However, Ahmed et al<sup>7</sup> found Dacrocystitis as the only ocular finding which was statistically significant related to immunization status. There is a lack of evidence in literature studying the risk factors associated with ocular involvement in severe acute malnutrition, only some of the studies are done that too on total malnourished children, therefore we can't compare our study with other studies. Limitation of our study being a single center hospital-based study, the results cannot be extrapolated to study the prevalence of Ocular manifestations in the general population.

## 5. Conclusion

The prevalence of ocular manifestations of severe malnutrition are noticeable and under 5 children forms an important target group and must be screened adequately for early detection of ocular findings and prevention of VAD. Also, every child should be immunized, given prophylaxis for vitamin A and promotion of EBF should be encouraged. Training should be given to health workers at the primary health care level and health centers on counseling mothers on feeding, growth monitoring, the preventable eye blinding diseases and hygiene during the vaccination sessions and early referral of children with eye signs to hospitals. Thus preventing adverse impact on childhood morbidity and mortality. Also education of couple regarding proper nutrition of mother and child should be encouraged and couples should be insisted to

have not more than two children.

## 6. Strength of the study

1. This study had better understanding of ocular profile of children with SAM.
2. This study had showed association of various risk factors with different type of ocular manifestation.

## 7. Limitations of Study

1. Although SAM is one of the leading causes of morbidity and mortality, worldwide, in childhood, Literature regarding ocular manifestations of SAM is few and research is scanty.
2. Ophthalmic examinations in severely comorbid children with SAM was inconvenient for mothers and care takers.
3. Follow up visits of patients to OPD for further assessment was not always accomplished.
4. Most cases were comorbid with high mortality.
5. As, cases were severely comorbid, unconscious and uncooperative therefore visual acuity and ocular movement assesment couldnt be studied.
6. Being a single center hospital-based study, the results cannot be extrapolated to study the prevalence of Ocular manifestations in the general population

## 8. Opportunity Laid by the Study

1. Helpful in spreading awareness regarding the disease
2. Counselling of parents regarding the risk factors associated so that preventable blindness could be minimised.

## 9. Source of Funding

None

## 10. Conflict of Interest


None.

## References

1. Haddad L, Alderman H, Appleton S, Song L, Yohannes Y. Reducing child malnutrition: How far does income growth take us. *World Bank Econ Rev.* 2003;17(1):107–31.
2. Malnutrition - World Health Organization. Last accessed on 3rd April 2021. Available from: <https://www.who.int/news-room/fact-sheets/detail/malnutrition>.
3. Child malnutrition – WHO . Last accessed on 3rd April 2021. Available from: <https://www.who.int/news-room/q-a-detail/malnutrition>.
4. UNICEF, WHO, World Bank. Joint Child Malnutrition Estimates 2018. New York: UNICEF; 2019. [cited 2020 Jul 15]. Available from: <https://data.unicef.org/resources/dataset/malnutrition-data>.
5. Gernaat HB, Dechering WH, Voorhoeve HW. Mortality in severe protein-energy malnutrition at Nchelenge, Zambia. *J Trop Pediatr.* 1998;44(4):211–7.

6. Lopez AD, Mathers CD, Ezzati M, Jamison DT, Murray CJ. Global and regional burden of disease and risk factors, 2001: systematic analysis of population health data. *Lancet*. 2006;367(9524):1747–57.
7. Ahmed UBM. Ocular manifestations of severe protein energy malnutrition in Sudanese children. 2003; Available from: <http://api.uofk.edu:8080/api/core/bitstreams/8a66c6df-c807-49ab-a238-db5593713dbf/content>.
8. Singh P, Kumar R, Das S. A clinical study of prevalence of ocular manifestations in malnourished children attending Anganwadi centers in urban slum areas. *Int J Med Res Rev*. 2017;5(11):956–61.
9. Anandakumar TS, Kumar GV, Viswanathakumar HM. Study of clinical profile of vitamin-a deficiency in malnourished children visiting a medical college hospital. *Int J Pediatr Res*. 2016;3(5):289–92.
10. Ferdousi SA, Biswas RS, Paul NK, Karim MR. Iron Status in Malnourished Children : A Cross Sectional Study. *Chattagram Maa-O-Shishu Hosp Med College J*. 2014;13(3):50–3.

### Author biography

**Divya Raichandani**, Resident  <https://orcid.org/0000-0003-0554-4907>

**Kavita Kumar**, HOD

**Aditi Dubey**, Assistant Professor

**Sheetal Morskole**, Resident

**Shreya Tyagi**, Resident

**Cite this article:** Raichandani D, Kumar K, Dubey A, Morskole S, Tyagi S. Current scenario of ocular morbidity in severe acute childhood malnutrition in central part of India. *Indian J Clin Exp Ophthalmol* 2022;8(1):130-136.