

Content available at: <https://www.ipinnovative.com/open-access-journals>

Indian Journal of Clinical and Experimental Ophthalmology

Journal homepage: www.ijceo.org

Original Research Article

Retrograde trans-synaptic axonal degeneration in post-geniculate lesions

Sujithra H¹, Rizana V Mohammed^{1,*}, Gopal S Pillai¹, Greeshma C R²¹Dept. of Ophthalmology, Amrita Institute of Medical Sciences, Edappally, Kerala, India²Dept. of Biostatistics, Amrita Institute of Medical Sciences, Edappally, Kerala, India

ARTICLE INFO

Article history:

Received 03-09-2021

Accepted 23-11-2021

Available online 31-03-2022

Keywords:

Ganglion cell complex
Optical coherence tomography
Post geniculate lesions
Retinal nerve fiber layer
Retrograde axonal degeneration

ABSTRACT

Background: The concept of retrograde axonal degeneration is well studied for visual pathway lesions upto lateral geniculate body. Since clinically evident optic nerve head changes and papillary changes are usually absent in post geniculate lesions, very few studies have been reported to look for the presence of retrograde axonal degeneration in these lesions.

Aims: To analyse RNFL and GCC thickness in patients with retrogeniculate lesions using Spectral Domain OCT and to determine any characteristic thinning pattern corresponding to the visual field defect.

Materials and Methods: Patients attending Ophthalmology OPD as diagnosed cases of unilateral retrochiasmal lesions were included in the study. Those who showed homonymous hemianopia corresponding to the retrochiasmal lesions were subjected to OCT RNFL and GCC. Spectral domain OCT was performed on all patients using ZEISS Cirrus HD-OCT Model 400.

Results: Mean age of the study population was 55.5±14.02 years. 21(70%) patients were males, 9(30%) were females. Ipsilateral eyes have superior RNFL thinning, contralateral eyes have inferior, nasal and temporal quadrants thinning. Average RNFL thickness and GCC thickness was reduced in the contralateral eyes. In ipsilateral eyes, temporal GCC was thinner compared to nasal, whereas in contralateral eyes, nasal GCC was thinner compared to temporal.

Conclusion: The pattern of RNFL and GCC thinning corresponds with pattern of visual field loss. The thinning of RNFL and GCC is in accordance to the known trajectories of the crossed and uncrossed projections arising in the nasal and temporal hemiretinae respectively. Our study substantiates that retrograde axonal degeneration occurs in post geniculate lesions also.

This is an Open Access (OA) journal, and articles are distributed under the terms of the [Creative Commons Attribution-NonCommercial-ShareAlike 4.0 License](https://creativecommons.org/licenses/by-nc-sa/4.0/), which allows others to remix, tweak, and build upon the work non-commercially, as long as appropriate credit is given and the new creations are licensed under the identical terms.

For reprints contact: reprint@ipinnovative.com

1. Introduction

Axonal degeneration is a phenomenon of central and peripheral nervous system wherein a nerve fibre will lose function after an injury. Degeneration of an axon in the direction of its terminal following direct injury is classified as anterograde degeneration, whereas retrograde degeneration proceeds towards the cell body.^{1,2}

Some investigators believe that retrograde degeneration do not occur in post geniculate lesions, since the second order neurons end at Lateral geniculate nucleus. This may be because of absence of optic nerve head changes in these lesions.³ This belief has been challenged over recent years,^{4,5} by demonstrating RNFL and GCC thinning using OCT.^{6,7}

2. Materials and Methods

Patients referred to Ophthalmology OPD as diagnosed cases of unilateral retrogeniculate lesions (it included vascular

* Corresponding author.

E-mail address: drrizanamohammed@gmail.com (R. V. Mohammed).

occlusions and mass lesions) from other departments were included in the study. Those who showed homonymous hemianopia corresponding to the retrogeniculate lesions were subjected to complete Ophthalmological examination, OCT RNFL and GCC. OCT was done using Cirrus™ HD-OCT.

Patients with high refractive errors, diabetic retinopathy, glaucoma, age related macular degeneration, multiple sclerosis and sick patients who cannot perform HFA and OCT were excluded from the study. None of the patients had clinically evident optic atrophy at the time of examination.

Quadrant wise RNFL thickness and average RNFL thickness of both eyes were recorded. Sector wise GCC thickness and average GCC thickness of both eyes were also recorded. Average nasal GCC thickness was calculated by taking average of superonasal and inferonasal sectors. Likewise average temporal GCC was calculated taking average of superotemporal and inferotemporal sectors.

A written informed consent for conduct and publication of the study was taken from all the patients included in the study as per the ethical committee guidelines. The study got approved by the Institutional Review Board (IRB-AIMS-2017-133) on 19-12-2017.

Statistical analysis was done using IBM-SPSS version 20.0 (SPSS Inc, Chicago USA). For all continuous variables, the results are given as Mean +/- SD and for categorical variables as percentage. To test the statistical significance of difference in Retinal Nerve Fiber Layer thickness and Ganglion Cell Complex thickness between ipsilateral and contralateral eyes of patients with retrogeniculate lesions, Independence sample t tests was used. To test the statistical significance of the association of thickness of RNFL and GCL with respect to the presence of retrogeniculate lesions, chi square test was done. A p value < 0.05 was considered as statistically significant.

3. Results

Out of 30, 21(70%) patients were males, 9 patients (30%) were females. Mean age of the study population was 55.5±14.02 years. 23 (76.67%) patients had vascular lesions, 7 patients (23.33%) had mass lesions. 11 patients (36.67%) had Right sided lesion with Left homonymous hemianopia and 19 patients (63.33%) had left sided lesion with Right homonymous hemianopia.

3.1. RNFL thickness analysis

Quadrant wise RNFL thickness analysis between ipsilateral and contralateral eyes showed that contralateral eyes have nasal and temporal quadrant thinning. There was statistically significant thinning of nasal quadrant in contralateral eyes.(p value-0.035). Inferior and superior RNFL quadrants did not show much difference.(Table 1). There was no statistically significant difference in average

RNFL thickness between ipsilateral and contralateral eyes. (p value 0.290).(Table 1)

3.2. GCC thickness analysis

Table 2 shows that in ipsilateral eyes, temporal GCC was thinner compared to nasal. This was found to have borderline statistical significance. (p value-0.059). Incontralateral eyes, nasal GCC was thinner compared to temporal. This was not statistically significant. (p value-0.102).

Table 3 shows that nasal GCC was thinner in contralateral eyes and temporal GCC was thinner in ipsilateral eyes. These were not statistically significant.

Sector wise GCC thickness comparison showed that GCC was lower in nasal sectors of contralateral eyes compared to ipsilateral eyes (statistically significant in inferonasal sector (p value- 0.00) and superonasal sector(p value-0.019). Also GCC was thinner in temporal sectors of ipsilateral eyes compared to contralateral eyes r (p value-0.031). (Table 4)

Average GCC thickness did not show any statistically significant difference between Ipsilateral eyes and contralateral eyes.(Table 4)

Eight patients showed GCC thinning pattern respecting the vertical meridian in GCC thickness map and deviation map, corresponding to the visual field defects. All these patients had a duration of more than 3 years between diagnosis and OCT.(Figure 1)

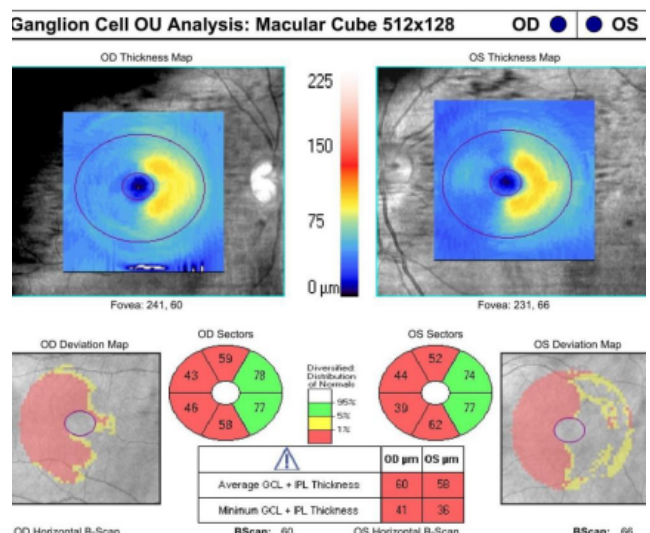


Fig. 1: Ganglion cell thinning respecting vertical meridian corresponding to visual field defect in a post geniculate lesion

4. Discussion

Arrangement of Retinal Nerve Fiber Layer (RNFL) of temporal and nasal retina at optic nerve head.^{8,9}

Table 1: Comparison of RNFL thickness in different quadrants between Ipsilateral and contralateral eyes

Quadrants	Ipsilateral eye n=30 mean±SD	Contralateral eye n=30 mean±SD	p value
Superior	96.400±20.863	97.233±21.750	0.971
Inferior	100.500±24.833	99.33±24.416	0.773
Nasal	69.500±10.006	62.967±12.582	0.035
Temporal	52.367±12.007	49.633±10.410	0.193
Average RNFL	79.700±13.204	76.9±15.114	0.290

Table 2: Comparison of average nasal GCC with average temporal GCC of ipsilateral and contralateral eyes

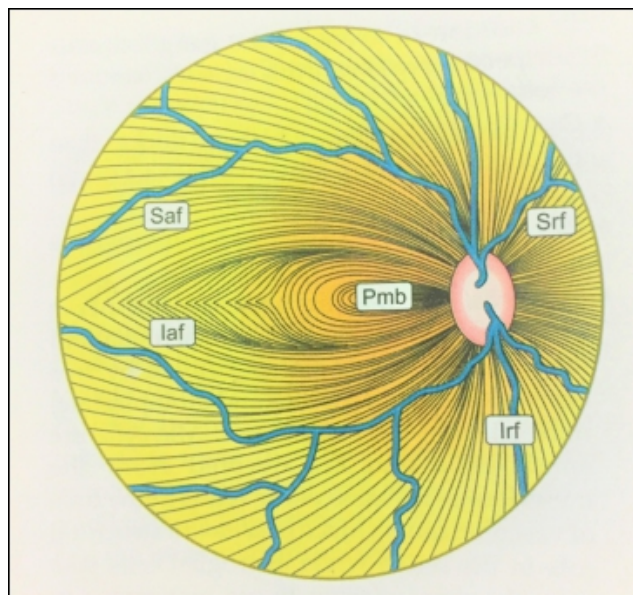
	Nasal GCC mean ± SD	Temporal GCC mean ± SD	p value
Ipsilateral eyes	71.62 ±9.789	66.83±9.443	0.059
Contralateral eyes	66.95±10.692	69.70±10.009	0.308

Table 3: Comparison of nasal and temporal GCC of ipsilateral with contralateral eyes

	Ipsilateral Eyes Mean ± SD	Contralateral Eyes Mean ± SD	p value
Nasal GCC	71.617 ±9.789	66.95±10.692	0.065
Temporal GCC	66.833 ±9.443	69.70±10.009	0.214

Table 4: Comparison of mean thickness of GCC sectors between ipsilateral and contralateral eyes

GCC sector	Ipsilateral mean±SD	Contralateral mean±SD	p value
Superior	67.40±12.517	68.8±11.469	0.734
Superonasal	74.733±12.518	67.733±14.405	0.019
Inferonasal	75.567±10.666	63.033±14.124	0.000
Inferior	68.767±11.619	68.233±11.927	0.756
Inferotemporal	65.967±11.699	71.8±13.26	0.031
Superotemporal	65.2±12.35	69.967±11.622	0.081
Average GCC thickness	69.7 ±9.300	68.367 ±9.894	0.539

**Fig. 2:** Arrangement of nerve fibres in the retina in the Right eye

1. Nasal Retinal Nerve Fibres reach optic disc as superior and inferior radiating fibres (Srf & Irf), which enters optic nerve head nasally, superonasally, superiorly, inferonasally, and inferiorly.
2. Papillomacular bundle (PMB): pass straight to temporal part of disc.
3. Temporal Retinal Nerve Fibres arch above and below the papillomacular bundle as superior / inferior arcuate fibres. (Saf & Iaf) which enters the optic disc superotemporally, superiorly, inferotemporally, and inferiorly.(Figure 2).

In this study we compared RNFL and GCC thickness between affected and unaffected fibres because of the characteristic projection of fibres to visual cortex.

4.1. Retinal nerve fiber layer thickness parameters

We found that superior and inferior RNFL thickness was not much different between ipsilateral and contralateral eyes. The circumpapillary RNFL in the superior and inferior parts of the optic nerve comprises retinal nerve fibers originating from both temporal and nasal hemiretinal areas. Hence superior and inferior RNFL cannot help in topographical localisation of visual pathway lesions.

In our study, nasal and temporal RNFL quadrants thinning was present in contralateral eyes. Nasal RNFL quadrant receives fibres only from nasal hemiretina as nasal radiating fibres.^{8,9} Temporal RNFL quadrants consists of fibres from both nasal hemiretina as papillomacular bundle and temporal hemiretinae as arcuate fibres. The major contribution is from papillomacular bundle. Hence we can expect nasal and temporal RNFL thinning in contralateral eyes which contribute to decussating nasal fibres of retrochiasm pathway. This was proved in our study also. This was in accordance with a study done by Katsutoshi Goto,¹⁰ et al. in homonymous hemianopia caused by post-geniculate lesions using spectral-domain optical coherence tomography, where they found that in contralateral eyes temporal and nasal RNFL thickness was reduced at the end of 24 months. There was statistically significant thinning only in nasal RNFL quadrant (p value-0.035) of contralateral eyes. This may be because of the fact that superior, inferior and temporal RNFL quadrants receive fibres from both nasal and temporal hemiretinae, whereas nasal RNFL consists of fibres only from nasal hemiretina.

In our study, average RNFL thickness was reduced in the contralateral eyes compared to ipsilateral eyes. (p value-0.290). This may be because of greater proportion of decussated fibres in the retrochiasm pathway.

4.2. Ganglion cell complex thickness parameters:

In our study, sector wise GCC comparison showed that GCC thickness was significantly lower in nasal sectors of contralateral eyes compared to ipsilateral eyes. (statistically significant thinning in inferonasal (p value-0.00) and superonasal (p value-0.019) sectors in contralateral eyes) also GCC was thinner in temporal sectors of ipsilateral eyes compared to contralateral eyes. (statistically significant thinning in inferotemporal sector (p value-0.031) of ipsilateral eyes).

In the ipsilateral eyes, mean temporal GCC was thinner compared to mean nasal GCC-this was found to have borderline statistical significance (p value 0.059). In the contralateral eye mean nasal GCC was thinner compared to mean temporal GCC. This was not statistically significant, but clinically significant.

Average nasal GCC was thinner in contralateral eyes compared to that of ipsilateral eyes. Average temporal GCC was thinner in ipsilateral eyes compared to contralateral eyes. Though clinically significant, these were also not statistically significant.

Average GCC thickness was reduced in contralateral eyes compared to ipsilateral eyes, but not statistically significant. This may be because of greater proportion of decussated fibres in retrochiasm pathway (53% of total fibres).

We also observed that GCC thickness map shows homonymous pattern of thinning in eight patients which

corresponds to their field defect. The normal donut pattern of GCC around fovea is lost respecting the vertical meridian in these patients.

Our findings in GCC thickness analysis was in accordance to the retrospective study on retrograde degeneration of retinal ganglion cells in ischemic occipital cortex lesions, conducted on 9 patients by Jindahra et al,¹¹ who found out that there exists a functional correlation between sector thinning of the GCL and the sensitivity loss of the in the corresponding visual field. They found a significantly stronger correlation between the VF defect and the thickness of GCL rather than that of the peripapillary RNFL. A case report of 3 patients with Posterior cerebral artery infarction, published by Yamashita et al,¹² says that GCC correlated better than RNFL with visual field defects, same as our findings. Johannes Keller et al,¹³ did a retrospective analysis of 8 patients with retro geniculate lesions where they tried to analyse the association between GCL thickness and peripapillary RNFL thickness with each quadrant of the VF, They found a strong correlation between the corresponding macular segment of the GCL and the Visual fields.

This is probably due to the fact that at the macula, the cell bodies of the neurons are more numerous and topographically organised to correspond to the visual field. But the anatomical distribution of fibres in the peripapillary RNFL is more complex, making a correlation with the visual field more difficult to establish. Also, peripapillary RNFL is not symmetric at baseline in normal subjects, the inferior quadrant is thickest, followed by the superior, nasal, and temporal. The absence of blood vessels or other structures in the perifoveal region results in better OCT image acquisition unlike peripapillary region.¹⁴

The fovea represents the physiologic division between crossed and uncrossed fibers to the visual cortex, and at baseline perifoveal thickness is symmetric between the superior, inferior, nasal, and temporal quadrants.¹⁵ For these reasons, the GCC analysis is a more straightforward way to demonstrate thinning as it is projected to the visual cortex and measured by a visual field. The GCC has been shown to be a more sensitive marker of inner retinal thinning than the RNFL in many diseases like Glaucoma and Multiple Sclerosis.^{16,17} GCC temporal to the fovea in the temporal hemiretina comprise strictly retinal ganglion cell elements that reside within the corresponding areas. The same is true with nasal GCC. Such enrichment in retinal ganglion cell components, as well as stringent retinotopical segregation renders GCC superior to the cpRNFL in the detection of homonymous hemianopic atrophy of the GCC due to retrogeniculate pathologies.¹⁸

5. Conclusion

Our study shows that there is clear cut evidence of retrograde trans synaptic degeneration in patients with

retrogeniculate lesions which manifest as GCC thinning respecting the vertical meridian with contralateral nasal RNFL thinning also. Those patients who have concurrent diseases like Glaucoma, Diabetic retinopathy, Age related macular degeneration etc, the Ganglion cell loss cannot be solely due to these diseases. The axonal loss is contributed by the posterior visual pathway lesion also. This should be kept in mind while evaluating progression of such diseases using OCT.

6. Source of Funding

None.

7. Conflict of Interest

The authors declare no conflict of interest.

References

- Coleman M. Axon degeneration mechanisms: commonality amid diversity. *Nat Rev Neurosci.* 2005;6(11):889–98.
- Saxena S, Caroni P. Mechanisms of axon degeneration: from development to disease. *Prog Neurobiol.* 2007;83(3):174–91.
- Chaddah MR, Khanna KK, Chawla GD. Optic atrophy (Review of 100 cases). *Indian J Ophthalmol.* 1971;19(4):172–6.
- Papageorgiou E, Ticini LF, Hardiess G, Schaeffel F, Wiethoelter H, Mallot HA, et al. The pupillary light reflex pathway: cytoarchitectonic probabilistic maps in hemianopic patients. *Neurology.* 2008;70(12):956–63.
- Vanburen JM. Trans-synaptic retrograde degeneration in the visual system of primates. *J Neurol Neurosurg Psychiatry.* 1963;26(5):402–9.
- Jindahra P, Hedges TR, Mendoza-Santiesteban CE, Plant GT. Optical coherence tomography of the retina: applications in neurology. *Curr Opin Neurol.* 2010;23(1):16–23.
- Park HY, Park YG, Cho AH, Park CK. Transneuronal retrograde degeneration of the retinal ganglion cells in patients with cerebral infarction. *Ophthalmology.* 2013;120(6):1292–9.
- Miller NR, Newman NJ. Walsch and Hoyt's Clinical Neuro-Ophthalmology. 6th ed. Philadelphia: Lippincott Williams and Wilkins; 2005. p. 10–82.
- Kline LB, Bajandas FJ. Neuro-Ophthalmology Review Manual. 6th ed. Thorofare: SLACK incorporated; 2008.
- Goto K, Miki A, Yamashita T, Araki S, Takizawa G, Nakagawa M, et al. Sectoral analysis of the retinal nerve fiber layer thinning and its association with visual field loss in homonymous hemianopia caused by post-geniculate lesions using spectral-domain optical coherence tomography. *Graefes Arch Clin Exp Ophthalmol.* 2016;254(4):745–56.
- Jindahra P, Petrie A, Plant G. Thinning of the Retinal Nerve Fibre Layer in Homonymous Quadrantanopia: Further Evidence for Retrograde Trans-Synaptic Degeneration in the Human Visual System. *Neuro-Ophthalmology.* 2012;36(3):79–84.
- Yamashita T, Miki A, Iguchi Y, Kimura K, Maeda F, Kiryu J. Reduced retinal ganglion cell complex thickness in patients with posterior cerebral artery infarction detected using spectral-domain optical coherence tomography. *Jpn J Ophthalmol.* 2012;56(5):502–10.
- Keller J, Sánchez-Dalmau BF, Villoslada P. Lesions in the posterior visual pathway promote trans-synaptic degeneration of retinal ganglion cells. *PLoS one.* 2014;9(5):e97444.
- Hood DC, Fortune B, Arthur SN, Xing D, Salant JA, Ritch R, et al. Blood vessel contributions to retinal nerve fiber layer thickness profiles measured with optical coherence tomography. *J Glaucoma.* 2008;17(7):519–28.
- Herro AM, Lam BL. Retrograde degeneration of retinal ganglion cells in homonymous hemianopsia. *Clin Ophthalmol.* 2015;9:1057–64.
- Balk LJ, Steenwijk MD, Tewarie P, Daams M, Killestein J, Wattjes MP, et al. Bidirectional trans-synaptic axonal degeneration in the visual pathway in multiple sclerosis. *J Neurol Neurosurg Psychiatry.* 2015;86(4):419–24.
- Kim MJ, Park KH, Yoo BW, Jeoung JW, Kim HC, Kim DM. Comparison of macular GCIPL and peripapillary RNFL deviation maps for detection of glaucomatous eye with localized RNFL defect. *Acta Ophthalmol.* 2015;93(1):e22–8.
- Salazar JJ, Ramírez AI, De Hoz R, Salobar-García E, Rojas P, Fernández-Albarral JA, et al. Anatomy of the Human Optic Nerve: Structure and Function. Ferreri FM, editor. IntechOpen; 2018.

Author biography

Sujithra H, -

Rizana V Mohammed, - <https://orcid.org/0000-0003-1266-3779>

Gopal S Pillai, -

Greeshma C R, -

Cite this article: Sujithra H, Mohammed RV, Pillai GS, Greeshma C R. Retrograde trans-synaptic axonal degeneration in post-geniculate lesions. *Indian J Clin Exp Ophthalmol* 2022;8(1):121-125.