

Content available at: <https://www.ipinnovative.com/open-access-journals>

Indian Journal of Clinical and Experimental Ophthalmology

Journal homepage: www.ijceo.org

Original Research Article

Rhinoorbital mucormycosis in COVID-19 pandemic: presentation and course of disease: An observational study

Maya Sharma^{1,*}, Seema Rajvanshi¹, Sunita Khurana¹, Rajkumar Arora²¹Dept. of Ophthalmology, Government District Hospital, Sri Ganganagar, Rajasthan, India²Dept. of Otorhinolaryngology, Government District Hospital, Sri Ganganagar, Rajasthan, India

ARTICLE INFO

Article history:

Received 16-06-2021

Accepted 06-07-2021

Available online 03-01-2022

Keywords:

COVID 19

Mucormycosis

Prevention

ABSTRACT

Purpose: During the second wave of Covid 19[SARS- Co V-2] pandemic, there is a sudden increase in number of mucormycosis infection cases in India. The present study is an attempt to understand the presentation, course and outcome of rhinoorbital mucormycosis in a group of patients who reported to Ophthalmology and Otorhinolaryngology department of our Govt. District Hospital (secondary referral centre) for enhancing measures for prevention and management.

Materials and Methods: Patients who reported to our Government district hospital with signs or symptoms suggestive of rhino orbital mucormycosis during May-June 2021 were included in the study with consent of ethical committee, patients and patient's relatives. Total 17 cases were reported and followed. Clinical examination was done for all the patients. History of the presenting complaints and underlying illness with COVID -19 was elicited. Underlying comorbid status was recorded. Patients were followed as all of them were referred to higher centre for further management as per the guidelines issued by directorate medical and health services, rajasthan, Jaipur.

Results: 13(76.4%) patients were from rural and 4 (23.5%) were from urban area. 11(64.7%) patients had RT-PCR +ve, 6 had RT-PCR _ve, 2 did not have RT-PCR report. 15(88.7%) patients had high blood sugar at presentation mean being 315.7mg%. 9 (52.9%) developed mucormycosis during their treatment for COVID in hospital. 8(47.05%) presented in OPD. 9 patients had treatment with inhalational O₂ while 8 patients did not have treatment with O₂. Death rate was high (70.5%) among our patients. Patients who survived (29.4%) had only initial symptoms and signs at presentation therefore could be managed earlier. None of our patient had vaccination for COVID.

Conclusion: Our study was done at secondary referral centre, all the previous studies were done at tertiary referral centres; therefore it shows the course of disease mainly among rural population ; most of them presented very late and had poor outcomes. It shows the need of more awareness about COVID and mucormycosis among people especially in rural areas. High blood sugar either due to treatment with steroids or pre existing is a major risk factor for Rhino orbital mucormycosis. Being RT- PCR negative for COVID 19 does not rule out the associated possible complication of Rhino orbital mucormycosis. Early diagnosis and management remains the key factor for managing Rhino orbital mucormycosis.

This is an Open Access (OA) journal, and articles are distributed under the terms of the [Creative Commons Attribution-NonCommercial-ShareAlike 4.0 License](https://creativecommons.org/licenses/by-nc-sa/4.0/), which allows others to remix, tweak, and build upon the work non-commercially, as long as appropriate credit is given and the new creations are licensed under the identical terms.

For reprints contact: reprint@ipinnovative.com

1. Introduction

Second wave of COVID-19 pandemic in India has affected a large number of people so the associated bacterial and fungal infection cases are also high.¹ Cases with symptoms and signs suggestive of rhinoorbital mucormycosis suddenly

* Corresponding author.

E-mail address: drmaya49@gmail.com (M. Sharma).

increased that was previously seldomly reported. Sen et al. studied 6 patients with COVID-19 who developed rhino-orbital mucormycosis.² Recently Sarcar et al. reported 10 cases of clinically diagnosed orbital mucormycosis with concurrent COVID-19 illness.³

The term 'Mucormycosis' denote the acute or subacute rapidly progressing infection caused by the angioinvasive fungi in the order of 'Mucorales'.^{4,5} The ubiquitous fungi often thrive on decaying plant debris and soil. The most common genera causing human infection include *Rhizopus*, *Lichtheimia*, *Apophysomyces*, *Mucor* and *Rhizomucor*. The most common clinical presentation is Rhino-orbital cerebral mucormycosis. Rhino-orbital cerebral mucormycosis almost always occurs in immunocompromised individuals, including uncontrolled diabetes mellitus with acidosis or keto acidosis, steroid therapy, organ transplant recipients, chemotherapy, hematologic dyscrasias, retroviral disease and malnourishment.⁶

The rapidly growing saprophytic fungi release a large number of spores in the environment. These sporangiospores are commonly inhaled by the host, in hosts with normal immune status, the ciliary system directs the spores towards the pharynx, thereby eliminating them via the GI system. The spores might also get colonized in the oral mucosa, nose, throat and paranasal sinuses. Mucorales do not cause disease in host with normal immune system where phagocytosis could effectively contain the invasion and infection. When phagocytosis is impaired due to immune deficiency, the germination of spores into hyphae with resultant angioinvasion is initiated. The initial site of infection in Rhino-orbital cerebral mucormycosis is the nasal turbinates. An acute episode of sinusitis progresses into pan sinus involvement within a few days with contiguous spread to orbit, palate and brain resulting in severe tissue ischemia and necrosis due to the angioinvasive nature of the fungi. This mechanism is facilitated by high amount of Iron and Glucose in serum.^{7–10}

The presenting symptoms of rhino orbital cerebral mucormycosis include headache, facial pain, eye pain, facial numbness, diplopia with varying degrees of ophthalmoplegia, ptosis, proptosis, vision loss with and without papilloedema, nasal discharge, epistaxis and loosening of teeth. Black discoloration of skin and mucosa along with ulceration and discharge from nose and palatal mucosa are characteristic of mucormycosis.¹¹ CT Scan can demonstrate the nature and extent of soft tissue abnormalities in the sinuses, orbits and brain. Mucosal thickening of sinuses along with opacification is often noted. MRI is more helpful over the CT in clearly delineating vascular invasion, intracranial spread and also in the assessment of early perineural spread. A T₂ weighted MRI with fat saturation sequences or short T1 inversion recovery is ideal. Definite diagnosis is arrived at by tissue biopsy.⁶

Rhino orbital mucormycosis is an medical and surgical emergency. Amphotericin B has become the gold standard for the systemic treatment. Liposomal amphotericin B is the first choice of treatment as it crosses the blood brain barrier more effectively. Surgical debridement of local necrotic tissue (paranasal sinuses and orbital exentration) are done to reduce fungal load.⁶

As the patients reported in our study were mostly from rural area, the awareness about the disease and data availability was limited. Therefore our study largely represents the presentation and course of disease among rural population.

2. Materials and Methods

We recruited a cluster of 17 patients with signs or symptoms suggestive of rhino-orbital mucormycosis who reported to Ophthalmology and Otorhinolaryngology departments of our Government district hospital after obtaining consent from patients. Their demographic profile was noted. Clinical examination was done. SpO₂, blood sugar, treatment history with O₂ and steroids was recorded. CT-PNS, orbit and head were done. All the patients were referred to tertiary level centres. Patients were followed for their management and outcome. At tertiary level MRI of paranasal sinuses, orbits and brain (plain and contrast) were obtained. Endoscopic tissue biopsy was done for final diagnosis. Endoscopic sinus debridement or orbital exentration were done as per the requirement. Intravenous liposomal amphotericin B was used for the medical management.

3. Results

Case no. 1,2,3,4,5,10,11,12 and 17 total 9 developed symptoms during their treatment for COVID in hospital. All these patients were on intravenous steroids and O₂. 7 out of these 9 patients had spo₂ below 90%. All these 7 patients died within 7 days from the onset of symptoms of mucormycosis. One patient out of these 9 admitted patients had spo₂ 97%, had orbital exentration done and was on Amphotericin B but expired during 3rd week of treatment. Remaining one patient had orbital exentration and was on Amphotericin B till the last follow up.

Table 1:

Case no.	Ag/sex	R/U	COVID RT-PCR	COVID Related symptoms, Spo2	Treatment with inhalational o2	Blood sugar (mg%)	Orbital symptoms and signs	Radiologic findings	Treatment received for Mucormycosis	Outcome
1	45/M	R	+ve	ICU, Spo2 75%	+	240	RE/ orbital cellulitis	MRI –Rt. Orbital cellulitis and Optic Neuritis Cavernous sinus thrombosis	Amph. B for 2 days	Death
2	80/F	U	+ve	ICU, Spo2 70%	+	320	RE/Orbital cellulitis	MRI-Rt. Orbital cellulitis and Optic neuritis	Amph. B for 2 days	Death
3	75/F	R	-ve	Fever, dyspnoea Spo2 80%	+	285	RE/ Orbital cellulitis	NA	Amph.B for 3 days	Death
4	45/F	U	+ve	Fever, dyspnoea Spo2 85%	+	280	RE/Orbital cellulitis	MRI –Rt Orbital cellulitis	RE /Orb.Ext. followed by Amph. B for 1 day	Death
5	70/ M	R	+	Fever, Dyspnoea Spo2 85%	+	310	RE/ Orbital cellulitis	MRI-Rt Orbital cellulitis with Optic neuritis	RE/ orb. Ext.	Death
6	45/M	R	-ve	Fever Spo2 95%	–	500	RE/ Orbital cellulitis PL _ve	MRI – Rt. Orbital Cellulitis	Received Amphotericin B for 2 days	Death
7	65/M	R	-ve	Fever Spo2 95%	–	500	LE/ Orbital cellulitis	MRI- Lt. Orbital cellulitis, Cavernous sinus Thrombosis	Nil	Death
8	54/F	R	_ve	Fever, breathlessness, anosmia	–	500	LE/ Orbital Cellulitis	MRI-Lt. Orbital cellulitis	On Amph. B	Improved
9	70/F	R	_ve	Fever, dyspnea, Spo2 75%	-	380	LE/ C/O pain at presentation, paraesthesia over Lt. heek progressed to Lt. 6th nerve palsy	MRI-+ve	Nil	Death

Continued on next page

Table 1 continued

10	70/F	R	+ve	Fever, Spo2 90%	+	340	LE/Pain, paresth- esia Lt. Cheek	CT PNS- Pansinusitis	Sinus debridement followed by Amph. B	Impro- ved
11	60/M	U	+ve	Fever	+	199	LE/Proptosis and chemosis	CT PNS- Pansinusitis, MRI- +ve	LE/ Orb. Ext. followed by Amph. B	Death
12	50/M	R	+ve	Admitted in ICU Spo2 54%	+	360	LE/ Eyelid swelling Progressed to orbital cellulitis	NA	Received Amphotericin B for 2 days	Death
13	50/M	R	NA, ___- ve after death	NIL	–	240	RE/ Orbital cellulitis	MRI - +ve	Nil	Death
14	61/F	R	+ve	Fever	+	70	RE/ Sudden loss of vision, PL_ve	CT PNS- Maxillary sinusitis	Oral Fluconazole	Unchanged
15	65/F	R	_ve	Fever CRP- 53 Spo2 95%	+	400	B/L Orbital cellulitis with facial swelling and eschar over lt. cheek	MRI- +ve	Amph. B For 1 day	Death
16	34/M	U	NA	Fever, vomiting	–	123	B/L conjunctival congestion	CT PNS –Sphenoidal sinusitis	On Amph. B	Improved
17	62/M	R	+ve	Fever	+	320	LE/ Orbital cellulitis	MRI- Rhino orbital mucormycosis	LE/ Orb. Ext. followed by Amph. B	Improved

Ag-Age, M-Male, F-Female, R- Rural, U- urban, MRI- +ve=MRI- +ve for Rhinorbital mucormycosis, RE-Righteye, LE-Left eye, Orb. Ext.-Orbital Exentration, Amph.B- Liposomal Amphotericin B

8 patients presented in OPD, they did not have history of treatment with O₂. 6 out of these 8 patients were on oral steroids. 5 out of these 8 OPD patients had orbital cellulitis at presentation. 4 of these 5 died within 1 week while on treatment for mucormycosis. One out of these 8 patients had acute presentation with right orbital cellulitis and nasal bleeding, blood sugar was 240mg/dl and spo₂ was 95%. MRI was positive for rhinoorbital mucormycosis. He had no history of any type of illness or treatment in the past. He died before having any treatment for mucormycosis. Duration of his onset of symptoms and death was only 4 days. RT-PCR done after death was negative. Another one patient was 34 yr male with vomiting, diarrhea and bilateral conjunctival congestion at presentation. CT-PNS showed sphenoidal sinusitis. His blood sugar level was 123 mg/dl and spo₂ was 97%. He was immediately referred; was diagnosed to have rhino orbital mucormycosis and was managed accordingly with Intravenous Amphotericin B. This patient survived and improved with timely intervention.

4. Observations

Total 17 patients were enrolled in our study. 13 (76.4%) patients were from rural area and remaining 4 (23.5%) were from urban area.

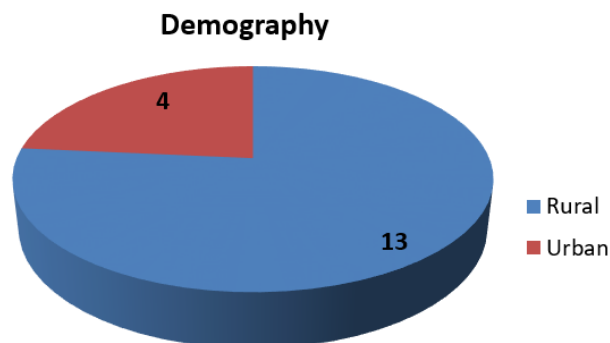


Fig. 1:

Mean age of presentation was 58.88 years

9 /17 (52.9%) of patients were already admitted in COVID wards and developed mucormycosis during treatment of COVID. Other 8/17 (47.05%) cases, reported in OPD and never had treatment with inhalational O₂. Therefore role of inhalational O₂ in causing rhinoorbital mucormycosis remains doubtful in our study.

6 patients had RT-PCR report negative but developed symptoms and signs of Rhino orbital mucormycosis in due course. 2 patients did not get RT- PCR test done. It shows that patients can develop associated complications of COVID 19 even if they are reported negative in RT- PCR.

12 enrolled patients (12/17 i.e 70.5%) died and 5 patients survived till the last follow up in our study. This

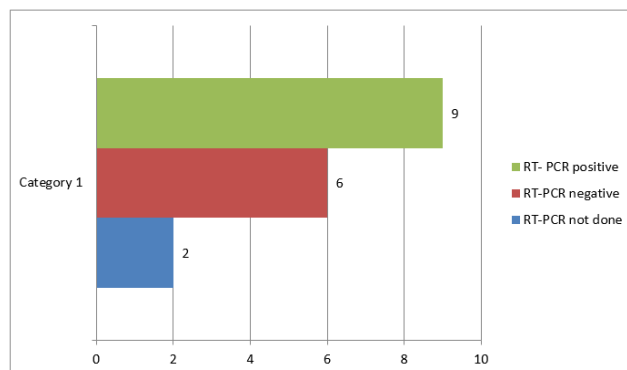


Fig. 2:

denotes a high death rate in mucormycosis patients. Out of 12 patients who died 10 (90.9%) had orbital cellulitis at presentation. Out of these 10 cases 2 cases presented in OPD; were immediately referred to higher centre but died before receiving any treatment for mucormycosis. 2 cases out of these 10 had orbital exenteration followed by liposomal amphotericin B, 5 had received amphotericin B for 2-3 days and remaining 1 died at home within 7 days without receiving any treatment. This shows poor prognosis of patients once orbital cellulitis sets in.

5. Discussion

15 (82.3%) cases had high blood sugar at presentation. Our finding correlates with the fact that mucormycosis infection is facilitated by high blood sugar.⁷⁻⁹

Our finding of high mortality among orbital cellulitis patients is similar to that of study done by Asim V et al.¹² Who described that fungal orbital cellulitis has high mortality despite aggressive treatment.

4 patients who were alive and had improved after referral to higher centre had only initial symptoms and signs suggestive of Rhino orbital mucormycosis at presentation; were immediately referred and were treated accordingly. This underlies the importance of early diagnosis and treatment.

The early flag sign and symptoms reported in our study were:

1. Paresthesia over cheek and ipsilateral eye pain
2. Bilateral conjunctival congestion
3. Eye lid swelling
4. Headache

Any patient with these symptoms must have CT PNS done ; if CT PNS shows mucosal thickening in any of the paranasal sinuses immediate further management must be done.

6. Conclusion

Rhinoorbital mucormycosis showed acute onset and rapid progression in all the patients. High index of suspicion

is necessary for early diagnosis and treatment to avoid high mortality and morbidity as it showed acute onset and rapid progression even in patients with mild symptoms of COVID. Prevention of COVID infection especially in patients with Diabetes remains the only way to avoid associated mortality, morbidity, social and economic upheavals. Wide social awareness about the preventive measures, early symptoms and available management is of paramount importance especially in rural and remote areas of India.

7. Source of Funding

None.

8. Conflict of Interest

The authors declare no conflict of interest.

9. Acknowledgement

We would like to acknowledge support of Dr. Anju Kochar, SP Medical College and Hospital, Bikaner for providing follow up details of our patients.

References

1. Mehta S, Pandey A. Rhino orbital mucormycosis associated with COVID 19. *Cureus*. 2020;12(9):e10726.
2. Sen M, Lahane S, Lahane TP, Parekh R, Honavar SG. Mucor in a Viral Land: A Tale of Two Pathogens. *Indian J Ophthalmol*. 2021;69(2):244–52.
3. Sarkar S, Gokhale T, Choudhury SS, Deb AK. COVID-19 and orbital mucormycosis. *Indian J Ophthalmol*. 2021;69(4):1002–4.
4. Harrill WC, Stewart MG, Lee AG. Chronic rhinocerebral mucormycosis. *Laryngoscope*. 1996;106(10):1292–7.
5. Xia ZK, Wang WL, Yang RY. Slowly progressive cutaneous, rhinofacial and pulmonary mucormycosis caused by *Mucor irregularis* in an immunocompetent woman. *Clin Infect Dis*. 2013;56(7):993–5.
6. Kumar AK, Gupta V. Rhino orbital cerebral Mucormycosis; 2021. Available from: <https://www.ncbi.nlm.nih.gov/books/NBK557429/>.
7. Ibrahim AS, Kontoyiannis DP. Update on mucormycosis pathogenesis. *Curr Opin Infect Dis*. 2013;26(6):508–15.
8. Mallis A, Mastronikolis SN, Naxakis SS, Papadas AT. Rhinocerebral mucormycosis: an update. *Eur Rev Med Pharmacol Sci*. 2010;14(11):987–92.
9. Gamaletsou MN, Sipas NV, Roilides E, Walsh TJ. Rhinoorbital cerebral mucormycosis. *Curr Infect Dis Rep*. 2012;14:423–34.
10. Maurya RP. Post COVID-19 Mucormycosis: What is role of iron and iron chelating agents? *Indian J Clin Exper Ophthalmol*. 2020;6(4):478–9.
11. Kulkarni R, K UMU, Meshram C, Kochar D, Modi M, Vishnu VY. Epidemic of mucormycosis in COVID 19 pandemic. *Ann Indian Acad Neurol*. 2021;doi:10.4103/aian.AIAN_421_21.
12. Farooq AV, Patel RM, Lin AY, Setabutr P, Sartori J, Aakalu VK. Fungal Orbital Cellulitis: Presenting Features, Management and Outcomes at a Referral Center. *Orbit*. 2015;34(3):152–9. doi:10.3109/01676830.2015.1014512.

Author biography

Maya Sharma, -  <https://orcid.org/0000-0002-0874-6179>

Seema Rajvanshi, -

Sunita Khurana, -

Rajkumar Arora, -

Cite this article: Sharma M, Rajvanshi S, Khurana S, Arora R. Rhinoorbital mucormycosis in COVID-19 pandemic: presentation and course of disease: An observational study. *Indian J Clin Exp Ophthalmol* 2021;7(4):624–629.