

Content available at: <https://www.ipinnovative.com/open-access-journals>

Indian Journal of Clinical and Experimental Ophthalmology

Journal homepage: www.ijceo.org

Original Research Article

Role of anterior segment optical coherence tomography in the evaluation of microbial keratitis

Isha Chaturvedi^{1,*}, Kamaljeet Singh², Jagriti Rana², Kshama Dwivedi², Reena Sachan²¹Dept. of Ophthalmology, MLN Medical College, (affiliated to KGMU), Prayagraj, Uttar Pradesh, India²Dept of Ophthalmology, MLN Medical College (affiliated to KGMU), Prayagraj, Uttar Pradesh, India

ARTICLE INFO

Article history:

Received 08-09-2019

Accepted 21-04-2021

Available online 30-09-2021

Keywords:

Anterior segment OCT

Corneal thickness (CT)

Infiltrate thickness (IT)

ABSTRACT

Background: Anterior segment optical coherence tomography (AS-OCT) is a newer technology that provides two-dimensional images of corneal infiltration. This study was undertaken to assess whether AS-OCT can aid objective evaluation and response to treatment in resolving microbial keratitis.

Materials and Methods: This prospective study was performed on 17 patients of who underwent slit lamp and AS-OCT examination at presentation and follow up on days 3, 7, 14, 28 and 6 weeks. A standardized scanning protocol was used to measure the corneal thickness (CT) and infiltrate thickness (IT) using the caliper tool of a commercially available AS-OCT device.

Results: The mean CT in the infiltrated area and mean IT, both were thickest at presentation (710.88 μm and 288.76 μm respectively). The mean CT decreased to 665.12 μm , 650.24 μm , 584.35 μm , 549 μm , 507.47 μm on days 3, 7, 14, 28 and 6 weeks respectively. Similarly, the mean IT decreased to 287.24 μm , 244.41 μm , 197 μm , 174.59 μm and 154.82 μm . Paired t- test was used to calculate the statistical change in CT and IT, which was significant ($p < 0.0001$) at 6 weeks, at the rate of 0.67% and 1.01% per day.

Conclusion: AS-OCT can show morphological characteristics of microbial keratitis and give quantitative assessment at every follow up.

This is an Open Access (OA) journal, and articles are distributed under the terms of the [Creative Commons Attribution-NonCommercial-ShareAlike 4.0 License](https://creativecommons.org/licenses/by-nc-sa/4.0/), which allows others to remix, tweak, and build upon the work non-commercially, as long as appropriate credit is given and the new creations are licensed under the identical terms.

For reprints contact: reprint@ipinnovative.com

1. Introduction

Microbial keratitis, as seen on slit lamp shows features such as infiltrates, which may be in the form of punctate epithelial keratitis, subepithelial infiltrates and stromal infiltrates. Also associated are ulceration, corneal edema, Descemet's folds and Descemetocoele.^{1,2}

Anterior segment optical coherence tomography (AS-OCT) is a relatively new technology that may be useful for monitoring corneal infections. Previous studies have demonstrated many qualitative changes occurring in the corneal morphology in cases of microbial keratitis,³ as well as quantitative analysis of these changes.⁴⁻⁷ But

so far, no study has analyzed both qualitative and quantitative parameters of different types of microbial keratitis. Moreover, AS-OCT has limited literature to elucidate the nature of such abnormalities with only one such study done in India.³

Hence, this study was undertaken to observe and quantify changes seen on AS-OCT in patients of microbial keratitis on treatment, and to correlate them with the slit lamp findings.

2. Materials and Methods

The study was carried out at the Department of Ophthalmology, MLN Medical College, Allahabad after taking permission from the ethical committee of M.L.N.

* Corresponding author.

E-mail address: ishachats.90@gmail.com (I. Chaturvedi).

Medical College, Allahabad. As per hospital protocol, written informed consent was obtained from all patients.

This study was conducted between October 2016 and November 2017. Patients with clinically diagnosed microbial keratitis seeking treatment were recruited. Children below 12 years and recruited patients lost to follow up were excluded from the study. Finally, 17 patients were analyzed.

A complete ophthalmic history was taken and slit lamp examination including examination of the conjunctiva, tear film, cornea, anterior chamber, iris, lens and anterior vitreous was done. Anterior segment imaging was carried out by a commercially available OCT device, the Cirrus HD-OCT (Model 500) by Carl Zeiss Meditec. Inc. (Dublin, CA). AS-OCT and slit-lamp examination were carried out on presentation (day 0) and, subsequently on days 3, 7, 14, 28 and 6 weeks of treatment. All patients underwent treatment based on clinical findings.

A standardized scanning protocol was used. At all visits, high resolution AS-OCT scans were carried out through the same area of corneal infiltration with the scanning beam running through the center of the infiltration. Corneal infiltration on the AS-OCT images was defined as the hyper-reflective area that corresponded to the clinical corneal infiltration.

CT and IT were measured with caliper tools of the OCT software. CT was measured in the center of the infiltration with one caliper arm on the most anterior hyper-reflective corneal surface and the second arm on the hyper-reflective endothelium. IT was also measured in the center of the infiltration, with one caliper arm on the most anterior hyper-reflective corneal surface and the second arm on the posterior border of the hyper-reflective area. If the posterior hyper-reflective corneal surface was not visualized, then the CT was measured in an area adjacent to the infiltration. The posterior-most surface of the hyperreflective infiltration was taken as the posterior limit used to measure IT.

3. Results

17 patients with a clinical diagnosis of microbial keratitis were recruited in our study. The patient characteristics are summarized in Table 1. Of the 17 patients included in the study, 11 patients were females and 6 were males. The age of the patients ranged from 25-60 years with an average of 47.5 years. Maximum patients belonged to the age group 41-50 years. The major risk factors identified in the study were trauma with vegetative matter (53%) and unknown foreign body (12%). No risk factor was identified in 35% of the cases. After a follow up of 6 weeks, 65% of the ulcers had healed completely whereas 35% of the ulcers had not.

3.1. Quantitative analysis

The corneal thickness (CT) on presentation ranged from 444-954 μm with a mean of 710.88 μm . Infiltrate thickness (IT) ranged from 112-443 μm with a mean of 288.76 μm . The overall CT in the infiltrated area on day 0 had a mean value of 710.88 μm . On days 3, 7, 14, 28 and 6 weeks mean CT had decreased to 665.12 μm , 650.24 μm , 584.35 μm , 549 μm , 507.47 μm respectively. IT on presentation had a mean value of 288.76 μm . On days 3, 7, 14, 28 and 6 weeks mean IT was 287.24 μm , 244.41 μm , 197 μm , 174.59 μm and 154.82 μm respectively. Serial AS-OCT imaging and change in CT and IT of a representative case, on treatment, are illustrated in Figure 1. Both parameters decreased as the corneal edema and inflammation subsided clinically.

CT showed a statistically significant decrease in the early (day 0-7), middle (day 7-14), and late phase (day 14-6 weeks) of treatment with daily change of 3.65% ($p=0.023$), 1.4% ($p=0.0319$) and 0.47% ($p<0.0001$) respectively. IT decreased at a daily rate of 2.24% ($p=0.0267$) in the middle phase and 0.38% ($p<0.0001$) in the late phase. The overall decrease in CT and IT over the course of treatment was found to be statistically significant with an average percentage reduction at 0.67% per day ($p<0.0001$) and 1.01% per day ($p<0.0001$). Graphical representation of these changes is shown in Figure 2.

3.2. Qualitative analysis

Corneal infiltration appeared hyperreflective as seen in Figure 1. Normal cornea was visualized as green colored. With increasing infiltration, the color changes from green to yellow, orange and red, with maximum hyperreflectivity denoted by red and normal reflectivity by green. Hyporeflexivity is denoted by black signals.

Besides this, unique morphological AS-OCT patterns were seen in the corneal stroma such as cystic spaces and microcystic edema. In the epithelium, a well-defined defect could be seen. Endothelial features included keratic precipitates and retrocorneal inflammatory plaque.

Stromal features are seen in Figure 3a to e. Both stromal infiltration and scarring appear hyperreflective. Stromal cystic spaces are hyporeflexive cavity like areas in the stroma (Figure 2 a). A differentiating feature between infiltration (Figure 3 b) and scarring (Figure 3 e) is that infiltration has ill-defined borders compared to scarring which shows more clearly defined borders and an intact epithelium above it. Stromal edema appears as diffuse areas of decreased reflectivity (Figure 3 c). Microcystic edema was a unique feature seen on the AS-OCT in viral keratitis. It was localized to the epithelium and/or anterior stroma (Figure 3 d).

Figure 3f shows an ulcer with sloping edges. Hyperelective area of infiltrate is seen in the base of the ulcer. Some degree of re-epithelization of the defect can

also be seen.

Endothelial features are shown in Figures 4 and 5. Figure 4 shows an inflammatory plaque attached to the corneal endothelium. Figure 5 shows the presence of a hyperreflective aggregation of inflammatory cells which are clinically seen as keratic precipitates. The latter were seen in case of disciform keratitis whereas endothelial plaque was seen in fungal keratitis.

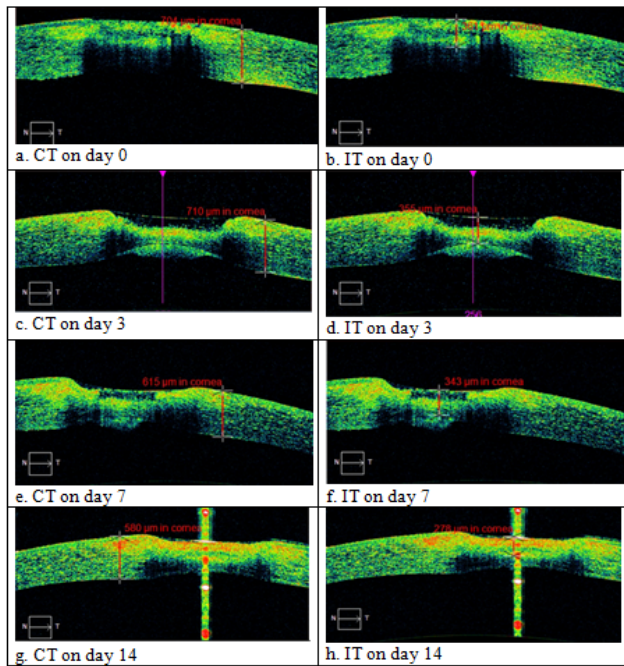


Fig. 1: A representative case showing progressive decrease in CT and IT in resolving microbial keratitis

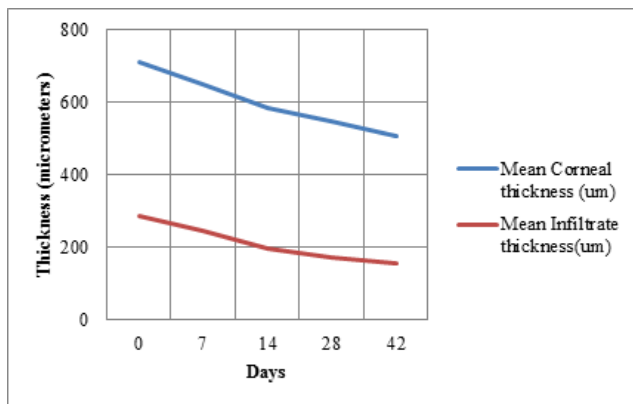


Fig. 2: Graphical change of CT(blue line) and IT(red line) over 6 weeks

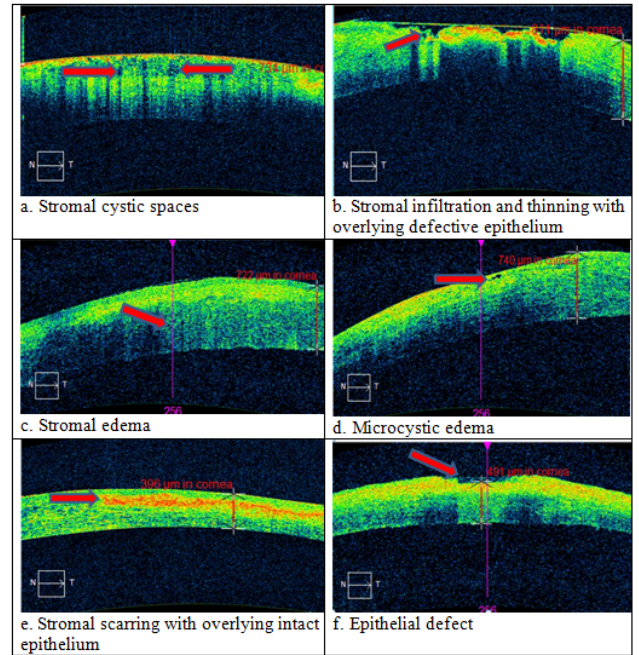


Fig. 3: Unique morphological changes occurring in the corneal microstructure in resolving microbial keratitis

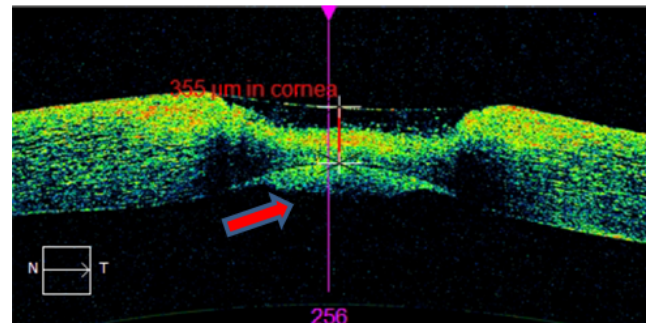


Fig. 4: Endothelial inflammatory plaque

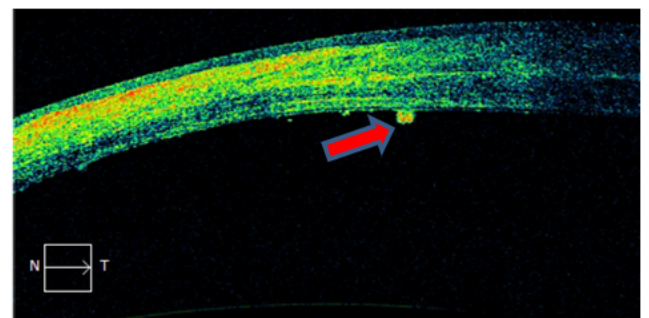


Fig. 5: Keratic precipitate seen sticking to posterior endothelial surface

Table 1: Patient characteristics

Patients:	17	
Sex:		
Male	6 (35%)	
Female	11 (65%)	
Age(years):		
Mean	47.47 ± 2.61	
Range	25-60	
Eyes:	17	
Laterality		
Left	5 (29%)	
Right	12 (71%)	
Both	0	
Ocular risk factor:		
Trauma with vegetative matter	9 (53%)	
Foreign body of unknown nature	2 (12%)	
None	6 (35%)	
Mean blood glucose (mg %):		
Fasting	104.24 ± 2.66	
Post Prandial	128.65 ± 1.83	
Healing at day 14:		
Complete	11	
Progressive	6	
OCT measurements on presentation: All cases-	Mean ± Standard Deviation	Range
Corneal thickness(μm)	710.88 ± 31.48	444-954
Infiltrate thickness(μm)	288.76 ± 26.79	112-443
Fungal keratitis		
Corneal thickness(μm)	732.92 ± 33.98	444-954
Infiltrate thickness(μm)	290.23 ± 30.84	112-443
Viral keratitis		
Corneal thickness(μm)	639.25 ± 72.18	450-763
Infiltrate thickness(μm)	284 ± 62.46	124-446

4. Discussion

Conventionally the slit lamp has remained the gold standard for diagnosis and management of microbial keratitis. However, the limitation of slit lamp is its inability to assess the depth of infiltration due to associated stromal edema. AS-OCT, on the other hand, allows a more accurate assessment of the corneal parameters such as measurement of depth of infiltration, stromal thinning in areas of ulceration and different morphological patterns.

Using AS-OCT, we have attempted to quantify the temporal change in corneal and infiltrate thickness. We also demonstrated some unique morphological patterns of microbial keratitis which may help in the etiological diagnosis as well as assessing the prognosis of the case.

Amongst microbial keratitis, the incidence of fungal keratitis in our country is reported to be as high as 63 percent.¹ In our study of 17 patients of microbial keratitis, 13 patients showed clinical features of fungal keratitis, of which nine had a history of trauma with vegetative matter. This is consistent with the fact that most of the patients in this part of the country belong to rural areas. Four patients were clinically diagnosed as cases of viral keratitis.

4.1. Quantitative assessment of corneal parameters by AS-OCT

We performed serial scans of the cornea and measured the CT and IT at every follow up.

Konstantopoulos et al⁵ recorded a maximum CT of 1490 μm and IT of 840 μm . In an earlier case series⁴ on microbial keratitis by the same author, the maximum CT recorded was 1560 μm and maximum IT was 590 μm . In the same study, there was a single case of combined bacterial and fungal infection where the CT was not recordable and the maximum infiltrate recorded was 3640 μm . Sometimes, measurements of CT and IT in cases of fungal or combined infections are difficult due to presence of thick infiltrate which does not allow proper demarcation of endothelium.

The only quantitative study on fungal keratitis by Martone et al⁶ showed a decrease in central corneal thickness from 584 μm to 532 μm in a single case of *Alternaria* keratitis. In our study, within three days of initiation of treatment in 13 cases of fungal keratitis, CT had decreased in 8 cases and IT had decreased in 11 cases. The overall daily reduction in CT and IT of fungal keratitis over a course of 6 weeks was 0.67% ($p < 0.0001$) and

1.09% ($p < 0.0001$) respectively.

In the four cases of viral keratitis, CT on day 3 had decreased in two cases (740 μm to 627 μm and 450 μm to 396 μm) whereas IT showed a decrease (426 μm to 337 μm) in only one case. This reflects the more chronic course of viral keratitis. Only the daily reduction in IT over 6 weeks was statistically significant. Hixson et al⁸ demonstrated a decrease in CT over a period of 25 and 33 days, in two cases of disciform keratitis with resolution of corneal edema on AS-OCT as well as slit lamp.

In a similar study by Kobayashi et al.,⁹ they demonstrated high reflectivity in the endothelium and deep stromal layers in 10 of 13 cases which decreased throughout the course of antiviral treatment. They, however, did not perform a quantitative analysis.

Konstantopoulos et al⁵ demonstrated an early phase reduction in IT and CT and a late phase reduction in IT in resolving bacterial keratitis. However, they exclusively analyzed resolving bacterial keratitis.

Our rate of reduction in CT was maximum in the late phase whereas IT decreased more rapidly in the middle and late phase. The likely mechanism for reduction in CT could be due to reduction of corneal edema; whereas resolution of inflammatory cells could lead to a reduction in IT. The late phase reduction in CT can be attributed to the fact that 13 out of 17 cases were fungal in nature and antifungal drugs have longer onset of action.

4.2. Qualitative assessment of corneal parameters by AS-OCT

Qualitative assessment of the infiltration is also possible, because the intensity of hyperreflectivity corresponds to the density of the infiltration on slit-lamp examination.⁴

In AS-OCT, corneal infiltrates and scar both appear hyperreflective. This was in accordance with previous studies. Soliman et al,⁷ have distinguished infiltrate and scar in that, infiltration has ill-defined borders with overlying defective epithelium. Scarring, on the other hand, has well defined borders with clear well delineated epithelium above. With the resolution of keratitis, the infiltrate is replaced by scar tissue. It was noted that infiltration was associated with increased CT whereas scarring led to a decrease in CT. Konstantopoulos also reported that in later stages of the disease, when scar tissue develops, the affected cornea may become thinner than adjacent healthy tissue.⁴ A similar observation was reported by Meredith et al.⁹ in a study on contact lens related corneal infiltration.

AS-OCT can detect changes in corneal microarchitecture occurring during inflammation. Stromal cystic spaces were seen in cases of fungal keratitis and usually limited to anterior stroma (Figure 3 a). These are suggestive of ongoing stromal necrosis. Soliman et al⁷ demonstrated the presence of localized small stromal cystic spaces and full thickness large stromal cystic spaces (necrotic stroma) as

unique patterns for fungal keratitis. Thinning may occur in the substance of the stroma with ongoing necrosis. This may be associated with an overlying defective epithelium as seen in Figure 3b. Stromal thinning was observed by both Soliman et al⁷ and Naik et al³ in cases of bacterial and fungal keratitis.

Stromal edema is seen as diffuse hyporeflective spaces in the stroma, loss of convexity of corneal endothelium, an increase in corneal thickness or in severe, cases, ruffles or folds in Descemet's membrane (Figure 3c). Stromal edema was seen by Soliman et al⁸ in both fungal and bacterial keratitis and by Naik et al⁷ in bacterial, fungal and viral keratitis. Edema may also be localized in the form of microcystic edema, not seen clinically (Figure 3 d). This type of microcystic edema was also found by Hixson et al⁸ in monitoring resolution of disciform keratitis.

Stromal scarring is seen as hyperreflective areas with sharp margins and an intact epithelium on top (Figure 3e), in contrast to infiltration. Stromal scarring was also seen by Soliman et al,⁷ Konstantopoulos et al⁴ and Naik et al.³

Our findings correlate with those of slit lamp which showed resolution of congestion, corneal edema and subsequent corneal scarring. At the end of the follow up period, 12 of the 17 cases were healed. Thus, AS-OCT can be a useful adjunct to slit lamp examination in diagnosing the exact histological/pathological stage of corneal ulceration.

Figure 3 f shows a defect in the epithelium and anterior stroma, clinically recognized as an ulcer. The floor of the ulcer shows active infiltration (hyperreflective) and there is ongoing epithelization on top. Such features cannot be demonstrated by slit lamp and this highlights the adjunctive role of AS-OCT in microbial keratitis.

Figure 4 shows the presence of an endothelial plaque. Although the exact width of the plaque could not be measured due to lack of horizontal caliper in our AS-OCT, the width of this plaque was found to decrease as the infection resolved. This again highlights the role of AS-OCT in seeing retrocorneal features. Konstantopoulos² demonstrated a similar plaque on the endothelium and measured the width of this plaque.

Figure 5 was a case of viral keratitis and shows that the infiltrate is mostly confined to the anterior part of the stroma with overlying intact epithelium. The posterior surface of the cornea shows the presence of keratic precipitates which are accumulations of inflammatory cells. In monitoring the resolution of disciform keratitis, stromal edema, microcystic edema and keratic precipitates were seen by Hixson et al⁸ and Konstantopoulos et al.⁴

In one case not responding to treatment, neither CT nor IT could be measured. This was probably because of dense infiltration and AS-OCT device with a wavelength of 1310 nm may be more useful in measuring corneal parameters in such cases. In the case series by Konstantopoulos,⁴

one case with mixed bacterial and fungal infection showed progressive increase in CT for almost a week and had to be finally taken up for a therapeutic keratoplasty. Hence, we concluded that dense infiltration, progressive increase in CT or thinning of the cornea with active infiltration should be taken as dangerous signs. These patients should be intensively followed for early therapeutic keratoplasty if descemetocele formation occurs.

Scans must be interpreted in the context of the clinical situation and examination. AS-OCT cannot replace slit-lamp examination, but it does provide additional information to help in assessment.

This study had several limitations. First, was the inability to see the posterior limit of the cornea in cases of thick infiltrate. This was because of the use of 830 nm wavelength light, unlike the 1310 nm that is used in AS-OCT and which allows deeper tissue penetration by reducing scattering. Secondly, the OCT machine used by us did not have a horizontal caliper tool such that the width of the infiltrate, scar or defect could not be measured. Thirdly, our SD-OCT images only a finite section of the cornea; for widespread keratitis or diffuse corneal edema, SD-OCT devices that image the cornea from limbus to limbus with better resolution would be more useful. Fourthly, scanning the exact desired location of the cornea at every follow up visit is subjective in nature. Lastly, a follow up period of 6 weeks was insufficient, as certain cases of fungal keratitis with thick stromal infiltrate can take longer to heal. We could document complete epithelial healing in only 12 out of 17 cases at the end of this period.

5. Conclusion

This study involved both quantitative and qualitative analysis of resolving microbial keratitis. With treatment, both CT and IT showed a significant decrease. This correlated well with the slit lamp examination which showed a decrease in acute inflammatory signs such as conjunctival congestion, corneal infiltration and hypopyon height. Thus, serial scans helped to evaluate the response to treatment. Secondly, certain histological patterns were seen on AS-OCT which cannot be seen on slit lamp such as stromal thinning, cystic spaces, microcystic edema. Hence, AS-OCT showed additional morphologic features and can be used as an adjunctive method to follow microbial keratitis with greater accuracy and objectivity compared to slit lamp examination alone.

AS-OCT provides a cross-sectional image showing the location and extent of edema throughout the cornea and not just comparison of corneal and infiltrate thickness. Because it is a noncontact instrument, it improves patients'

compliance for follow up.

6. Source of Funding

None.

7. Conflict of Interest

None.

References

- Basak SK, Basak S, Mohanta A. Epidemiological and microbiological diagnosis of suppurative keratitis in Gangetic West Bengal, Eastern India. *Indian J Ophthalmol.* 2005;53(1):17–22.
- Deshmukh S, Pandey S, Maurya RP, Singh MK, Singh VP, Yadav I. Epidemiology and factors affecting visual acuity in fungal keratitis in Eastern Uttar Pradesh. *Indian J Clin Exp Ophthalmol.* 2015;1(2):68–75.
- Naik RR, Panditrao K. Spectral Domain Anterior Segment Optical Coherence Tomography in Microbial Keratitis. *Int J Sci Res.* 2015;4(12):2120–2.
- Konstantopoulos A, Kuo J, Anderson D. Assessment of the use of anterior segment optical coherence tomography in microbial keratitis. *Am J Ophthalmol.* 2008;146(4):534–42.
- Konstantopoulos A, Yadegarfar G, Fievez M. In Vivo Quantification of Bacterial Keratitis With Optical Coherence Tomography. *Invest Ophthalmol Vis Sci.* 2011;52:1093–7.
- Martone G, Pichierrri P, Franceschini R. In Vivo Confocal Microscopy and Anterior Segment Optical Coherence Tomography in a Case of *Alternaria* Keratitis. *Cornea.* 2011;30:449–53.
- Soliman W, Fathalla A, Dalia M, Al-Hussaini AK. Spectral domain anterior segment optical coherence tomography in microbial keratitis. *Graefes Arch Clin Exp Ophthalmol.* 2013;251(2):549–53.
- Hixson A, Blanc S, Sowka J. Monitoring Keratitis Resolution with Optical Coherence Tomography. *Optom Vis Sci.* 2014;91(4 Suppl 1):S40–5. doi:10.1097/OPX.000000000000189.
- Kobayashi R, Hashida N, Soma T. Clinical Findings of Anterior Segment Spectral Domain Optical Coherence Tomography Images in Cytomegalovirus Corneal Endothelitis. *Cornea.* 2017;36:411–4.

Author biography

Isha Chaturvedi, Senior Resident

Kamaljeet Singh, Professor and Head

Jagriti Rana, Professor

Kshama Dwivedi, Professor

Reena Sachan, Professor

Cite this article: Chaturvedi I, Singh K, Rana J, Dwivedi K, Sachan R. Role of anterior segment optical coherence tomography in the evaluation of microbial keratitis. *Indian J Clin Exp Ophthalmol* 2021;7(3):548-553.