

Content available at: <https://www.ipinnovative.com/open-access-journals>

Indian Journal of Clinical and Experimental Ophthalmology

Journal homepage: www.ijceo.org

Review Article

Hydroxychloroquine retinal toxicity- Can we do better with SD-OCT?

Logandran Vijaya Kumar^{1,*}, Kursiah Mohd Razali², Wan Hazabbah Wan Hitam³¹Ministry of Health, Malaysia²Hospital Raja Permaisuri Bainun, Perak, Malaysia³Universiti Sains, Malaysia

ARTICLE INFO

Article history:

Received 14-03-2021

Accepted 26-04-2021

Available online 30-09-2021

Keywords:

Hydroxychloroquine

Plaquenil

RNFL Thinning

Macula thinning

ABSTRACT

Introduction: Hydroxychloroquine used in the management of connective tissue diseases also used to treat a wide spectrum of diseases. This disease-modifying anti-rheumatic drug can cause irreversible retinal damage and there are preferred practice guidelines for early screening to aid ophthalmologists and all those involved in the management of these patients. Spectral-Domain Optical Coherence Tomography (SD-OCT) currently an important tool in early detection of possible toxicity. Even with the current guideline-recommended 5mg/kg/day dosage, a baseline SD-OCT of the macula should be taken and repeated at 5 years. Many cross-sectional studies using SD-OCT have shown earlier retina damages, but none had monitored continuously from the beginning of Hydroxychloroquine usage.

Purpose: To evaluate sequential changes of the retina thickness in patients newly treated with hydroxychloroquine.

Materials and Methods: We compared the mean central macular and Retinal Nerve Fiber Layer (RNFL) thickness pre, 3 months and 6 months post hydroxychloroquine using SD-OCT in order to find an association between them over the three time-points. 33 previously healthy patients who were newly confirmed clinically and serologically with connective tissue disease planned for hydroxychloroquine who fulfilled the inclusion and exclusion criteria were recruited over 2 years. In consideration of selection criteria and drop-out rate, finally, 26 patients were included in the study.

Results: 26 eyes of 26 patients (20 females and 6 males) were included in the study. The mean age was 33.92. The macula was significantly thinner ($P < 0.05$) at superior ($P < 0.032$), temporal ($P < 0.025$), and inferior ($P < 0.016$) parafoveal areas. RNFL showed significantly thinning at the temporal quadrant ($P < 0.041$). Further analysis showed significant occurrences of parafoveal inferior thinning at 3 ($P < 0.035$) and 6 ($P < 0.032$) months. Correlation analysis between parafoveal thinning and the mean optic disc RNFL showed a significant result ($p = 0.004$, $r = 0.55$). The mean optic disc RNFL thickness significantly affected lesser ($p = 0.004$, $r^2 = 0.302$) than the perifoveal area ($p = 0.001$, $r^2 = 0.784$) when compared to the typical parafoveal pattern of thinning in this toxicity.

Conclusion: There is a need for an earlier repetition of SD-OCT imaging before 5 years to detect potential toxicity. Involvement of RNFL requires further investigation and monitoring.

This is an Open Access (OA) journal, and articles are distributed under the terms of the [Creative Commons Attribution-NonCommercial-ShareAlike 4.0 License](https://creativecommons.org/licenses/by-nc-sa/4.0/), which allows others to remix, tweak, and build upon the work non-commercially, as long as appropriate credit is given and the new creations are licensed under the identical terms.

For reprints contact: reprint@ipinnovative.com

1. Introduction

Hydroxychloroquine is an immunomodulator drug often used as a disease-modifying antirheumatic drug (DMARDs) and acts by inhibition and modulation of immune responses.

* Corresponding author.

E-mail address: drlogan2008@gmail.com (L. V. Kumar).

Hydroxychloroquine also used in many conditions including diabetes mellitus, heart disease, graft-versus-host disease, adjunctive cancer therapy, systemic vasculitis and Coronavirus Disease 2019 (COVID-19).^{1–4}

Hydroxychloroquine retinal toxicity is a serious condition with potential retinal damage and has a higher prevalence than previously documented.⁵ The mechanism involved binding of hydroxychloroquine to the melanin of retinal pigmented epithelium, inhibits its activity over a prolonged period,⁶ causing thinning to both the inner and outer retina.⁷ Other mechanism is retinal vasculitis with retinal microinfarcts initiating the RNFL and macular thinning (inner retina), and arteriolar narrowing and disc pallor in higher concentration.⁸ Rare mechanism with early toxicity occurred with genetic predisposition to hydroxychloroquine⁹ and polymorphisms in the cytochrome P450 gene that increased hydroxychloroquine blood concentration.¹⁰

Visual acuity is usually good until the development of severe toxicity, so any efficient screening should detect structural changes (retina damage) before functional deterioration. Spectral Domain Optical Coherence Tomography (SD-OCT) is an important addition for early detection of hydroxychloroquine toxicity. The SD-OCT cross-section images at mild toxicity are subtle or unremarkable. Moderate toxicity has a distinctive discontinuity of the photoreceptor inner segment/outer segment.¹¹ With time, the outer nuclear layer thinning occurred.¹² However, the outer retinal thickness remains normal despite the destruction of outer segment photoreceptors creating the “flying saucer” or sombrero sign.¹³ Severe toxicity includes disruption of the outer retina and RPE.

The recommended dose of hydroxychloroquine, ophthalmology baseline, and follow-ups plus the screening tools changes over the years was summarized in (Table 1). The paradigm shift of these guidelines tally with discoveries of increased prevalence and the reversible retinal changes with early detection and intervention using SD-OCT. The current recommended dose is 5mg/kg real body weight per day with a baseline SD-OCT and re-imaging at 5 years of hydroxychloroquine usage to most patients classified as a low-risk group.⁵

Many cross-sectional studies using SD-OCT have shown earlier retina damages, but none had measured continuously from the beginning of hydroxychloroquine usage. Thus, the purpose of this pilot prospective cohort study is to evaluate the sequential changes of retina thickness in patients newly treated with hydroxychloroquine using the latest guideline recommendations.

2. Materials and Methods

This study was conducted after obtaining approvals from the Ethical Committee of Universiti Sains Malaysia and

the Ministry of Health of Malaysia per the Declaration of Helsinki for Human Research (USM/JEPeM/ 16060209 and NMRR-16-116-28987 (IIR)). The sample size was calculated using closest studies using G*Power version 3.1.9.2 for Windows available at <http://www.gpower.hhu.de>. We have summarized the methodology in (Figure 1). Written consent was obtained from all patients.

These patients underwent complete ocular and systemic history with the full ocular examination via slit lamp biomicroscope (Topcon Corp, Japan) and Volk Super 66 stereo fundus lens and then OCT macula and Optic disc (Cirrus-HD OCT 4000 software version 5.0, Carl Zeiss Meditec, Inc, Dublin, CA) pre, and 6 months of hydroxychloroquine treatment. At 3 months of hydroxychloroquine treatment, only OCT measurements were obtained in patients except for any visual symptoms where a complete ocular examination was conducted. Only tests that yielded signal strength of at least 6 and above were taken for interpretation to ensure the accuracy of the result.

A total of 33 patients were recruited. Two patients did not fulfill the selection criteria and five patients were lost to follow up. 26 patients were studied as per the protocol and included for analysis. Data collection and analysis were performed using the Statistical Package for the Social Sciences (SPSS) version 24 (SPSS, Chicago, IL, USA). Descriptive statistics were used to summarize the basic characteristics of the patients. Normally distributed data were expressed as mean \pm standard deviation. All values were tested for normal distribution in all groups. Repeated Measured ANOVA test used to compare the macular thickness and RNFL thickness pre, 3 months, and 6 months. A P value of less than 0.05 ($P < 0.05$) was considered significant.

3. Results

3.1. Demographic data

We summarize demographic characteristics of the patients in (Table 2). Our patients were young with a mean age of 33.92 years. Females were predominant (76.9%). Malay race was the most (50%). SLE is the most common disease (57.7%). Generally, all the patients having good visual acuity and vision remain unchanged for the period of this study except the 3 patients with 6/12 visual acuity who improved with glasses prescription and/or artificial tears.

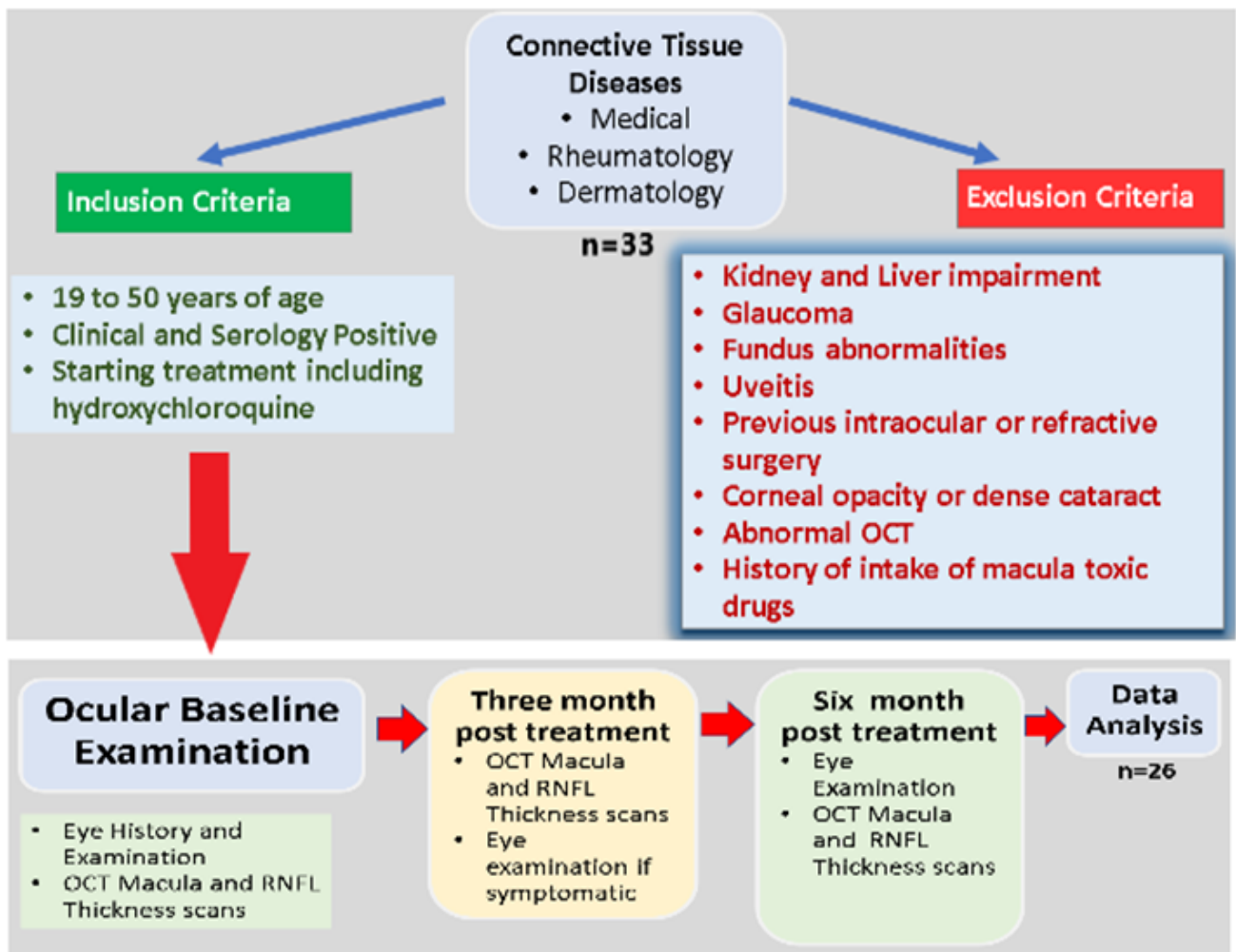


Fig. 1: Methodology of the study

Table 1: Paradigm shifts in the recommendation of guidelines on hydroxychloroquine screening

	RCOphth, 1993¹⁴	RCOphth, 1998¹⁵	AAO, 2002¹⁶	RCOphth, 2004¹⁷	RCOphth, 2009¹⁸	AAO, 2011¹⁹	AAO, 2017²⁰	RCOphth, 2018²¹
Recommended dosage	6.5 mg/kg lean weight	6.5 mg/kg lean weight	6.5 mg/kg lean weight	6.5 mg/kg lean weight	6.5 mg/kg lean weight	6.5 mg/kg lean weight	5.0 mg/kg real weight	5.0 mg/kg real weight
Baseline screening	<i>Recommended ophthalmology examination when starting, with VA, fundus and HVF 10-2</i>	Respective discipline monitor with renal and liver function, history of visual symptoms, near VA <i>Referral to ophthalmology if vision derangement or reduced VA</i>	Assessment should be done by an ophthalmologist within 1 year, of starting therapy High risk: • More than 5 years of usage • High dosage. • High body fat level. • Kidney, liver, or retinal diseases. • More than 60 years old. Low risk: • Less than 5 years of usage	Respective disciplines monitoring <i>Suggested for ophthalmology assessment Referral to ophthalmology if vision derangement or reduced VA</i>	Respective disciplines monitoring with Amsler Chart (preferably red on black) and/or HVF 10-2 Referral to an optometrist if any visual complains <i>Suggested for ophthalmology assessment</i>	<i>Advised for an ophthalmologist assessment when starting High and Low risk as AAO 2002</i>	Assessment should be done by an ophthalmologist within 1 year, of starting therapy Major toxicity factors: • Daily Dose (more than 5mg/kg) • Duration of use (more than 5 years). • Renal disease (subnormal glomerular filtration rate) • Concomitant drugs (Tamoxifen). • Retina and Macular diseases Lesser toxicity factors: • Age (Elderly) • Liver Disease • Genetic Factors	Assessment should be done by an ophthalmologist within six months, but not more than 12 months, of starting therapy with a colour retinal photograph and SD-OCT scans of the macula Major and Lesser toxicity factors as AAO 2017
Ophthalmology further screening	Nil	Nil	After 5 years if low risk (earlier based on age) or annual if high risk	At 5 years	At 5 years	At 5 years or cumulative dose of 1000 g of hydroxychloroquine	After 5 years if low risk (earlier based on age) or annual if presence of major risk	After 5 years if low risk (earlier based on age) or annual if presence of major risk

Continued on next page

Table 1 continued

<i>Important tools for screening</i>	<i>VA and Amsler Test</i>	<i>VA and Amsler Test</i>	<i>VA, Amsler Chart and/or HVF 10-2 Multi focal ERG is still in investigation</i>	<i>VA and Amsler Chart</i>	<i>Fundus photography. Amsler Chart (red on black) Suggested OCT, FAF imaging and visual electrophysiological tests</i>	HVF 10-2 with white target <i>Suggested SD-OCT, FAF and/or multi focal ERG</i>	SD-OCT and HVF (10-2 for Caucasian and 24-2 or 30-2 for Asian)	SD-OCT, widefield FAF and HVF 10-2 HVF 30-2 if abnormal FAF HVF defect with normal SD-OCT and FAF require multi focal ERG
<i>Not recommended for screening</i>	<i>Nil</i>	<i>Nil</i>	<i>Nil</i>	<i>Nil</i>	<i>Nil</i>	Fundus Photography, Time Domain OCT, Fluorescein angiograph, Full field ERG, Amsler grid, Colour testing and EOG	Fundus Photography, Time Domain OCT, Fluorescein angiography, Full field ERG, Amsler grid, Colour testing and EOG	VA, Fundus Photography, Time Domain OCT, Fluorescein angiography, Full field ERG, Amsler grid, Colour testing and EOG
<i>Long term follow-up</i>	<i>No further ophthalmic examination is necessary unless the patient becomes symptomatic</i>	<i>Individual arrangements after 5 years</i>	<i>None for low risk, Annual for high risk</i>	<i>May not be required in patients taking low (6.5 mg/kg) doses of hydroxychloro-quine</i>	<i>Most patient does not require follow-ups after check at 5 years</i>	Annual screening in all patient after 5 years	Annual screening in all patient after 5 years	Annual screening in all patient after 5 years

RCOphth: Royal College of Ophthalmologists; AAO: American Academy of Ophthalmology; HVF: Humphrey visual field; ERG: Electro-retinogram; EOG: Electro-oculogram; VA: Visual Acuity; SD-OCT: Spectral Domain Optical Coherence Tomography; FAF: Fundus Autofluorescence; Italic words: Updated in the latest guidelines; Bold & Italic words: Removed from the latest guideline

Table 2: Demographic characteristics of patients, (n=26)

Parameters	Mean (SD)	Frequency (%)
Age	33.92 (8.75)	
Gender		
Male		6 (23.1%)
Female		20 (76.9%)
Race		
Malay		13 (50.0%)
Chinese		5 (19.2%)
Indian		8 (30.8%)
Diagnosis		
SLE		15 (57.7%)
RA		7 (26.9%)
Others		4 (15.4%)
Initial Visual Acuity*		
6/6		9 (34.6%)
6/9		14 (53.8%)
6/12		3 (11.5%)

Comparing the central macular thickness and optic disc retinal nerve fiber layer thickness (RNFL) using Cirrus SD-OCT in patients with connective tissue diseases on hydroxychloroquine pre-treatment, 3 months, and 6 months post-treatment.

Comparison of mean central macular thickness and optic disc RNFL thickness were summarized in (Table 3). Generally, the macula and RNFL were thinner post-treatment. Significant thinning occurred at superior, temporal, and inferior parafoveal areas and at temporal quadrant RNFL.

Comparison of the mean central macular and optic disc retinal nerve fiber layer (RNFL) thickness using Repeated Measured ANOVA test, n=26.

Post-hoc Bonferroni correction was done to establish changes of the significant retina thinning from (Table 3) over 3 months and 6 months and is summarized in (Table 4). The inferior parafoveal area showed significant retinal thinning at 3 months and 6 months when compared with the pre-treatment group.

Linear Regression analysis to predict future thinning in the mean optic disc RNFL and the parafoveal areas based on parafoveal thinning from (Table 4) is summarized in (Table 5). All areas showed significant findings with the mean optic disc RNFL thickness significantly affected lesser ($p = 0.004$, $r^2 = 0.302$) than the parafoveal area ($p = 0.001$, $r^2 = 0.784$) when compared to the parafoveal thinning. Correlation analysis (Not Shown in the table) between parafoveal thinning and the mean optic disc RNFL also showed a significant result ($p = 0.004$, $r = 0.55$).

4. Discussion and Conclusion

This study showed that there were significant thinning in mean macular thickness at parafoveal superior, temporal, and inferior areas. (Table 3). These changes could be the

precursor to a future localized area of photoreceptor loss noted in moderate toxicity by SD-OCT. Our timelines are much earlier than Eric Chen et al¹³ who showed that the parafoveal thinning can be identified by SD-OCT in patients receiving hydroxychloroquine by 2 years. Likewise, SD-OCT cross-section quantitative analysis of the macula by Pasadhika et al²² found significant thinning of mean inner retinal thickness with the usage of hydroxychloroquine as early as 6 years even before ophthalmoscopic fundus changes. However, a recent study of hydroxychloroquine among SLE patients had shown that there are insignificant retinal changes with SD-OCT over 5 years duration.²³ But, over 99% of their patients take less than 5 mg/kg/day of HCQ and more than 92% prescribed a dose 250 mg/day which differs enormously in daily practice. Thus, repeated measurements of macular thickness to detect early thinning is relevant while quantitative analysis (such as HD Raster with 6mm Vertical x 9mm Horizontal scan area) would only be fruitful at a later stage.

The parafoveal inferior area showed significant retinal thinning at 3 months and 6 months after hydroxychloroquine usage (Table 4) which corresponded to the typical pattern of this toxicity and coincided with a recent large study of patients using hydroxychloroquine for less than 5 years duration.²⁴ However, two studies had documented that the typical parafoveal distribution of toxicity is not common in Asians, who show a pericentral pattern of foveal thinning.^{25,26} But this parafoveal pattern in the first study was observed in Korean patients while the second study although include East Asian, Southeast Asian, and Filipinos, the total percentage of Asian was only 18%. They also found that 76% of patients had typical parafoveal changes, while only 12% each showed a parafoveal or mixed pattern. In our study, focusing on Asian patients, we found parafoveal involvement to be the first sign of toxicity. Similarly, the latest review in Korean patients showed predominantly parafoveal and mixed patterns.²⁷ Another study showed that Hydroxychloroquine initially involves the parafovea, but becomes diffuse across the macula as damage progresses.²⁸ With parafoveal thinning being a typical pattern, repeat of SD-OCT prior to 5 years should be done and compared to baseline values and once there is thinning should prompt for HVF 10-2 in Asians (instead of HVF 24-2) as it has better resolution and still able to detect the parafoveal defect.

The typical parafoveal thinning could predict future thinning in other areas as shown in our study (Table 5). Among all, parafoveal area showed the highest impact as compared to fovea because fovea is protected by foveal avascular zone. Thus, repeat of SD-OCT prior to 5 years should look for new areas of thinning instead of looking for worsening of the value of the same area. Parafoveal area thinning could also influence the mean disc RNFL thickness and this new finding could be important in future

Table 3: Comparison of the mean central macular and optic disc retinal nerve fiber layer (RNFL) thickness using Repeated Measured ANOVA test, n=26

	Pre-treatment mean(SD)	3 months post treatment mean(SD)	6 months post treatment mean(SD)	F statistics	P value
Macula Thickness					
Foveal	242.00 (23.45)	239.69 (23.57)	239.08 (24.64)	1.94	0.166
Superior Parafoveal	317.81 (14.40)	315.46 (13.76)	309.62 (21.49)	1.94	0.032*
Temporal Parafoveal	302.27 (12.87)	299.58 (14.63)	299.38 (14.94)	1.94	0.025*
Inferior Parafoveal	311.73 (15.89)	309.73 (15.95)	306.85 (20.15)	1.94	0.016*
Nasal Parafoveal	319.89 (15.62)	317.85 (16.88)	316.88 (19.58)	1.94	0.076
Superior Perifoveal	285.31 (18.11)	282.23 (16.69)	282.38 (19.79)	1.82	0.184
Temporal Perifoveal	256.85 (11.55)	255.35 (11.08)	255.19 (13.08)	1.41	0.253
Inferior Perifoveal	267.08 (15.15)	264.58 (14.60)	266.96 (16.77)	1.25	0.294
Nasal Perifoveal	300.23 (17.68)	298.35 (18.27)	297.19 (19.48)	1.89	0.162
RNFL Thickness					
Superior Disc	122.38 (17.30)	120.73 (15.98)	120.38 (16.57)	1.12	0.334
Temporal Disc	70.89 (18.03)	67.92 (17.76)	68.81 (17.96)	3.42	0.041*
Inferior Disc	128.96 (20.37)	126.81 (20.12)	125.58 (20.28)	3.02	0.058
Nasal Disc	68.35 (11.63)	67.58 (12.42)	67.73 (11.41)	0.20	0.816

SD: Standard Deviation; *: Statistical significance (P<0.05)

Note: Power of the study is 0.9

Table 4: Post-hoc Bonferroni correction to establish changes of the significant retina thinning from Table 4

Right Eye	Pre-treatment and 3 months		Pre-treatment and 6 months	
	MD (95% CI)	p-value	MD (95% CI)	p-value
Superior Parafoveal	2.35 (-0.16, 4.85)	0.071	8.19 (-2.59, 18.97)	0.187
Temporal Parafoveal	2.69 (-0.71, 6.10)	0.159	2.89 (-0.18, 5.95)	0.070
Inferior Parafoveal	2.00 (0.11, 3.89)	0.035*	4.89 (0.34, 9.43)	0.032*
Temporal Disc	2.96 (-0.37, 6.29)	0.094	2.08 (-0.79, 4.95)	0.226

MD= mean difference; *: Statistical significance (P<0.05)

Table 5: Linear Regression analysis to predict future thinning in the perifoveal areas and mean optic disc RNFL on parafoveal thinning from Table 4.

Areas	β (95% CI)	t statistic (df)	p-value	r ²
Total area	0.30 (0.23, 0.37)	8.65 (24)	<0.001*	0.757
Foveal	0.27 (0.03, 0.50)	2.35 (24)	0.027*	0.188
Perifoveal	0.95 (0.74, 1.16)	9.33 (24)	<0.001*	0.784
Mean Optic Disc RNFL**	0.73 (0.26, 1.19)	3.22 (24)	<0.004*	0.302

*: Statistical significance (P<0.05)

***: Mean of superior, temporal, inferior, and nasal quadrants of optic disc RNFL thickness

studies to identify the nature of the toxicity and performing appropriate screening tests.

Our study also showed RNFL thinning (at temporal quadrant) (Table 3) in patients taking hydroxychloroquine but compared to the macula thinning we could not establish a significant change at 3 months or 6 months (Table 4). There are limited studies in this area. GY Liu et al.¹⁹ showed that there is significant retinal nerve layer thinning besides macula thinning in SLE patients with chronic hydroxychloroquine usage. Another study found the patients using hydroxychloroquine for a mean of 13.4 years had thinner mean retinal nerve fiber layers

values than healthy patients.¹⁴ Interestingly, an older study found significant thinning of RNFL nasal quadrant using quantitative analysis at 5 years of usage and postulated that it because of significant retinal ganglion cell degeneration. Measurement of the macular ganglion cell-inner plexiform layer (GC-IPL) over time may establish a new link this toxicity.¹⁵

The main limitation of our study is a short time of observation as further follow-ups could show transformation into structural defects. We also cannot measure the blood hydroxychloroquine level to establish compliance as proper testing is unreliable or still in

development.

The fundamental challenge in managing retinal hydroxychloroquine toxicity is the possibility of toxicity before 5 years of usage. A large population study conducted in the United Kingdom in 2018 showed excess dosing of hydroxychloroquine than the recommended ophthalmology level¹⁶ as it is quite commonly prescribed as 200mg or 400mg daily dose.¹⁷ Another study also revealed that half of the patients had weight documented before prescription but not used to determine the doses.¹⁸ Further, a safe dose of 5mg/kg real bodyweight places short, obese patients at unnecessarily increased risk for retinopathy.²⁰ It is also not uncommon that patients may develop renal disease or experience weight loss (and a higher dose) after 1 year and these patients will probably not realize they are high risk and will go without follow-up for 4 more years.²¹ Meanwhile, only 86% were aware that they require eye checks after five years of hydroxychloroquine use, and even worse, 20% were not compliant.²⁹ Also, these patients' eye reports are likely hard to acquire after 5 years.

Addressing this challenge, SD-OCT is crucial for the detection of early hydroxychloroquine retinal toxicity. And once the toxicity was detected, and the drug withheld before RPE damage, the progression is mild and limited (Reversible toxicity).³⁰ If the drug is continued, the area of functional disturbance expands with RPE involvement and encroach fovea and stopping the drug in this stage will not prevent further deterioration of vision (Irreversible toxicity).²⁶ Second SD-OCT imaging performed before 5-years duration, after baseline assessment may detect potential earliest retina thinning and, once there is a thinning, other modalities such as HVF 10-2, FAF, or mfERG could be used. SD-OCT also easily available and could be a cost-effective way of screening. The future applications of OCT include OCT angiography to detect the earliest microvascular changes³¹ and the wide-angle mode swept source OCT(SS-OCT) for its accuracy and a wider area.³²

In summary, SD-OCT could evaluate potential hydroxychloroquine retinal toxicity better, and we should perform it early and repeatedly.

5. Source of Funding

This work is not supported by any research grant.

6. Conflict of Interest

The authors declare that they have no competing interests.

7. Acknowledgments

We are indebted to the Rheumatological, Medical, and Dermatological departments of Hospital Raja Permaisuri Bainun contributing for the patients' pool as well as to Dr. Siti Azrin Abdul Hamid and Liu Kien Ting from


the Department of Biostatistics and Research Methodology who assisted us during proposal preparation and statistical analysis respectively.

References

- Hage MP, Al-Badri MR, Azar ST. A favorable effect of hydroxychloroquine on glucose and lipid metabolism beyond its anti-inflammatory role. *Ther Adv Endocrinol Metab.* 2014;5(4):77-85.
- Sharma TS, Wasko MCM, Tang X, Vedamurthy D, Yan X, Cote J, et al. Hydroxychloroquine Use Is Associated With Decreased Incident Cardiovascular Events in Rheumatoid Arthritis Patients. *J Am Heart Assoc.* 2016;5(1):e002867. doi:0.1161/JAHA.115.002867.
- Manic G, Obrist F, Kroemer G, Vitale I, Galluzzi L. Chloroquine and hydroxychloroquine for cancer therapy. *Mol Cell Oncol.* 2014;1(1):e29911.
- Yao X, Ye F, Zhang M, Cui C, Huang B, Niu P, et al. In Vitro Antiviral Activity and Projection of Optimized Dosing Design of Hydroxychloroquine for the Treatment of Severe Acute Respiratory Syndrome Coronavirus 2 (SARS-CoV-2). *Clin Infect Dis.* 2020;71(15):732-9. doi:10.1093/cid/ciaa237..
- Melles RB, Marmor MF. The risk of toxic retinopathy in patients on long-term hydroxychloroquine therapy. *JAMA Ophthalmol.* 2014;132(12):1453-60.
- Xu C, Zhu L, Chan T, Lu X, Shen W, Madigan MC. Chloroquine and Hydroxychloroquine Are Novel Inhibitors of Human Organic Anion Transporting Polypeptide 1A2. *J Pharm Sci.* 2016;105(2):884-90.
- Rosenthal AR, Kolb H, Bergsma D, Huxsoll D, Hopkins JL. Chloroquine retinopathy in the rhesus monkey. *Invest Ophthalmol Vis Sci.* 1978;17(12):1158-75.
- Karpik AG, Schwartz MM, Dickey LE, Streeten BW, Roberts JL. Ocular immune reactants in patients dying with systemic lupus erythematosus. *Clin Immunol Immunopathol.* 1985;35(3):295-312.
- Shroyer NF, Lewis RA, Lupski JR. Analysis of the ABCR (ABCA4) gene in 4-aminoquinoline retinopathy: is retinal toxicity by chloroquine and hydroxychloroquine related to Stargardt disease? *Am J Ophthalmol.* 2001;131(6):761-6.
- Lee JY, Vinayagamoorthy N, Han K, Kwok SK, Ju JH, Park KS, et al. Association of Polymorphisms of Cytochrome P450 2D6 With Blood Hydroxychloroquine Levels in Patients With Systemic Lupus Erythematosus. *Arthritis Rheumatol.* 2016;68(1):184-90.
- Rodriguez-Padilla JA, Hedges TR, Monson B, Srinivasan V, Wojtkowski M, Reichel E, et al. High-speed ultra-high-resolution optical coherence tomography findings in hydroxychloroquine retinopathy. *Arch Ophthalmol.* 2007;125(6):775-80.
- Marmor MF. Comparison of Screening Procedures in Hydroxychloroquine Toxicity. *Arch Ophthalmol.* 2012;130(4):461-9.
- Chen E, Brown DM, Benz MS, Fish RH, Wong TP, Kim RY. Spectral domain optical coherence tomography as an effective screening test for hydroxychloroquine retinopathy (the "flying saucer" sign). *Clin Ophthalmol (Auckland, NZ).* 2010;4:1151-8.
- Çay HF, Erol MK, Çoban DT, Bulut M, Sezer İ, Çakir T, et al. Retinotoxicity of Hydroxychloroquine: Is It Possible to Demonstrate by Spectral Domain Optical Coherence Tomography Before Development? A Cross Sectional Investigation. *Arch Rheumatol.* 2014;29(3):178-85.
- Kan E, Yakar K, Demirag MD, Gok M. Macular ganglion cell-inner plexiform layer thickness for detection of early retinal toxicity of hydroxychloroquine. *Int Ophthalmol.* 2018;38(4):1635-40.
- Jorge AM, Melles RB, Zhang Y, Lu N, Rai SK, Young LH, et al. Hydroxychloroquine prescription trends and predictors for excess dosing per recent ophthalmology guidelines. *Arthritis Res Ther.* 201805;20(1):133.
- Braslow RA, Shiloach M, Macsai MS. Adherence to Hydroxychloroquine Dosing Guidelines by Rheumatologists: An Electronic Medical Record-Based Study in an Integrated Health Care System. *Ophthalmology.* 2017;124(5):604-8.

18. Saravanan A, Ahmed T. SAT0222 Clinical risk stratification for hydroxychloroquine prescribing in a large urban district general hospital. *Ann Rheum Dis*. 2018;77(Suppl 2):972.
19. Liu GY, Utset TO, Bernard JT. Retinal nerve fiber layer and macular thinning in systemic lupus erythematosus: an optical coherence tomography study comparing SLE and neuropsychiatric SLE. *Lupus*. 2015;24(11):1169-76.
20. Browning DJ, Lee C. Somatotype, the risk of hydroxychloroquine retinopathy, and safe daily dosing guidelines. *Clin Ophthalmol*. 2018;12:811-8.
21. Marmor MF, Kellner U, Lai TYY, Melles RB, Mieler WF. American Academy of Ophthalmology Statement: Recommendations on screening for chloroquine and hydroxychloroquine retinopathy (2016 Revision). *Ophthalmology*. 2016;123:1386-94.
22. Pasadhika S, Fishman GA. Effects of chronic exposure to hydroxychloroquine or chloroquine on inner retinal structures. *Eye (Lond)*. 2010;24(2):340-6.
23. Martín-Iglesias D, Artaraz J, Fonollosa A, Ugarte A, Arteagabeitia A, Ruiz-Irastorza G. Evolution of retinal changes measured by optical coherence tomography in the assessment of hydroxychloroquine ocular safety in patients with systemic lupus erythematosus. *Lupus*. 2019;28(4):555-9.
24. Gil P, Nunes A, Farinha C, Teixeira D, Pires I, Silva R. Structural and Functional Characterization of the Retinal Effects of Hydroxychloroquine Treatment in Healthy Eyes. *Ophthalmologica*. 2019;241(4):226-33.
25. Melles RB, Marmor MF. Pericentral retinopathy and racial differences in hydroxychloroquine toxicity. *Ophthalmology*. 2015;122(1):110-6.
26. Lee DH, Melles RB, Joe SG, Lee JY, Kim JG, Lee CK. Pericentral hydroxychloroquine retinopathy in Korean patients. *Ophthalmology*. 2015;122(6):1252-6.
27. Eo D, Lee MG, Ham DI, Kang SW, Lee J, Cha HS. Frequency and Clinical Characteristics of Hydroxychloroquine Retinopathy in Korean Patients with Rheumatologic Diseases. *J Korean Med Sci*. 2017;32(3):522-7.
28. Sisternes LD, Hu J, Rubin DL, Marmor MF. Localization of damage in progressive hydroxychloroquine retinopathy on and off the drug: inner versus outer retina, parafovea versus peripheral fovea. *Invest Ophthalmol Vis Sci*. 2015;56(5):3415-26.
29. Sunmboye K, Shaffu S, Mccartney M. PS6:113 Long-term hydroxychloroquine use: are lupus patients undermonitored?: a university teaching hospital experience. *Lupus Sci Med*. 2018;5(Suppl 1):92.
30. Marmor MF, Hu J. Effect of disease stage on progression of hydroxychloroquine retinopathy. *JAMA Ophthalmol*. 2014;132(9):1105-12.
31. Bulut M, Akıdan M, Gözkaya O, Erol MK, Cengiz A, Çay HF. Optical coherence tomography angiography for screening of hydroxychloroquine-induced retinal alterations. *Graefes Arch Clin Exp Ophthalmol*. 2018;256(11):2075-81.
32. Ahn SJ, Joung J, Lee BR. En Face Optical Coherence Tomography Imaging of the Photoreceptor Layers in Hydroxychloroquine Retinopathy. *Am J Ophthalmol*. 2019;199:71-81.

Author biography

Logandran Vijaya Kumar, Ophthalmologist  <https://orcid.org/0000-0002-0013-1508>

Kursiah Mohd Razali, Ophthalmologist

Wan Hazabbah Wan Hitam, Professor

Cite this article: Kumar LV, Razali KM, Hitam WHW. Hydroxychloroquine retinal toxicity- Can we do better with SD-OCT?. *Indian J Clin Exp Ophthalmol* 2021;7(3):457-465.